

Diagnostic Imaging Pathways - Prostate Cancer (Suspected and Staging)

Population Covered By The Guidance

This pathway provides guidance on the diagnosis and staging of adult male patients with suspected prostate cancer.

Date reviewed: November 2015

Date of next review: 2017/2018






Published: February 2017

Quick User Guide

Move the mouse cursor over the **PINK** text boxes inside the flow chart to bring up a pop up box with salient points.

Clicking on the **PINK** text box will bring up the full text.

The relative radiation level (RRL) of each imaging investigation is displayed in the pop up box.

SYMBOL	RRL	EFFECTIVE DOSE RANGE
	None	0
	Minimal	< 1 millisieverts
	Low	1-5 mSv
	Medium	5-10 mSv
	High	> 10 mSv

Pathway Diagram

Date reviewed November 2015
 Please note that this pathway is subject to review and revision

- What do I need to know?**
1. What are the patient's risk factors?
 2. Is the patient symptomatic?
 3. Are there any contraindications for MRI?
 4. Is there ongoing clinical suspicion despite a negative biopsy?

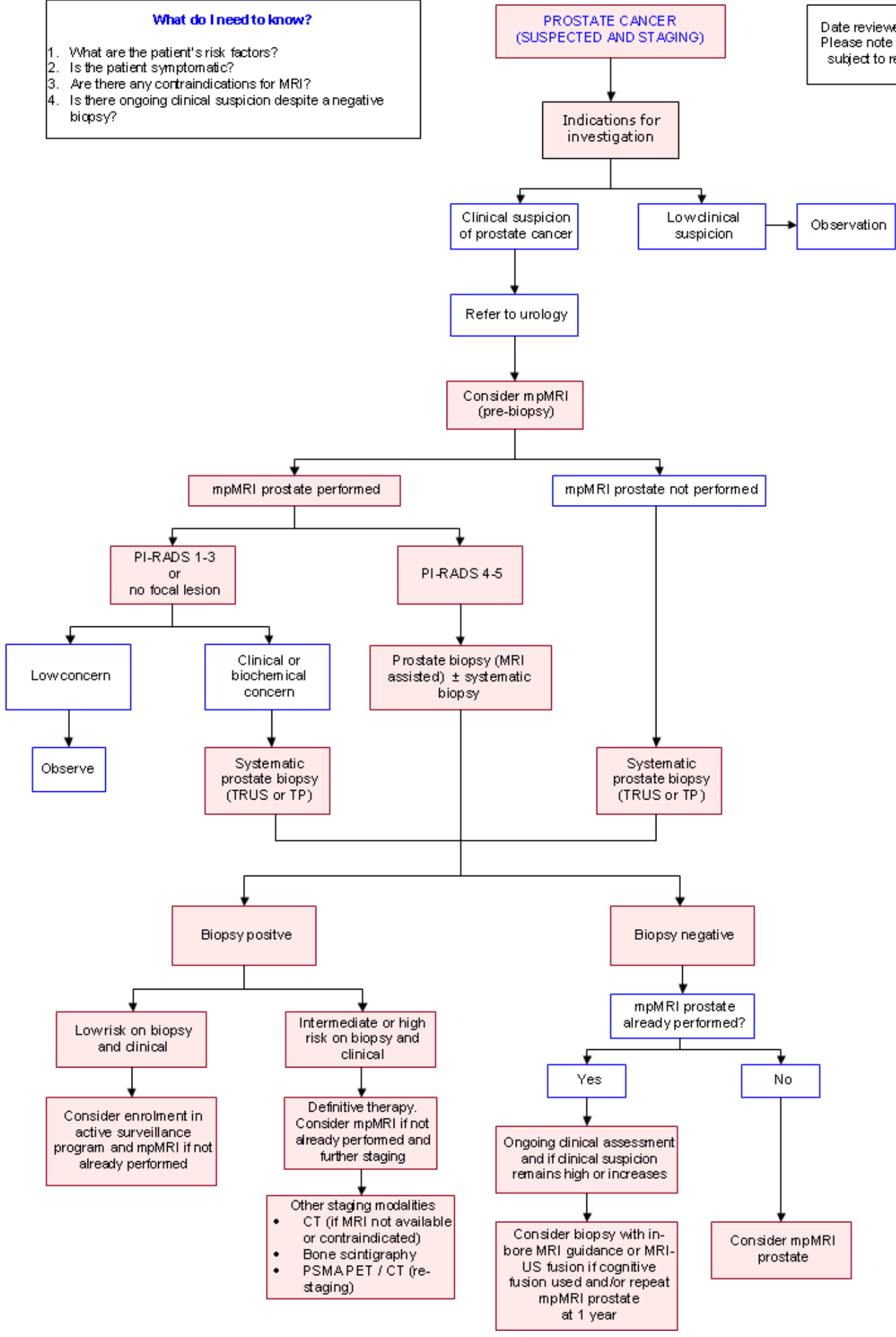


Image Gallery

Note: These images open in a new page

1 **Prostate Carcinoma**

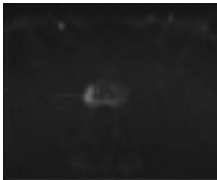


Image 1 (Multi-parametric MRI, DWI) : peripheral zone lesion

2 **Prostate Carcinoma**

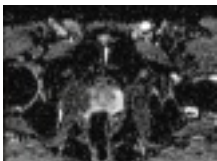

Image 2 (Multi-parametric MRI, ADC) : peripheral zone lesion

3 **Prostate Carcinoma**

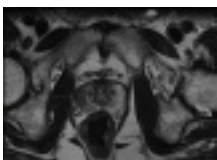


Image 3 (Multi-parametric MRI, T2WI) : peripheral zone lesion

Teaching Points

- With the rationale of performing pre-biopsy MRI in the initial assessment, subsequent MRI assisted biopsy may result in fewer men biopsied overall with far less cores needed or no further biopsies and prevents the diagnosis of clinically insignificant cancer
- In clinically low risk patients who have no focal lesion or a PI-RADS 1-3 lesion on mpMRI, no further imaging is indicated
- For initial staging of advanced prostate cancer, 99mTc bone scintigraphy and CT abdomen/pelvis/chest should be considered as the imaging modalities
- In patients with suspected biochemical recurrence, 68Ga-PSMA PET / CT can detect prostate cancer at low PSA levels and may be preferred over conventional imaging for re-staging. The role of 68Ga-PSMA PET / CT in primary staging is still under investigation

Prostate Cancer (Suspected and Staging)

- As prostate cancer is very age-dependent, more than two-thirds of all new prostate cancers are diagnosed in men aged 60-79 and >80% of prostate cancer deaths occur in men >70 years [1](#)
- Around 9 in 10 Australian men with prostate cancer have a 93% 5-year survival rate. Nearly all patients who present with localised disease will live beyond five years, with the 10- and 15-year survival rates being 84% and 77% respectively. Prostate cancer relative survival (period 2006–2010) varies with age, with: [2-4](#)
 - 1-year relative survival



- Age 0-79: 96% to nearly 100%
- Age ≥80 years: 89%
- 5-year relative survival
 - Age 40-69: 95% and 97% (highest)
 - Age 70-79: 91%
 - Age

Prostate Imaging – Reporting and Data System (PI-RADS) Scoring

Guidance for assignment of overall PI-RADS v2 score [25, 26](#)

Peripheral zone lesion	DWI Score (dominant sequence)	DCE Score (secondary sequence)	T2WI Score	Overall PI-RADS v2 Score
	1	Any	Any	1
	2	Any	Any	2
	3	-	Any	3
	3	+	Any	4
	4	Any	Any	4
	5	Any	Any	5
Transition zone lesion	T2WI Score (dominant sequence)	DWI Score (secondary sequence)	DCE Score	Overall PI-RADS v2 Score
	1	Any	Any	1
	2	Any	Any	2
	3	?4	Any	3
	3	5	Any	4
	4	Any	Any	4
	5	Any	Any	5

PI-RADS v2 Assessment Categories	PIRADS 1	Very low (clinically significant cancer is highly unlikely to be present)
	PIRADS 2	Low (clinically significant cancer is unlikely to



	be present)
PIRADS 3	Intermediate (the presence of clinically significant cancer is equivocal)
PIRADS 4	High (clinically significant cancer is likely to be present)
PIRADS 5	Very high (clinically significant cancer is highly likely to be present)

Multi-parametric Magnetic Resonance Imaging (mpMRI)

- mpMRI combines anatomic (T1- and T2-weighted imaging) with functional and physiologic assessment using diffusion-weighted imaging (DWI) and its derivative apparent diffusion coefficient (ADC) maps, dynamic contrast-enhanced (DCE) MRI and sometimes other techniques such as MR proton spectroscopy (though not routinely used). Although use has grown in recent years, one of the biggest challenges with mpMRI has been the substantial variation in diagnostic performance reported across different centres and lack of consistency in reporting and interpretation
- Clinical guidelines for the acquisition and reporting of mpMRI called the Prostate Imaging-Reporting and Data System (PI-RADS) were developed in 2012 by the European Society of Urogenital Radiology with a later revised version developed in conjunction with the American College of Radiology and the AdMeTechFoundation in 2014. The PI-RADS version 2 (v2) includes recommendations for risk stratification of patients with PCa, image acquisition, an overview of normal anatomy and benign findings, a lexicon of terminology as well as a proposed scoring system in order to promote global standardisation of interpretation and reporting of mpMRI
- PI-RADS v2 introduced the concept of dominant sequences based on the location of the prostate lesion. For peripheral zone lesions, the dominant sequence is DWI, which determines the PI-RADS score, with the secondary sequence DCE used for PI-RADS 3 lesions. For transitional zone lesions, the dominant sequence is T2WI and DWI is the secondary sequence used

to differentiate PI-RADS 3 lesions. The PI-RADS score reflects the probability that the findings correlate with the presence of clinically significant cancer. The assigned score is based solely on mpMRI findings alone and do not take into account PSA level, DRE findings or clinical history

- PI-RADS v1 has been validated in several studies [27-29](#). Since its publication, several retrospective validation studies looking at the diagnostic performance of PI-RADS v2 in PCa have shown promising results, with a reported lesion-based AUC of 0.83 and good inter-reader reliability ($k=0.68$) [30-32](#)
- PI-RADS v2 is designed to be used in a pre-therapy patient and has not been tested for the detection of suspected recurrent PCa, progression during surveillance or for evaluation of other parts of the body that may be involved with PCa
- It is likely that a mpMRI showing no evidence of tumour has a negative predictive value for significant disease similar to or better than a standard 12 core prostate biopsy thus performing MRI as the first investigation in a man suspected of having prostate cancer might in some cases prevent the need for biopsy [17](#) in up to 51% of cases. [18](#) Furthermore, an MRGB pathway decreased the diagnosis of low-risk prostate cancer by 89.4%, and increased the detection of intermediate/high-risk prostate cancer by 17.7% compared with a 12 core TRUS biopsy pathway [18](#)
- MpMRI demonstrates high specificity (0.82-0.92), negative predictive value (NPV) (0.66-0.81) and sensitivity (0.66-0.81) for prostate cancer detection utilizing T2-weighted imaging combined with two functional techniques: diffusion-weighted imaging (DWI) and dynamic contrast-enhanced MRI (DCE-MRI) while the combination of T2WI and DWI or Magnetic Resonance Spectroscopic Imaging (MRSI) with DCE-MRI has the potential to guide biopsy to the most aggressive cancer foci in patients with previously negative biopsies, increasing the accuracy of the procedure [19](#)
- In biopsy naive patients with elevated PSA and normal DRE, pre-biopsy mpMRI reports a sensitivity (61-71%), specificity (89-96%), accuracy (85-87%), and area under the curve (AUC) values (0.79-0.81) for the detection of significant prostate cancer [20](#)
- Detection of clinically significant prostate cancer using mpMRI ranged from 44% to 87% and the negative predictive value for exclusion of significant disease ranged from 63% to 98% for both biopsy naive males and men with prior negative biopsies [21](#)
- This may result in fewer (up to a third) of men biopsied overall with far less cores needed or no further biopsies. Additionally, the targeted approach prevented the diagnosis of clinically insignificant cancer in 10% of the population [17, 18, 22, 23](#) fewer or no systematic or targeted biopsies in patients with PSA suspicious for prostate cancer
- Pre-biopsy MRI also improves accuracy for smaller lesions. The indications for repeat biopsy are [6, 8](#)
 - a. Rising and / or persistently elevated PSA [24](#)
 - b. Suspicious DRE (5-30% cancer risk)
 - c. Atypical small acinar proliferation (40% cancer risk)
 - d. Extensive high grade prostatic intraepithelial neoplasia (HGPIN) from > 3 biopsy sites) (~30% cancer risk)
 - e. A few atypical glands immediately adjacent to high grade prostatic

intraepithelial neoplasia (PINATYP) (~50% cancer risk)

- In patients with elevated PSA and previous negative TRUS-biopsy sessions, MRGB of mpMRI suspicious regions report good prostate cancer-detection rate of between 52%-65% [24, 33, 34](#) with high sensitivity (91%) [35](#). The majority of detected cancers were clinically significant (80.8%-93%) [7, 24, 34, 36, 37](#) while the detection of insignificant prostate cancer was much lower (44%) [35, 38](#)
 - Serum PSA levels is predictive for a positive biopsy result while the number of preceding negative biopsies was not associated with the likelihood of a positive biopsy result [24](#). With this strategy, almost two-thirds (59%) of men with 2 or more previous negative TRUS biopsies have been diagnosed with cancer [39](#)
 - There are significant histological differences between detected and missed prostate tumours using magnetic resonance imaging with independent predictors of detection being size, Gleason score and solid growth
 - a. Identification with T2-weighted imaging is associated with size and Gleason score
 - b. Identification with DWI is associated with size, Gleason score and loose stroma
 - c. Identification with DCE was associated with intermixed benign epithelium, loose stroma and a high malignant epithelium-to-stroma ratio
- Knowledge to this may aid in the use of mpMRI for treatment selection for patients with prostate cancer
- Cancers, in the anterior prostate, apex, and midline are either under-sampled or never sampled, resulting in clinically significant cancers going undetected [39](#)
 - Furthermore, the majority of tumours missed by TRUS biopsy are anteriorly located [33, 40](#). Anterior prostate cancer can be missed in up to 46% of cases and of the detected cases, there was significant Gleason score upgrading in 44% of cases [41](#). Prostate cancer or significant cancer missed by trans-rectal biopsy can be well identified by mpMRI [42-44](#)
 - However, it should be noted that most tumours missed by MRI guided in-bore biopsy alone had a Gleason score of 3+3=6 [40](#). About 25% of patients with Gleason scores of 6 will be found to have more aggressive disease after radical prostatectomy [13](#). Men with low-risk disease (Gleason score 6, PSA

Prostate Ultrasound and Prostate Systematic Biopsy Under US

- Ultrasound (transrectal or transperineal) should not be used for local staging of prostate cancer. It has a tendency to under-stage. [8](#) It cannot accurately differentiate between T2 and T3 tumours [6, 8](#), nor can it reliably predict extra-capsular extension (accuracy 37-83%) [13](#) due to inadequate spatial resolution. This results in biopsies not specifically targeted to areas most likely to be malignant [3](#)
- Cancer detection rates (CDR) are comparable with both approaches TRUS and transperineal (TP) [6](#) with reasonable, self-limiting morbidity [50](#) and negligible sepsis rate [51](#) of the TP saturation approach. In grey-zone PSA cases, more TZ cores were positive

- with the TP approach than with TRUS [52](#)
- Saturation biopsy appears to be necessary in the repeat setting [53](#), [54](#), the indications for which include: Rising and / or persistently elevated PSA [24](#); Suspicious DRE (5-30% cancer risk); atypical small acinar proliferation (40% cancer risk); extensive high grade prostatic intraepithelial neoplasia (HGPIN) from > 3 biopsy sites (~30% cancer risk); a few atypical glands immediately adjacent to high grade prostatic intraepithelial neoplasia (PINATYP) (~50% cancer risk). [6, 8](#) If performed transperineally, it may detect an additional 38% of prostate cancer [6](#) Apart from improving the cancer detection rate, it also is responsible for the increase of clinically insignificant disease [24](#) and high rate of urinary retention (10%). Therefore, saturation biopsy is often reserved for high risk patients with rising or persistently elevated PSA, previous abnormal biopsies or DRE [6](#)
 - Sextant biopsy (6 cores) is no longer considered adequate. For prostate volume 30-40 mL, > 8 cores should be sampled. Ten to 12 core biopsies are recommended, with > 12 cores not being significantly more conclusive. [6](#) A cut-off of 0.5 mL is commonly used to distinguish insignificant from clinically relevant cancer [6, 17](#) There are studies that report that there is no clear advantage of targeted biopsies over the current standard of systematic biopsies (SB) when considering overall CDR as an outcome. However the combination of fusion of systematic and targeted biopsy schemes provides the highest detection rate [50, 55](#)

Positive Biopsy for Cancer

- Clinically 'insignificant' prostate cancer can be defined as a cancer, which will not affect the patient during the natural course of his lifetime. [5](#)
- To date, the most commonly used criteria for defining 'insignificant' prostate cancer are based on the pathologic assessment of the radical prostatectomy specimen and include the well-established prognostic factors of: [56](#)
 - Gleason score ≤ 6 without Gleason pattern 4 or 5
 - Organ-confined disease (no extra-prostatic extension, no seminal vesicle or lymph node invasion) and
 - Tumour volume $< 0.5\text{cm}^3$

Gleason's Pattern Scale

- Prostate cancer is graded histologically using normal healthy prostate tissue as a comparison. The tissue architectural appearance indicates the aggressiveness of the tumour and ultimately provides information regarding the risk posed by the cancer to direct patient management. Scores from 1 (most normal or differentiated) to 5 (most abnormal or poorly differentiated) are assigned. The Gleason score is given as two numbers added together to give a score out of 10 (for example, 3 + 4 = 7). The first



number is the tumour's dominant pattern (primary grade) while the second number is the tumour's next most frequent pattern (secondary grade). A high Gleason score indicates an aggressive cancer and predilection for rapid disease progression.

- Low risk (Gleason score 2-6): Low grade, well differentiated tumour
 - Intermediate risk (Gleason score 7): Intermediate grade, moderately differentiated tumour
 - High risk (Gleason score 8-10): High grade, poorly differentiated tumour
- There are multiple organisational pre-treatment prostate cancer risk stratification systems [57](#) based on the initial PSA, biopsy Gleason score and clinical T stage. This includes the European Association of Urology (EAU) [8](#), American Urology Association (AUA) [58](#), National Institute For Health and Clinical Excellence (NICE) [59](#), National Cancer Control Network (NCCN) [11](#) and European Society for Medical Oncology (ESMO) [60](#) risk stratification systems as summarised in the table below. There is no consensus as to which

system is superior and clinical practice varies across institutions.

Organisation	Low risk	Intermediate risk	High risk
AUA EAU	<ul style="list-style-type: none"> • T1-T2a and • PSA <10 ng/mL and • Gleason score ≤6 	<ul style="list-style-type: none"> • T2b and/or • PSA 10-20 ng/mL not low-risk or • Gleason score 7 	<ul style="list-style-type: none"> • ?T2c or • PSA >20 ng/mL or • Gleason score 8-10
NICE	<ul style="list-style-type: none"> • T1-T2a and • PSA ≤10 ng/mL and • Gleason score ≤6 	<ul style="list-style-type: none"> • T1-T2 and/or • PSA ≤20 ng/mL not low-risk or • Gleason score ≤7 	<ul style="list-style-type: none"> • ?T3a or • PSA >20 ng/mL or • Gleason score 8-10



NCCN	T1-T2a and Gleason score 2-6 and PSA <10 ng/mL not very low-risk AND very-low risk category: T1c and GS <6 and PSA <10 ng/mL and fewer than 3 biopsy cores positive and >50% cancer in each core	<ul style="list-style-type: none"> • T2b or T2c and/ or • PSA >10 –20 ng/mL not low-risk and/ or • Gleason score <7 	<ul style="list-style-type: none"> • T3a or • PSA >20 ng/mL or • Gleason score 8-10 not very high risk AND very high-risk: category T3b-4
ESMO	<ul style="list-style-type: none"> • T1-T2a and • PSA <10 ng/mL and • Gleason score <6 	Not high risk and not low risk (the remainder)	<ul style="list-style-type: none"> • T3-4 or • PSA >20 ng/mL or • Gleason score 8-10

Table: Organisational pre-treatment prostate cancer risk stratification systems that were used to support the literature and proposed imaging pathway (table adapted from Rodrigues G, et al. [57](#))

Active Surveillance (AS)

- It is recommended that patients and their treating physicians consider active surveillance based on careful consideration of the patient's prostate cancer risk profile, age, health and personal preferences [11](#)
- Active surveillance is recommended for patients with low risk prostate cancer and those with intermediate risk prostate cancer who



do not wish to have immediate treatment. [59](#) Active surveillance is not recommended for patients with high risk cancer

- Most guidelines make a distinction between active surveillance and observation (or watchful waiting) in the management of prostate cancer [11, 61](#)
- In active surveillance the intent is curative and involves regular follow-up of patients with the expectation to intervene if there is evidence of disease progression
- The intent of observation is to provide palliative treatment for the development of symptoms associated with disease progression in a patient with limited life expectancy

Year 4 The recommended protocol for active surveillance is [59](#)

- Every 3-4 months: measure PSA and monitor PSA kinetics
- Every 6-12 months: perform DRE

Years 2-4 12 months: prostate re-biopsy *

- Every 3-6 months: measure PSA and monitor PSA kinetics

Year 5 and thereafter

- Every 6 months: measure PSA and monitor PSA kinetics

* Prostate re-biopsy at 12 months, DRE every 3 years and at any time if there is clinical or biochemical concern. If no evidence of disease progression, then continue active surveillance. If evidence of disease progression, then offer treatment.

- Although mpMRI is not routinely recommended for active surveillance, MRI has a high specificity for clinically significant carcinoma [62](#) and it may be useful when a patient's clinical findings are discordant with the pathological findings and to exclude the presence of an anterior cancer [63](#)
- A positive MRI is more likely to be associated with upgrading (Gleason score >3+3) than a negative MRI (43% vs 27%) while a positive MRI is not significantly more likely to be associated with upstaging at radical prostatectomy (>T2) than a negative MRI (10% vs 8%). [64](#) Available clinical evidence demonstrates that Gleason 6 cancer (3 + 3) has little or no metastatic potential [65](#)
- A small percentage of low-grade cancers (1% of patients per year) harbour molecular alterations that result in grade progression, which means that long term follow up is required [65](#)
- Therefore MRI is appropriate to clarify a patient's risk status and to detect cases that have been under-staged and misclassified [13, 17](#)
- Visible tumours can be monitored for progression and MRI has the capacity to contribute to follow-up cases in such instances [17](#)

Prostate Cancer Staging

TNM Staging

- The most widely used staging system for prostate cancer is the Primary Tumour (T) (Clinical) TNM system. [66](#)

Primary Tumour (T) (Clinical)	Definition
TX	Primary tumour cannot be assessed
T0	No evidence of primary



	tumour
T1	Clinically inapparent tumour neither palpable nor visible by imaging
T1a	Tumour incidental histologic finding in 5% or less of tissue resected
T1b	Tumour incidental histologic finding in more than 5% of tissue resected
T1c	Tumour identified by needle biopsy (for example, because of elevated PSA)
T2	Tumour confined within prostate ¹
T2a	Tumour involves one-half of one lobe or less
T2b	Tumour involves more than one-half of one lobe but not both lobes
T2c	Tumour involves both lobes
T3	Tumour extends through the prostate capsule ²
T3a	Extra-capsular extension (unilateral or bilateral)
T3b	Tumour invades seminal vesicle(s)
T4	Tumour is fixed or invades adjacent structures other than seminal vesicles, such as external sphincter, rectum, bladder, levator muscles, and/or pelvic wall
<p>Note</p> <ol style="list-style-type: none"> 1. Tumor found in one or both lobes by needle biopsy, but not palpable or reliably visible by imaging, is classified as T1c 2. Invasion into the prostatic apex or into (but not beyond) the prostatic capsule is classified not as T3 but as T2 	
Regional Lymph Nodes (N)	
Nx	Regional lymph nodes were not assessed
No	No regional lymph node metastasis



N1	Metastasis in regional lymph node(s)
Distant Metastasis (M)³	
M0	No distant metastasis
M1	Distant metastasis
M1a	Nonregional lymph node(s)
M1b	Bone(s)
M1c	Other site(s) with or without bone disease
<p>Note</p> <p>3. When more than one site of metastasis is present, the most advanced category is used. pM1c is most advanced</p>	

Anatomic Stage / Prognostic Groups					
Gro up	T	N	M	PSA	Glea son
I	T1a-c	N0	M0	<10	?6
	T2a	N0	M0	<10	?6
	T1-2a	N0	M0	X	X
IIA	T1a-c	N0	M0	<20	7
	T1a-c	N0	M0	?10 <20	?6
	T2a	N0	M0	?10 <20	?6
	T2a	N0	M0	<20	7
	T2b	N0	M0	<20	?7
	T2b	N0	M0	X	X
IIB	T2c	N0	M0	Any	Any
	T1-2	N0	M0	?20	Any
	T1-2	N0	M0	Any	?8
III	T3a-b	N0	M0	Any	Any
IV	T4	N0	M0	Any	Any
	Any T	N1	M0	Any	Any
	Any T	Any N	M1	Any	Any

Computed Tomography (CT)

- CT may be used as an initial staging imaging modality in select patients [11](#)
 - a. T3 or T4 disease
 - b. Patients with T1 or T2 disease and nomogram indicated

- probability of lymph node involvement >10% may be candidates for pelvic imaging, but the level of evidence is low
- CT may be considered in patients after RP when [3](#)
 - a. PSA fails to fall to undetectable levels, or
 - b. when an undetectable PSA becomes detectable and increases on 2 subsequent determinations, or
 - c. after RT for rising PSA or positive DRE if the patient is a candidate for additional therapy
- CT and MRI should be considered for men with low-risk patients and consider mpMRI (or CT if MRI is unavailable / contraindicated), for men with histologically proven prostate cancer if knowledge of the T or N stage could affect management [6, 8, 11, 13, 16](#)

Bone Scintigraphy (BS)

- No single imaging modality is consistently best for the assessment of metastatic bone disease across all tumour types and clinical situations [15](#)
- However, metastatic bone disease occurs in approximately 90% of patients with metastatic prostate cancer, thus making bone scans (single photon, using Tc-99m labelled phosphonates) the mainstay of imaging in advanced prostate cancer [6, 8, 13, 67](#)
- In low risk patients, no imaging is indicated [8, 15, 16](#) as BS positivity rate in this group of patients are extremely low (6 Bone scans are rarely positive in asymptomatic men with PSA 20 ng/mL [6](#)
- PSA \geq 20 ng/mL or poorly differentiated primary tumours [15](#)
- Advanced disease (T1 disease and PSA 20, T2 disease and PSA 10, Gleason score 8, or T3/T4 disease) and / or symptomatic patients [11](#)
- Limitations of bone scanning include [67](#)
 - a. lack of specificity
 - b. unclear relationship between bone scan changes and disease progression or response to therapy
- Owing to bone scintigraphy's low specificity, and in equivocal cases, 18F-fluorodeoxyglucose PET or PET / CT could be of value to differentiate active metastases and healing bones [6, 8, 15](#)
- Combined whole-body MRI and mpMRI of the prostate plays a vital role (both sensitivity [68](#) and specificity of 100%) as a single-step, non-irradiating technique to perform TNM staging in high-risk PCa on 3T when compared to a combination of BS + TXR and CT (sensitivity 85% and specificity of 88%) [69](#)
- Considering the cost-effectiveness when implementing new strategies for bone and soft tissue imaging, it is recommended that 99mTc bone scintigraphy and CT abdomen / pelvis / chest as the imaging modalities for initial staging in intermediate and high risk [70](#)

Positron Emission Tomography/Computed Tomography (PET / CT) and PSMA



- The gold standard for nodal staging is open or laparoscopic lymphadenectomy. Pre-treatment imaging facilitates the visual detection of tumour bearing sentinel lymph nodes (SN) allowing for appropriate management planning with the aim to reduce morbidity associated with extended pelvic lymph node dissection. However, difficulty in accessing the SN and the lack of clinical evidence are limitations to its use [6](#)
- In the last several years PET and PET / CT have been playing an increasing role in the staging workup of newly diagnosed and recurrent prostate cancer with the potential to play an important role in detecting early metastatic spread and monitoring post-therapy response [13](#)
- The radiotracers available include 68Ga-PSMA-ligand, 11C or 18F choline and acetate, 11C methionine, 18F fluoride, fluorodihydrotestosterone and 18F-FDG
- PSMA or prostate-specific membrane antigen is a cell surface protein which is physiologically expressed at relatively low levels in the kidneys and salivary glands. Prostate cancer cells have a significantly increased expression of PSMA which enables excellent contrast between malignant and most healthy tissues [71](#)
- Several isotopes and ligands have been developed for use in PSMA PET, and currently there is no consensus as to which is best. [72](#) The most commonly used ligand in Australia is 68Ga-HBED-PSMA
- Preliminary studies looking at the accuracy of 68Ga-PSMA PET in primary staging have been promising, but larger trials are needed for it to be recommended in this setting. [72](#) In patients with biopsy-proven PCa and at intermediate to high risk of metastases, 68Ga-PSMA PET / CT accurately detects lymph node metastases prior to primary lymph node dissection, with a reported sensitivity, specificity, NPV and PPV of 86%, 88%, 92% and 80% respectively in one series. [73](#) 68Ga-PSMA PET / CT also has demonstrated superior performance when compared with morphological imaging alone (CT or MRI) for the correct identification of lymph node metastases in one small retrospective study [74](#)
- In re-staging of prostate cancer, conventional bone scintigraphy and CT have limited detection rates for metastases at low serum PSA levels, hence most guidelines recommend such imaging for patients who have symptomatic recurrent prostate cancer or when PSA levels > 10ng/ml. [72](#), [75](#) Biochemical recurrence following radical prostatectomy is expected with PSA levels > 0.2ng/ml hence imaging techniques with improved sensitivity would be valuable
- 68Ga-PSMA PET is a promising new technique in re-staging of prostate cancer and it is increasingly being used in this setting. In one study of a cohort of patients with suspected prostate cancer recurrence and a median PSA level of 4.6 ng/ml, at least one lesion typical of prostate cancer was found in 83% of patients. The detection rates were found to be 50% for PSA values > 2ng/ml. [76](#), [77](#) When compared directly to 18F-fluoroethylcholine, 68Ga-PSMA PET / CT has higher sensitivity (71% vs 86.9% respectively), specificity (86.9% vs 93.1%), PPV (67.3% vs 75.7%) and NPV (88.8% vs 96.6%) with an overall higher accuracy (82.2% vs 91.9%) for the detection of metastatic lesions prior to salvage lymphadenectomy
- The reported sensitivity of 11C-choline and 18F-fluorocholine for primary tumour detection ranges from 10 %-67 %, too low to be of clinical interest for detecting nodal metastasis

- In restaging patients with biochemical failure after local treatment with curative intent choline PET / CT may be useful for guiding re-biopsy in highly selected patients suffering from clinically suspected PCa with repeatedly negative prostate biopsies. Sensitivity is crucially dependent on the level of serum PSA, with a linear relationship
- 18F-fluorodeoxyglucose (18F-FDG) FDG PET is not used in prostate cancer staging as prostate cancer has variable accumulation of FDG and FDG is excreted in the urine leading to poor visualisation of the lower urinary tract.

References

Date of literature search: November 2015

The search methodology is available on request. [Email](#)

References are graded from Level I to V according to the Oxford Centre for Evidence-Based Medicine, Levels of Evidence. [Download the document](#)

1. **Localised prostate cancer: A guide for men and their families.** © **Cancer Council Australia** Australian Prostate Cancer Collaboration; 2010 [cited 2015 November]. Fourth edition October 2010: Available from: [View the reference](#)
2. **Prostate cancer in Australia** Cancer Australia, Australian Government; 2015 [cited 2015 October 6]. Available from:[View the reference](#)
3. Kelloff GJ, Choyke P, Coffey DS, Prostate Cancer Imaging Working Group. **Challenges in clinical prostate cancer: role of imaging.** AJR Am J Roentgenol. 2009;192(6):1455-70. (Guidelines). [View the reference](#)
4. Australian Institute of Health Welfare. **Prostate cancer in Australia.** Cancer series no. 79. Canberra: AIHW 2013 [cited 2015 October 12]. Available from: [View the reference](#)
5. Shaw GL, Thomas BC, Dawson SN, Srivastava G, Vowler SL, Gnanapragasam VJ, et al. **Identification of pathologically insignificant prostate cancer is not accurate in unscreened men.** Br J Cancer. 2014;110(10):2405-11. (Level IV evidence). [View the reference](#)
6. Mottet N, Bellmunt J, Briers E, van den Bergh RCN, Bolla M, van Casteren NJ, et al. **Guidelines of Prostate Cancer** European Association of Urology (EAU) (Guidelines); 2015 [cited 2015 October 16]. Available from: [View the reference](#)
7. Zhang ZX, Yang J, Zhang CZ, Li KA, Quan QM, Wang XF, et al. **The value of magnetic resonance imaging in the detection of prostate cancer in patients with previous negative biopsies and elevated prostate-specific antigen levels: a meta-analysis** Acad Radiol. 2014;21(5):578-89. (Level II evidence). [View the reference](#)
8. Heidenreich A, Bastian PJ, Bellmunt J, Bolla M, Joniau S, van der Kwast T, et al. **EAU guidelines on prostate cancer. part 1: screening, diagnosis, and local treatment with curative intent-update 2013** Eur Urol. 2014;65(1):124-37. (Guidelines). [View the reference](#)
9. Lawrentschuk N, Thompson J, Frydenberg M, Thompson L, Stricker P **Status of mp-MRI prostate 2012: Report from the MRI prostate working party.** ANZUCA (Australian and New Zealand Urologic Cancer Association)

- and USANZ (Urological Society of Australia and New Zealand). 2012:(Guidelines). [View the reference](#)
10. **PSA testing and early management of test-detected prostate cancer: clinical practice guidelines** [Internet]. Cancer Council Australia; 2016 [cited 2016 July 28]. Available from: [View the reference](#)
 11. Mohler JL, Kantoff PW, Armstrong AJ, Bahnson RR, Cohen M, D'Amico AV, et al. **Prostate cancer, version 2.2014** J Natl Compr Canc Netw. 2014;12(5):686-718. (Guidelines). [View the reference](#)
 12. Barentsz JO, Richenberg J, Clements R, Choyke P, Verma S, Villeirs G, et al. **ESUR prostate MR guidelines 2012**. Eur Radiol. 2012;22(4):746-57. (Guidelines). [View the reference](#)
 13. Eberhardt SC, Carter S, Casalino DD, Merrick G, Frank SJ, Gottschalk AR, et al. **ACR Appropriateness Criteria prostate cancer--pretreatment detection, staging, and surveillance**. J Am Coll Radiol. 2013;10(2):83-92. (Guidelines). [View the reference](#)
 14. Muller BG, Futterer JJ, Gupta RT, Katz A, Kirkham A, Kurhanewicz J, et al. **The role of magnetic resonance imaging (MRI) in focal therapy for prostate cancer: recommendations from a consensus panel**. BJU Int. 2014;113(2):218-27. (Guidelines). [View the reference](#)
 15. Roberts CC, Daffner RH, Weissman BN, Bancroft L, Bennett DL, Blebea JS, et al. **ACR appropriateness criteria on metastatic bone disease**. J Am Coll Radiol. 2010;7(6):400-9. (Guidelines). [View the reference](#)
 16. **Prostate cancer: diagnosis and treatment** National Institute for Health and Care Excellence (NICE) (Guidelines); 2014 [cited 2015 October 16]. Available from: [View the reference](#)
 17. Kirkham AP, Haslam P, Keanie JY, McCafferty I, Padhani AR, Punwani S, et al. **Prostate MRI: who, when, and how? Report from a UK consensus meeting**. Clin Radiol. 2013;68(10):1016-23. (Guidelines). [View the reference](#)
 18. Pokorny MR, de Rooij M, Duncan E, Schroder FH, Parkinson R, Barentsz JO, et al. **Prospective study of diagnostic accuracy comparing prostate cancer detection by transrectal ultrasound-guided biopsy versus magnetic resonance (MR) imaging with subsequent MR-guided biopsy in men without previous prostate biopsies**. Eur Urol. 2014;66(1):22-9. (Level II evidence). [View the reference](#)
 19. Sciarra A, Barentsz J, Bjartell A, Eastham J, Hricak H, Panebianco V, et al. **Advances in magnetic resonance imaging: how they are changing the management of prostate cancer**. Eur Urol. 2011;59(6):962-77. (Review article). [View the reference](#)
 20. Jambor I, Kahkonen E, Taimen P, Merisaari H, Saunavaara J, Alanen K, et al. **Prebiopsy multiparametric 3T prostate MRI in patients with elevated PSA, normal digital rectal examination, and no previous biopsy**. J Magn Reson Imaging. 2015;41(5):1394-404. (Level II/III evidence). [View the reference](#)
 21. Futterer JJ, Briganti A, De Visschere P, Emberton M, Giannarini G, Kirkham A, et al. **Can Clinically Significant Prostate Cancer Be Detected with Multiparametric Magnetic Resonance Imaging? A Systematic Review of the Literature**. Eur Urol. 2015;68(6):1045-53. [Epub ahead of print]. (Level II evidence). [View the reference](#)
 22. Valerio M, Donaldson I, Emberton M, Ehdai B, Hadaschik BA, Marks LS, et al. **Detection of Clinically Significant Prostate Cancer Using Magnetic**

- Resonance Imaging-Ultrasound Fusion Targeted Biopsy: A Systematic Review** Eur Urol. 2015;68(1):8-19. (Level II evidence). [View the reference](#)
23. Moore CM, Robertson NL, Arsanious N, Middleton T, Villers A, Klotz L, et al. **Image-guided prostate biopsy using magnetic resonance imaging-derived targets: a systematic review.** Eur Urol. 2013;63(1):125-40. (Level II evidence). [View the reference](#)
24. Roethke M, Anastasiadis AG, Lichy M, Werner M, Wagner P, Kruck S, et al. **MRI-guided prostate biopsy detects clinically significant cancer: analysis of a cohort of 100 patients after previous negative TRUS biopsy** World J Urol. 2012;30(2):213-8. (Level III/IV evidence). [View the reference](#)
25. Barrett T, Turkbey B, Choyke PL. **I-RADS version 2: what you need to know.** Clin Radiol. 2015;70(11):1165-76. (Review article). [View the reference](#)
26. Weinreb JC, Barentsz JO, Choyke PL, Cornud F, Haider MA, Macura KJ, et al. **PI-RADS Prostate Imaging - Reporting and Data System: 2015, Version 2.** Eur Urol. 2016;69(1):16-40. (Guidelines). [View the reference](#)
27. Hamoen EH, de Rooij M, Witjes JA, Barentsz JO, Rovers MM. **Use of the Prostate Imaging Reporting and Data System (PI-RADS) for Prostate Cancer Detection with Multiparametric Magnetic Resonance Imaging: A Diagnostic Meta-analysis.** Eur Urol. 2015;67(6):1112-21. (Level III evidence). [View the reference](#)
28. Renard-Penna R, Mozer P, Cornud F, Barry-Delongchamps N, Bruguere E, Portalez D, et al. **Prostate Imaging Reporting and Data System and Likert Scoring System: Multiparametric MR Imaging Validation Study to Screen Patients for Initial Biopsy.** Radiology. 2015;275(2):458-68. (Level II evidence). [View the reference](#)
29. Portalez D, Mozer P, Cornud F, Renard-Penna R, Misrai V, Thoulouzan M, et al. **Validation of the European Society of Urogenital Radiology scoring system for prostate cancer diagnosis on multiparametric magnetic resonance imaging in a cohort of repeat biopsy patients.** Eur Urol. 2012;62(6):986-96. (Level II/III). [View the reference](#)
30. Kasel-Seibert M, Lehmann T, Aschenbach R, Guettler FV, Abubrig M, Grimm MO, et al. **Assessment of PI-RADS v2 for the Detection of Prostate Cancer.** Eur J Radiol. 2016;85(4):726-31. (Level III evidence). [View the reference](#)
31. Baldisserotto M, Neto EJ, Carvalhal G, de Toledo AF, de Almeida CM, Cairoli CE, et al. **Validation of PI-RADS v.2 for prostate cancer diagnosis with MRI at 3T using an external phased-array coil.** J Magn Reson Imaging. 2016:(Level III evidence). [View the reference](#)
32. Vargas HA, Hotker AM, Goldman DA, Moskowitz CS, Gondo T, Matsumoto K, et al. **Updated prostate imaging reporting and data system (PI-RADS v2) recommendations for the detection of clinically significant prostate cancer using multiparametric MRI: critical evaluation using whole-mount pathology as standard of reference.** Eur Radiol. 2015:(Level IV evidence). [View the reference](#)
33. Salami SS, Ben-Levi E, Yaskiv O, Ryniker L, Turkbey B, Kavoussi LR, et al. **In patients with a previous negative prostate biopsy and a suspicious lesion on magnetic resonance imaging, is a 12-core biopsy still necessary in addition to a targeted biopsy?** BJU Int. 2015;115(4):562-70. (Level III evidence). [View the reference](#)



34. Hambrock T, Somford DM, Hoeks C, Bouwense SA, Huisman H, Yakar D, et al. **Magnetic resonance imaging guided prostate biopsy in men with repeat negative biopsies and increased prostate specific antigen.** J Urol. 2010;183(2):520-7. (Level III evidence). [View the reference](#)
35. Schoots IG, Roobol MJ, Nieboer D, Bangma CH, Steyerberg EW, Hunink MG. **Magnetic Resonance Imaging-targeted Biopsy May Enhance the Diagnostic Accuracy of Significant Prostate Cancer Detection Compared to Standard Transrectal Ultrasound-guided Biopsy: A Systematic Review and Meta-analysis.** Eur Urol. 2015;68(3):438-50. (Level II evidence). [View the reference](#)
36. Overduin CG, Futterer JJ, Barentsz JO. **MRI-guided biopsy for prostate cancer detection: a systematic review of current clinical results.** Curr Urol Rep. 2013;14(3):209-13. (Level II evidence). [View the reference](#)
37. Hoeks CM, Schouten MG, Bomers JG, Hoogendoorn SP, Hulsbergen-van de Kaa CA, Hambrock T, et al. **Three-Tesla magnetic resonance-guided prostate biopsy in men with increased prostate-specific antigen and repeated, negative, random, systematic, transrectal ultrasound biopsies: detection of clinically significant prostate cancers.** Eur Urol. 2012;62(5):902-9. (Level III evidence). [View the reference](#)
38. Polanec SH, Helbich TH, Margreiter M, Klingler HC, Kubin K, Susani M, et al. **Magnetic resonance imaging-guided prostate biopsy: institutional analysis and systematic review** Rofo. 2014;186(5):501-7. (Level II evidence). [View the reference](#)
39. Dickinson L, Ahmed HU, Allen C, Barentsz JO, Carey B, Futterer JJ, et al. **Clinical applications of multiparametric MRI within the prostate cancer diagnostic pathway.** Urol Oncol. 2013;31(3):281-4. (Review article). [View the reference](#)
40. Quentin M, Blondin D, Arsov C, Schimmoller L, Hiester A, Godehardt E, et al. **Prospective evaluation of magnetic resonance imaging guided in-bore prostate biopsy versus systematic transrectal ultrasound guided prostate biopsy in biopsy naive men with elevated prostate specific antigen** J Urol. 2014;192(5):1374-9. (Level III evidence). [View the reference](#)
41. Ouzzane A, Puech P, Lemaitre L, Leroy X, Nevoux P, Betrouni N, et al. **Combined multiparametric MRI and targeted biopsies improve anterior prostate cancer detection, staging, and grading.** Urology. 2011;78(6):1356-62. (Level III/IV evidence). [View the reference](#)
42. Sciarra A, Panebianco V, Ciccariello M, Salciccia S, Cattarino S, Lisi D, et al. **Value of magnetic resonance spectroscopy imaging and dynamic contrast-enhanced imaging for detecting prostate cancer foci in men with prior negative biopsy.** Clin Cancer Res. 2010;16(6):1875-83. (Level II/III evidence). [View the reference](#)
43. Lawrentschuk N, Haider MA, Daljeet N, Evans A, Toi A, Finelli A, et al. **'Prostatic evasive anterior tumours': the role of magnetic resonance imaging** BJU Int. 2010;105(9):1231-6. (Level IV evidence). [View the reference](#)
44. Komai Y, Numao N, Yoshida S, Matsuoka Y, Nakanishi Y, Ishii C, et al. **High diagnostic ability of multiparametric magnetic resonance imaging to detect anterior prostate cancer missed by transrectal 12-core biopsy.** J Urol. 2013;190(3):867-73. (Level III evidence). [View the reference](#)



45. Carter HB, Partin AW, Walsh PC, Trock BJ, Veltri RW, Nelson WG, et al. **Gleason score 6 adenocarcinoma: should it be labeled as cancer?** J Clin Oncol. 2012;30(35):4294-6. (Review article). [View the reference](#)
46. Wysock JS, Rosenkrantz AB, Huang WC, Stifelman MD, Lepor H, Deng FM, et al. **A prospective, blinded comparison of magnetic resonance (MR) imaging-ultrasound fusion and visual estimation in the performance of MR-targeted prostate biopsy: the PROFUS trial.** Eur Urol. 2014;66(2):343-51. (Level II evidence). [View the reference](#)
47. Gayet M, van der Aa A, Beerlage HP, Schrier BP, Mulders PF, Wijkstra H. **The value of magnetic resonance imaging and ultrasonography (MRI/US)-fusion biopsy platforms in prostate cancer detection: a systematic review.** BJU Int. 2015:13247. [Epub ahead of print]. (Level I/II evidence). [View the reference](#)
48. Radtke JP, Teber D, Hohenfellner M, Hadaschik BA. **The current and future role of magnetic resonance imaging in prostate cancer detection and management.** Transl Androl Urol. 2015;4(3):326-41. (Review article). [View the reference](#)
49. Yacoub JH, Verma S, Moulton JS, Eggener S, Aytekin O. **Imaging-guided prostate biopsy: conventional and emerging techniques.** Radiographics. 2012;32(3):819-37. (Review article). [View the reference](#)
50. Kuru TH, Roethke MC, Seidenader J, Simpfendorfer T, Boxler S, Alammari K, et al. **Critical evaluation of magnetic resonance imaging targeted, transrectal ultrasound guided transperineal fusion biopsy for detection of prostate cancer.** J Urol. 2013;190(4):1380-6. (Level III evidence). [View the reference](#)
51. Grummet JP, Weerakoon M, Huang S, Lawrentschuk N, Frydenberg M, Moon DA, et al. **Sepsis and 'superbugs': should we favour the transperineal over the transrectal approach for prostate biopsy?** BJU Int. 2014;114(3):384-8. (Level III/IV evidence). [View the reference](#)
52. Takenaka A, Hara R, Ishimura T, Fujii T, Jo Y, Nagai A, et al. **A prospective randomized comparison of diagnostic efficacy between transperineal and transrectal 12-core prostate biopsy.** Prostate Cancer Prostatic Dis. 2008;11(2):134-8. (Level II/III evidence). [View the reference](#)
53. Scattoni V, Maccagnano C, Capitanio U, Gallina A, Briganti A, Montorsi F. **Random biopsy: when, how many and where to take the cores?** World J Urol. 2014;32(4):859-69. (Review article). [View the reference](#)
54. Scattoni V, Russo A, Di Trapani E, Capitanio U, La Croce G, Montorsi F. **Repeated biopsy in the detection of prostate cancer: when and how many cores.** Arch Ital Urol Androl. 2014;86(4):311-3. (Review article). [View the reference](#)
55. van Hove A, Savoie PH, Maurin C, Brunelle S, Gravis G, Salem N, et al. **Comparison of image-guided targeted biopsies versus systematic randomized biopsies in the detection of prostate cancer: a systematic literature review of well-designed studies.** World J Urol. 2014;32(4):847-58. (Level I/II evidence). [View the reference](#)
56. Ploussard G, Epstein JI, Montironi R, Carroll PR, Wirth M, Grimm MO, et al. **The contemporary concept of significant versus insignificant prostate cancer.** Eur Urol. 2011;60(2):291-303. (Review article). [View the reference](#)
57. Rodrigues G, Warde P, Pickles T, Crook J, Brundage M, Souhami L, et al. **Pre-treatment risk stratification of prostate cancer patients: A critical review.** Can Urol Assoc J. 2012;6(2):121-7. (Review article). [View the reference](#)

[reference](#)

58. Carter HB. **American Urological Association (AUA) guideline on prostate cancer detection: process and rationale.** BJU Int. 2013;112(5):543-7. (Guidelines). [View the reference](#)
59. National Institute for Health and Care Excellence. **Prostate cancer overview** [<http://pathways.nice.org.uk/>]. London, United Kingdom; National Institute for Health and Care Excellence: [updated 2014 January; cited 2015 May 4]. Available at: [View the reference](#)
60. Horwich A, Parker C, Bangma C, Kataja V. **Prostate cancer: ESMO Clinical Practice Guidelines for diagnosis, treatment and follow-up.** Ann Oncol. 2010;21 Suppl 5:v129-33. (Guidelines). [View the reference](#)
61. Chen RC, Rumble RB, Loblaw DA, Finelli A, Ehdai B, Cooperberg MR, et al. **Active Surveillance for the Management of Localized Prostate Cancer (Cancer Care Ontario Guideline): American Society of Clinical Oncology Clinical Practice Guideline Endorsement.** J Clin Oncol. 2016:(Guidelines). [View the reference](#)
62. van den Bergh RC, Ahmed HU, Bangma CH, Cooperberg MR, Villers A, Parker CC. **Novel tools to improve patient selection and monitoring on active surveillance for low-risk prostate cancer: a systematic review.** Eur Urol. 2014;65(6):1023-31. (Level II evidence). [View the reference](#)
63. Moore CM, Petrides N, Emberton M. **Can MRI replace serial biopsies in men on active surveillance for prostate cancer?** Curr Opin Urol. 2014;24(3):280-7. (Review article). [View the reference](#)
64. Schoots IG, Petrides N, Giganti F, Bokhorst LP, Rannikko A, Klotz L, et al. **Magnetic Resonance Imaging in Active Surveillance of Prostate Cancer: A Systematic Review.** Eur Urol. 2015;67(4):627-36. (Level II evidence). [View the reference](#)
65. Klotz L, Emberton M. **Management of low risk prostate cancer: active surveillance and focal therapy.** Curr Opin Urol. 2014;24(3):270-9. (Review article). [View the reference](#)
66. **Prostate Cancer Staging 7th Edition:** American Joint Committee on Cancer (AJCC); 2009 [cited 2015 November 6]. Available from: [View the reference](#)
67. Leung D, Krishnamoorthy S, Schwartz L, Divgi C. **Imaging approaches with advanced prostate cancer: techniques and timing.** Can J Urol. 2014;21(2 Supp 1):42-7. (Review article). [View the reference](#)
68. Lecouvet FE, Geukens D, Stainier A, Jamar F, Jamart J, d'Othee BJ, et al. **Magnetic resonance imaging of the axial skeleton for detecting bone metastases in patients with high-risk prostate cancer: diagnostic and cost-effectiveness and comparison with current detection strategies** J Clin Oncol. 2007;25(22):3281-7. (Level III evidence). [View the reference](#)
69. Pasoglou V, Larbi A, Collette L, Annet L, Jamar F, Machiels JP, et al. **One-step TNM staging of high-risk prostate cancer using magnetic resonance imaging (MRI): toward an upfront simplified "all-in-one" imaging approach?** Prostate. 2014;74(5):469-77. (Level III evidence). [View the reference](#)
70. Crawford ED, Stone NN, Yu EY, Koo PJ, Freedland SJ, Slovin SF, et al. **Challenges and recommendations for early identification of metastatic disease in prostate cancer.** Urology. 2014;83(3):664-9. (Review article). [View the reference](#)
71. Afshar-Oromieh A, Malcher A, Eder M, Eisenhut M, Linhart HG, Hadaschik



- BA, et al. **PET imaging with a [68Ga]gallium-labelled PSMA ligand for the diagnosis of prostate cancer: biodistribution in humans and first evaluation of tumour lesions.** Eur J Nucl Med Mol Imaging. 2013;40(4):486-95. (Level III/IV evidence). [View the reference](#)
72. Maurer T, Eiber M, Schwaiger M, Gschwend JE. **Current use of PSMA-PET in prostate cancer management.** Nat Rev Urol. 2016;13(4):226-35. (Review article). [View the reference](#)
73. Herlemann A, Wenter V, Kretschmer A, Thierfelder KM, Bartenstein P, Faber C, et al. **Ga-PSMA Positron Emission Tomography/Computed Tomography Provides Accurate Staging of Lymph Node Regions Prior to Lymph Node Dissection in Patients with Prostate Cancer.** Eur Urol. 2016:(Level III evidence). [View the reference](#)
74. Maurer T, Gschwend JE, Rauscher I, Souvatzoglou M, Haller B, Weirich G, et al. **Diagnostic Efficacy of Gallium-PSMA Positron Emission Tomography Compared to Conventional Imaging for Lymph Node Staging of 130 Consecutive Patients with Intermediate to High Risk Prostate Cancer.** J Urol. 2015:(Level III evidence). [View the reference](#)
75. **The European Association of Urology Prostate Cancer Guidelines** [Internet]. 2016 [cited 2016 August 2]. Available from: [View the reference](#)
76. Evangelista L, Briganti A, Fanti S, Joniau S, Reske S, Schiavina R, et al. **New Clinical Indications for F/C-choline, New Tracers for Positron Emission Tomography and a Promising Hybrid Device for Prostate Cancer Staging: A Systematic Review of the Literature.** Eur Urol. 2016:(Level I/II evidence). [View the reference](#)
77. Afshar-Oromieh A, Avtzi E, Giesel FL, Holland-Letz T, Linhart HG, Eder M, et al. **The diagnostic value of PET/CT imaging with the (68)Ga-labelled PSMA ligand HBED-CC in the diagnosis of recurrent prostate cancer.** Eur J Nucl Med Mol Imaging. 2015;42(2):197-209. (Level IV evidence). [View the reference](#)

Information for Consumers

Information from this website	Information from the Royal Australian and New Zealand College of Radiologists' website
<p>Consent to Procedure or Treatment</p> <p>Radiation Risks of X-rays and Scans</p> <p>Bone Scan</p> <p>Computed Tomography (CT)</p>	<p>Computed Tomography (CT)</p> <p>Contrast Medium (Gadolinium versus Iodine)</p> <p>Gadolinium Contrast Medium</p> <p>Iodine-Containing Contrast Medium</p>

Magnetic Resonance Imaging (MRI)	Magnetic Resonance Imaging (MRI)
Ultrasound	Plain Radiography/X-rays
Chest Radiograph (X-ray)	Radiation Risk of Medical Imaging During Pregnancy
	Radiation Risk of Medical Imaging for Adults and Children
	Ultrasound
	MRI Scan of the Rectum
	Nuclear Medicine Bone Scan
	Nuclear Medicine
	MRI of the Prostate
	Ultrasound Guided Prostate Biopsy

Copyright

© Copyright 2016, Department of Health Western Australia. All Rights Reserved. This web site and its content has been prepared by The Department of Health, Western Australia. The information contained on this web site is protected by copyright.

Legal Notice

Please remember that this leaflet is intended as general information only. It is not definitive and The Department of Health, Western Australia can not accept any legal liability arising from its use. The information is kept as up to date and accurate as possible, but please be warned that it is always subject to change

.

File Formats

Some documents for download on this website are in a Portable Document Format (PDF). To read these files you might need to download Adobe Acrobat Reader.





[Legal Matters](#)