

Diagnostic Imaging Pathways - Bladder Cancer (Staging)

Population Covered By The Guidance

This pathway provides guidance on the staging of patients with bladder cancer confirmed with histology.

Date reviewed: January 2012

Date of next review: 2017/2018






Published: September 2012

Quick User Guide

Move the mouse cursor over the **PINK** text boxes inside the flow chart to bring up a pop up box with salient points.

Clicking on the **PINK** text box will bring up the full text.

The relative radiation level (RRL) of each imaging investigation is displayed in the pop up box.

SYMBOL	RRL	EFFECTIVE DOSE RANGE
	None	0
	Minimal	< 1 millisieverts
	Low	1-5 mSv
	Medium	5-10 mSv
	High	>10 mSv

Pathway Diagram

Date reviewed: January 2012
 Please note that this pathway is subject to review and revision.

Other imaging modalities:

- MRI
- Ultrasound
- Intravenous Urography
- Nuclear Medicine / PET

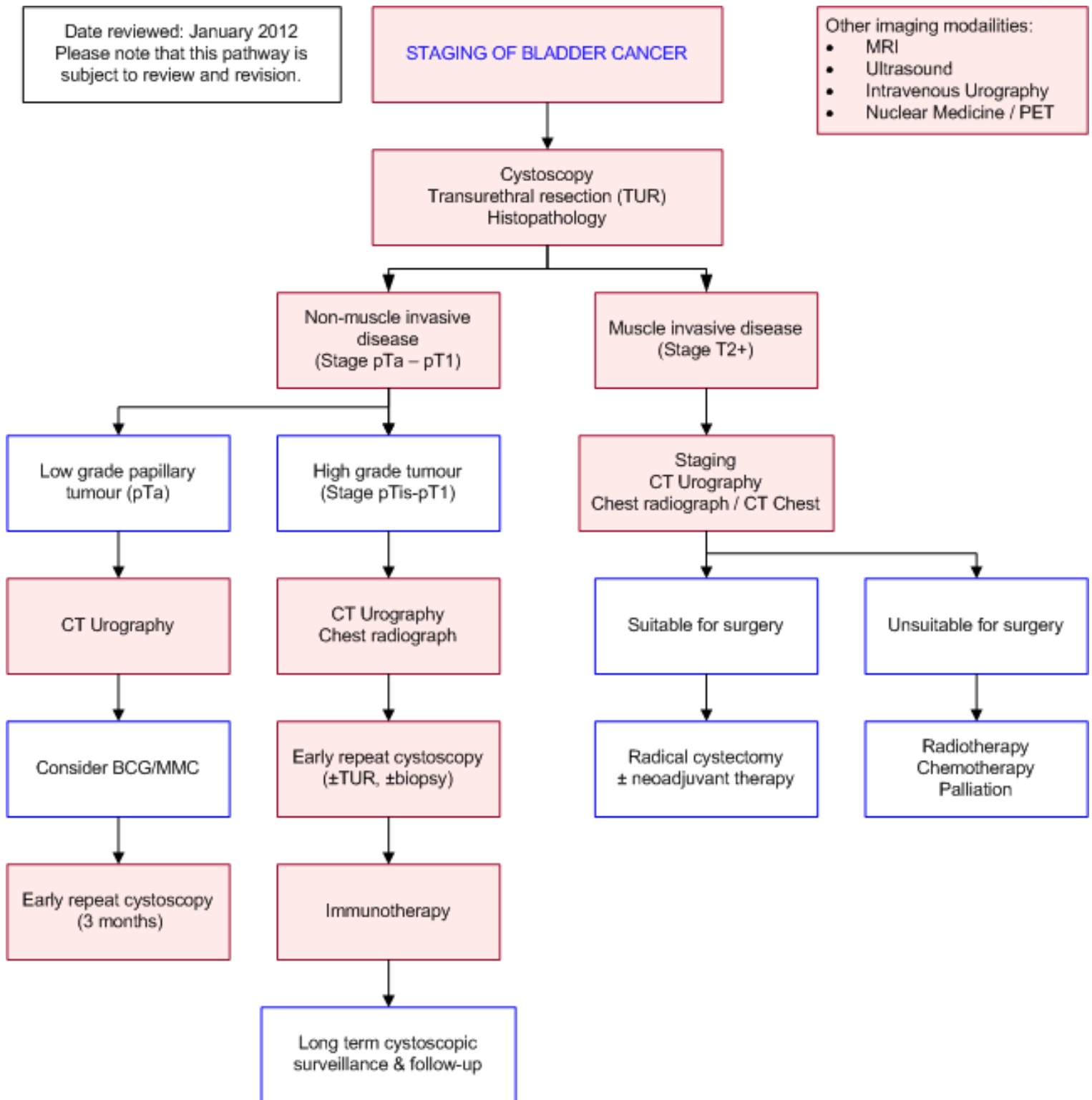
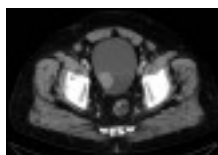

Image Gallery

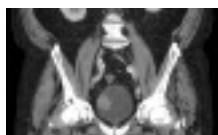Note: These images open in a new page



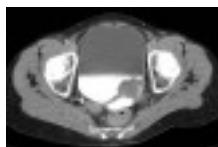
Papillary TCC

Images 1a & 1b: 77yo M had an incidental bladder mass detected on CT abdomen. Patient underwent TURBT & pathology confirmed low grade papillary TCC with no evidence of stromal invasion. Stage: T2N0M0.

1b



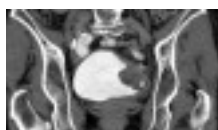2a



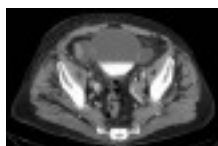
Invasive TCC

Images 2a & 2b: 66yo F with history of recurrent TCC of bladder & left ureter. Follow-up CT shows left-sided posterolateral bladder tumour invading into adjacent ileum. No lymphadenopathy or distant metastatic disease was seen. Stage: T4N0M0.

2b



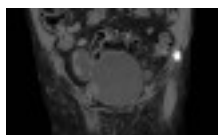
3a



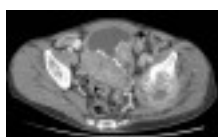
Squamous TCC

Images 3a & 3b: 91yo M presented with frank haematuria. CT urograph showed a bladder with thickened walls and bilateral diverticulae. The larger right diverticulum had nodular wall thickening of its lateral wall. The patient later underwent open diverticulectomy. Pathological findings were of TCC with squamous differentiation. Stage: T3N0M0.

3b



4a



Metastatic TCC

Images 4a & 4b: 60yo M presented with left hip pain, with initial plain films showing a mixed lytic-sclerotic lesion of his left femur & pelvis. CT abdo/pelvis showed multiple large calcific tumours within the bladder, obstructing the left ureter & causing hydronephrosis. There was a large metastatic deposit involving the left hemipelvis and acetabulum. Pathological findings showed high grade TCC with squamous differentiation. Stage: T4N0M1.

4b



Teaching Points

- Accurate staging of bladder cancer allows for optimal treatment and prognostication of the individual patient. It is important to differentiate between non-muscle-invasive lesions and muscle invasive bladder lesions
- Conventional rigid cystoscopy is the gold standard for diagnosis of bladder tumours, followed closely by flexible cystoscopy. Though small biopsies may be retrieved via a flexible cystoscope, rigid cystoscopy allows for tissue biopsy and formal tumour resection. Tissue histopathology provides further tumour staging information
- Radiologic investigations are used in bladder cancer staging for further clarifying the extent of local disease and looking for nodal & metastatic spread
- Distant metastatic spread is rarely seen at time of presentation. The most common sites of spread can be investigated appropriately using chest radiography (and/or CT chest) and CT abdomen



Bladder Cancer Staging

- Bladder cancer is the 10th most common cancer in Australians (the 5th most common in Australian men). Around 2500 new cases are diagnosed every year [1](#)
- The majority of bladder cancers are transitional cell carcinomas (TCCs), with the remaining 10% being squamous cell carcinomas (SCCs) and adenocarcinomas [2](#)
- TCCs are characterised by a high recurrence rate and multiplicity. Once a malignancy occurs in one part of the urothelium, the rest of the mucosa seems primed to become malignant ("field effect" theory). Around 2-4% of patients with bladder TCC will eventually develop upper urinary tract tumours. [2](#) TCC also has the highest recurrence rates of any cancer, with 70% recurrence rate in patients with non-muscle invasive disease [2](#)
- The American Joint Committee on Cancer Staging (AJCC) TNM classification is the most widely used method of bladder cancer staging [3](#)
- Accurate staging is essential for therapeutic decision making and prognostic information [4](#)
- Primary Tumour (T)
 - TX - Primary tumour cannot be assessed
 - T0 - No evidence of primary tumour
 - Ta - Noninvasive papillary carcinoma
 - Tis - Carcinoma in situ: "flat tumour"
 - T1 - Tumour invades subepithelial connective tissue
 - T2 - Tumour invades muscularis propria
 - pT2a - Tumour invades superficial muscularis propria (inner half)
 - pT2b - Tumour invades deep muscularis propria (outer half)
 - T3 - Tumour invades perivesical tissue
 - pT3a - Microscopically
 - pT3b - Macroscopically (extravesical mass)
 - T4 - Tumour invades any of the following: prostatic stroma, seminal vesicles, uterus, vagina, pelvic wall, abdominal wall
 - T4a - Tumour invades prostatic stroma, uterus, vagina
 - T4b - Tumour invades pelvic wall, abdominal wall
- Regional Lymph Nodes (N)
 - NX - Lymph nodes cannot be assessed
 - N0 - No lymph node metastasis
 - N1 - Single regional lymph node metastasis in the true pelvis (hypogastric, obturator, external iliac or presacral lymph node)
 - N2 - Multiple regional lymph node metastasis in the true pelvis
 - N3 - Lymph node metastasis to the common iliac lymph nodes
- Distant Metastasis (M)
 - M0 - No distant metastasis
 - M1 - Distant metastasis

Stage Grouping	Tumour	Node	Metastases
0	Ta or Tis	N0	M0
I	T1	N0	M0
II	T2a or T2b	N0	M0
III	T3a, T3b or T4	N0	M0
IV	T4b	N0	M0
	Any T	N1, N2 or N3	M0 or M1

Computed Tomography Urography (CTU)

- Multidetector CT urography (CTU) is the preferred imaging modality to complement cystoscopy in the investigation of haematuria and the further investigation and staging of bladder cancer. [8](#) Compared to MRI, CT has better spatial and temporal resolution. It also has faster image acquisition times and is more readily accessible
- CTU is a three phase CT (non-contrast, portal venous and pyelographic phase) of the abdomen and pelvis. It has largely replaced intravenous urography as the first line radiological investigation of haematuria, due to its ability to evaluate the entire urological tract and diagnose upper and lower tracts tumours, as well as other possible causes of haematuria. The sensitivity & specificity of CTU for detecting bladder cancer is generally in the range of 79-93% and 91-99% respectively [8](#)
- In terms of local bladder cancer staging, current CT (& MRI) techniques are both unable to accurately resolve the bladder wall layers, limiting staging of T1-T3 tumours. [9](#) T3b stage tumours and higher can be more readily detected by CT. The reported accuracy in detecting extravesical spread varies from 40-92%, with a tendency to understage [3](#)
- Various techniques have been tried to improve diagnostic accuracy including insufflating the bladder with air (95% accurate vs 87% for urine filled bladder), using a scanning delay of 60s following contrast injection and delaying scanning post-TURBT until 7 days or longer [11,12](#)
- CT virtual cystoscopy is a new 3D reconstruction technique that has shown much promise. It can either be done using contrast-filled bladder as part of the routine CTU protocol, or using an air-filled bladder (which requires catheterisation). A recent meta-analysis examined 26 studies with 3084 patients, and compared the detection rates of US, CT virtual cystoscopy (CTVC) and MRVC for the initial investigation and diagnosis of bladder cancer, compared to the gold standard of conventional cystoscopy. [8](#) CTVC was shown to be the most sensitive and specific diagnostic modality (sensitivity 93.9%, specificity 98.1%) compared to the other modalities. Its major limitations compared to the conventional cystoscopy are the inability to detect flat lesions accurately and inability to provide tissue samples for histological diagnosis [13](#)
- In terms of lymph node staging, the accuracy of CT ranges from 73-92% with a tendency to understage nodal involvement. [12](#) Nodal involvement is currently judged on size criteria, and both CT & MRI are unable to detect metastatic spread in normal-sized lymph nodes, or lymph nodes enlarged by a benign process [14](#)
- Distant metastases are rarely found at the time of presentation in the majority of bladder cancers. However, it is important to evaluate the presence of distant metastases prior to any invasive curative treatments. CT & MRI are both satisfactory modalities for imaging distant metastases [14](#)

Chest Radiograph (CXR)

- Chest radiography is an effective, inexpensive, low morbidity screen for detecting asymptomatic lung metastases. [31](#) It should be a routine part of screening and follow up. In patients with equivocal CXRs or those thought to be at high risk of lung mets, a CT chest should be performed

Conventional Cystoscopy

- Cystoscopy is considered the gold standard for bladder tumour diagnosis
- There are two types of cystoscopes. Rigid cystoscopy is a more established technique that provides high image quality and very good cancer detection rates. However, it requires a general anaesthetic and is often done as a day procedure. Flexible cystoscopy was introduced in the 1980s and is a safe, relatively painless procedure that can be done in the urologist's office under local

- anaesthetic [5](#)
- Cystoscopy provides direct visualisation of the urothelium, and allows for guided biopsy and transurethral resection of the bladder tumour (TURBT). This tissue can then be used to provide histopathological diagnosis as well as local staging information [6](#)
- Bladder cancer detection rates using rigid cystoscopy are slightly better. The use of photodynamic diagnosis using blue light and hexaminolevulinate have been shown to improve cancer detection rates in both procedures and improve overall prognosis [7](#)

Other Modalities

Magnetic Resonance Imaging (MRI)

- The use of MRI urography is relatively recent and limited by availability and experience. However, some consider it to be modality of choice for primary staging of urinary bladder cancer. Compared to CT, it has better soft tissue contrast and offers multiplanar imaging, but has poorer spatial resolution and longer image acquisition times. There is good reproducibility between reviewers for staging [15](#)
- For local tumour staging, the accuracy of MRI varies from 62-85% (on average about 20% higher than CT). [16](#) Although MRI is more accurate than CT for local staging, it is also unable to differentiate the bladder wall layers well. Gadolinium enhanced MRI improves accuracy of extravesical extension to 73-100% [15](#)
- Recent studies comparing T1 & T2 weighted imaging and diffusion weighted imaging (DWI) showed improved accuracy using DWI alone and overall accuracy of 92% when using interpreting all three image types together [17,18,19](#)
- MRI nodal staging is based on size criteria (as for CT), and the accuracy is on par with CT (73-92%) [20,21](#)
- In recent years, new MRI techniques aimed at improving diagnosis of nodal metastases have arisen. These involve the use of novel contrasts such as ferumoxtran-10 and ultrasmall superparamagnetic particles of iron oxide. [21,22](#) Though these techniques show promise, they are still in their infancy and require further evaluation
- Whole-body MRI can be also be used for investigation of distant metastases. One study found it to be better than bone scintigraphy for detection of bony metastases. [23](#) Its use in TCC staging is limited due to availability and experience, and because TCC is rarely metastatic at time of presentation
- There is a risk of nephrogenic systemic fibrosis when patients with renal failure are administered gadolinium based contrast agents [More information](#)

Ultrasound

- Ultrasound does not play a significant role in the pre-operative screening of bladder cancer
- Ultrasound is often used as a first line investigation for haematuria. However, patients with high risk of bladder cancer or clinical findings suggesting malignancy should proceed to cystoscopy or CT urography
- Limitations of US include lower rates of detection compared with CT & cystoscopy (particularly with small lesions <5mm and position of lesion - worse in anterior wall), [24-26](#) inability to evaluate extent of invasion into bladder wall or extravesical extension, nor evaluation of the entire GU tract [27](#)
- A recent meta-analysis examined 26 studies with 3084 patients, and compared the detection rates of US, CT virtual cystoscopy (CTVC) and MRVC for diagnosing bladder cancer, compared to the gold standard of conventional cystoscopy. Ultrasound was shown to have poorer diagnostic value

compared to the other modalities [28](#)

Intravenous Urography (IVU)

- This investigation was traditionally the most common initial investigation of haematuria and bladder cancer. Its diagnostic value is limited by low bladder cancer detection rates of around 60% [29](#), and an inability to show extravesical disease. It has now been largely surpassed by CT urography, although it is still sometimes used for detailed imaging of the upper urinary tract [29,30](#)

Nuclear Imaging / PET

- Currently, there is no evidence for routine use of PET or PET/CT in local or nodal staging of bladder cancer. It may be helpful in the detection of distant metastases
- Multiple small trials show that PET & PET/CT show some promise in nodal staging of bladder cancer. [32-34](#) However, there are significant limitations with use of fludeoxyglucose (FDG) as the tracer, since it is excreted in urine which may obscure nearby lymph nodes
- Various techniques trialled to overcome these limitations, such as using non-urinary excreted tracers such as 11C-choline [33](#) and use of various tracers attached to anti-oncoantigen [35,36](#)

References

References are graded from Level I to V according to the Oxford Centre for Evidence-Based Medicine, Levels of Evidence. [Download the document](#)

- [1.](#) Australian Institute of Health and Welfare & Australasian Association of Cancer Registries. **Cancer in Australia: an overview, 2008. Cancer series no. 46. AIHW cat. no. CAN 42.** [View the reference](#)
- [2.](#) Vikram R, Sandler CM, Ng CS. **Imaging and staging of transitional cell carcinoma: Part I, lower urinary tract.** AJR Am J Roentgenol. 2009;192:1481-7. (Review article)
- [3.](#) Edge SB, Byrd DR, Compton CC, Fritz AG, Greene FL, Trotti A, editors. AJCC cancer staging manual. 7th ed. Chicago **American Joint Committee on Cancer.** c2009. pp497-502.
- [4.](#) MacVicar AD. **Bladder cancer staging.** BJU Int. 2000;86 Suppl 1:111-22. (Review article)
- [5.](#) Pillai PL, Sooriakumaran P. **Flexible cystoscopy: a revolution in urological practice.** Br J Hosp Med. 2009;70(10):583-5. (Review article)
- [6.](#) Battista G, Sassi C, Corcioni B, Bazzocchi A, Golfieri R, Canini R. **Latest developments in imaging of bladder cancer.** Expert Rev Anticancer Ther. 2010;10(6):881-94. (Review article)
- [7.](#) Witjes JA, Redorta JP, Jacqmin D, Sofras F, Malmström PU, Riedl C, et al. **Hexaminolevulinate-guided fluorescence cystoscopy in the diagnosis and follow-up of patients with non-muscle-invasive bladder cancer: review of the evidence and recommendations.** Eur Urol. 2010;57(4):607-14. (Review article)
- [8.](#) Battista G, Sassi C, Corcioni B, Bazzocchi A, Golfieri R, Canini R. **Latest developments in imaging of bladder cancer.** Expert Rev Anticancer Ther. 2010;10(6):881-94.
- [9.](#) Vikram R, Sandler CM, Ng CS. **Imaging and staging of transitional cell carcinoma: Part I, lower urinary tract.** AJR Am J Roentgenol. 2009;192:1481-7. (Review article)
- [10.](#) Paik ML, Scolieri MJ, Brown SL, Spirnak JP, Resnick MI, Fritz GA. **Limitations of computerized tomography in staging invasive bladder cancer before radical cystectomy.** J Urol. 2000;163(6):1693-6. (Level III evidence)
- [11.](#) Caterino M, Giunta S, Finocchi V, Giglio L, Mainiero G, Carpanese L, Crecco M. **Primary cancer of the urinary bladder: CT evaluation of the T parameter with different techniques.** Abdom

- Imaging. 2001;26(4):433-8. (Level III evidence)
12. Kim JK, Park SY, Ahn HJ, Kim CS, Cho KS. **Bladder cancer: analysis of multi-detector row helical CT enhancement pattern and accuracy in tumor detection and perivesical staging.** Radiology. 2004;231(3):725-31. (Level III evidence)
 13. Qu X, et al. **Comparison of virtual cystoscopy and ultrasonography for bladder cancer detection: a meta-analysis.** Eur J Radiol. 2011;80(2):188-97. (Level II evidence)
 14. Cowan NC, Crew JP. **Imaging bladder cancer.** Curr Opin Urol. 2010;20:409-13. (Review article)
 15. Tekes A, Kamel I, Imam K, Szarf G, Schoenberg M, Nasir K, Thompson R, Bluemke D. **Dynamic MRI of bladder cancer: evaluation of staging accuracy.** AJR Am J Roentgenol. 2005;184(1):121-7. (Level III evidence)
 16. Zhang J, Gerst S, Lefkowitz RA, Bach A. **Imaging of bladder cancer.** Radiol Clin North Am. 2007;45(1):183-205. (Review article)
 17. Takeuchi M, Sasaki S, Ito M, Okada S, Takahashi S, Kawai T, Suzuki K, Oshima H, Hara M, Shibamoto Y. **Urinary bladder cancer: diffusion-weighted MR imaging: accuracy for diagnosing T stage and estimating histologic grade.** Radiology. 2009;251(1):112-21. (Level II evidence)
 18. El-Assmy A, Abou-El-Ghar ME, Mosbah A, El-Nahas AR, Refaie HF, Hekal IA, El-Diasty T, Ibrahiem H, et al. **Bladder tumour staging: comparison of diffusion- and T2-weighted MR imaging.** Eur Radiol. 2009;19(7):1575-81. (Level II evidence)
 19. Watanabe H, Kanematsu M, Kondo H, Goshima S, Tsuge Y, Onozuka M, Moriyama N. **Preoperative T staging of urinary bladder cancer: does diffusion-weighted MRI have supplementary value?** AJR Am J Roentgenol. 2009;192(5):1361-6. (Level III evidence)
 20. Barentsz JO, Jager GJ, van Vierzen PB, Witjes JA, Strijk SP, Peters H, Karssemeijer N, Ruijs SH. **Staging urinary bladder cancer after transurethral biopsy: value of fast dynamic contrast-enhanced MR imaging.** Radiology. 1996;201:185-93. (Level III evidence)
 21. Deserno WM, Harisinghani MG, Taupitz M, Jager GJ, Witjes JA, Mulders PF, Hulsbergen van de Kaa CA, Kaufmann D, Barentsz JO. **Urinary bladder cancer: preoperative nodal staging with ferumoxtran-10-enhanced MR imaging.** Radiology. 2004;233(2):449-56. (Level II evidence)
 22. Thoeny HC, Triantafyllou M, Birkhaeuser FD, Froehlich JM, Tshering DW, Binser T, Fleischmann A, Vermathen P, Studer UE. **Combined ultrasmall superparamagnetic particles of iron oxide-enhanced and diffusion-weighted magnetic resonance imaging reliably detect pelvic lymph node metastases in normal-sized nodes of bladder and prostate cancer patients.** Eur Urol. 2009;55(4):761-9. (Level III evidence)
 23. Lauenstein TC, Goehde SC, Herborn CU, Goyen M, Oberhoff C, et al. **Whole-body MR imaging: evaluation of patients for metastases.** Radiology. 2004;233(1):139-48. (Level III evidence)
 24. Ozden et al. **Effect of bladder carcinoma location on detection rates by ultrasonography and computed tomography.** Urology. 2007;69(5):889-92. (Level III evidence)
 25. Itzchak Y, Singer D, Fischelovitch Y. **Ultrasonographic assessment of bladder tumors: 1. Tumor detection.** J Urol. 1981;126:31-3. (Level III evidence)
 26. Abu-Yousef MM, Narayana AS, Franken EA, et al. **Urinary bladder tumors studied by cystosonography. Part 1: detection.** Radiology. 1984;153:223-6 (Level III evidence)
 27. Dershaw DD, Scher HI. **Sonography in evaluation of carcinoma of bladder.** Urology. 1987;29:454-7. (Level III evidence)
 28. Qu X, et al. **Comparison of virtual cystoscopy and ultrasonography for bladder cancer detection: a meta-analysis.** Eur J Radiol. 2010;80(2):188-97. (Level II evidence)
 29. Hillman BJ, et al. **Recognition of bladder tumors by excretory urography.** Radiology. 1981;138(2):319-23. (Level III evidence)
 30. Sanderson KM, Rouprêt M. **Upper urinary tract tumour after radical cystectomy for transitional cell carcinoma of the bladder: an update on the risk factors, surveillance regimens and treatments.** BJU Int. 2007;100(1):11-6. (Review article)
 31. Kuroda M, et al. **Stage specific follow-up strategy after cystectomy for carcinoma of the**



- bladder.** Int J Urol. 2002;9(3):129-33. (Level II evidence)
32. Anjos DA, Etchebehere EC, Ramos CD, Santos AO, Albertotti C, Camargo EE. **18F-FDG PET/CT delayed images after diuretic for restaging invasive bladder cancer.** J Nucl Med. 2007;48(5):764-70. (Level III evidence)
33. Picchio M, Treiber U, Beer AJ, Metz S, Bossner P, van Randenborgh H, Paul R, Weirich G, Souvatzoglou M, Hartung R, Schwaiger M, Piert M. **Value of 11C-choline PET and contrast-enhanced CT for staging of bladder cancer: correlation with histopathologic findings.** J Nucl Med. 2006;47(6):938-44. (Level III evidence)
34. Drieskens O, Oyen R, Van Poppel H, Vankan Y, Flamen P, Mortelmans L. **FDG-PET for preoperative staging of bladder cancer.** Eur J Nucl Med Mol Imaging. 2005;32(12):1412-7. (Level III evidence)
35. Simms MS, Perkins AC, Price MR, Scholfield DP, Bishop MC. **99mTechnetium-C595 radioimmunoscinigraphy: a potential staging tool for bladder cancer.** BJU Int. 2001;88(7):686-91. (Level III evidence)
36. Hughes OD, Perkins AC, Frier M, Wastie ML, Denton G, Price MR, Denley H, Bishop MC. **Imaging for staging bladder cancer: a clinical study of intravenous 111indium-labelled anti-MUC1 mucin monoclonal antibody C595.** BJU Int. 2001;87(1):39-46. (Level III evidence)

Information for Consumers

Information from this website	Information from the Royal Australian and New Zealand College of Radiologists' website
<p>Consent to Procedure or Treatment</p> <p>Radiation Risks of X-rays and Scans</p> <p>Computed Tomography (CT)</p> <p>Magnetic Resonance Imaging (MRI)</p> <p>Positron Emission Tomography (PET)</p> <p>Ultrasound</p> <p>Ultrasound (Doppler)</p> <p>Chest Radiograph (X-ray)</p>	<p>Computed Tomography (CT)</p> <p>Contrast Medium (Gadolinium versus Iodine)</p> <p>Gadolinium Contrast Medium</p> <p>Iodine-Containing Contrast Medium</p> <p>Magnetic Resonance Imaging (MRI)</p> <p>Plain Radiography/X-rays</p> <p>Radiation Risk of Medical Imaging During Pregnancy</p> <p>Radiation Risk of Medical Imaging for Adults and Children</p> <p>Ultrasound</p> <p>Nuclear Medicine</p>



[PET Scan](#)

Copyright

© Copyright 2015, Department of Health Western Australia. All Rights Reserved. This web site and its content has been prepared by The Department of Health, Western Australia. The information contained on this web site is protected by copyright.

Legal Notice

Please remember that this leaflet is intended as general information only. It is not definitive and The Department of Health, Western Australia can not accept any legal liability arising from its use. The information is kept as up to date and accurate as possible, but please be warned that it is always subject to change

File Formats

Some documents for download on this website are in a Portable Document Format (PDF). To read these files you might need to download Adobe Acrobat Reader.



[Legal Matters](#)