

Diagnostic Imaging Pathways - Paediatric, Urinary Tract Infection

Population Covered By The Guidance

This pathway provides guidance on imaging young children following a urinary tract infection.

Date reviewed: July 2014

Date of next review: 2017/2018






Published: July 2014

Quick User Guide

Move the mouse cursor over the **PINK** text boxes inside the flow chart to bring up a pop up box with salient points.

Clicking on the **PINK** text box will bring up the full text.

The relative radiation level (RRL) of each imaging investigation is displayed in the pop up box.

SYMBOL	RRL	EFFECTIVE DOSE RANGE
	None	0
	Minimal	< 1 millisieverts
	Low	1-5 mSv
	Medium	5-10 mSv
	High	>10 mSv

Pathway Diagram

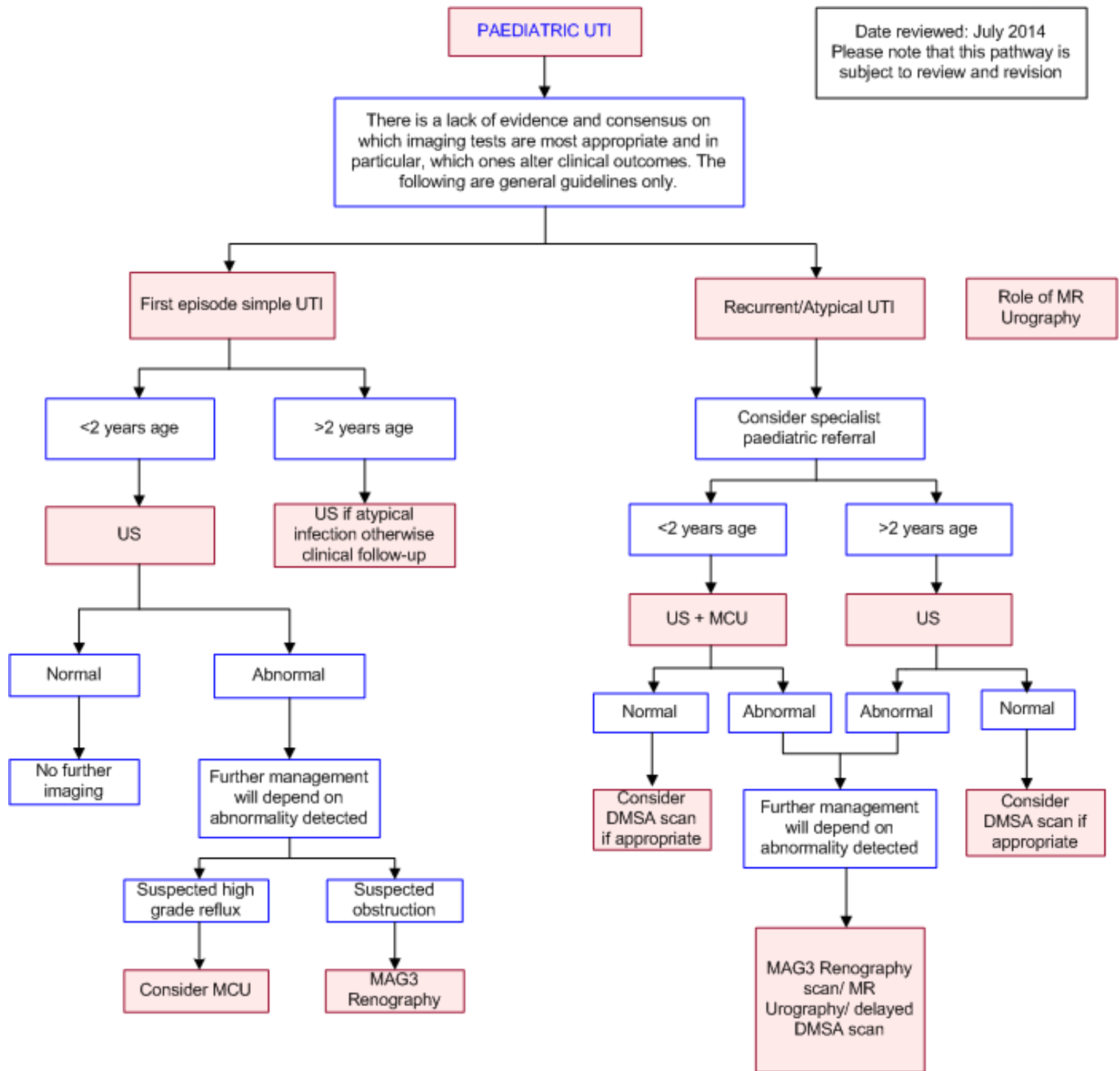
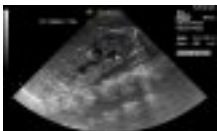

Image Gallery

Note: These images open in a new page

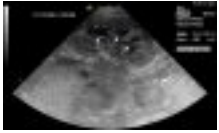1a



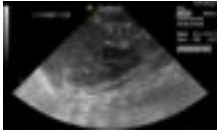Vesicoureteric Reflux

Image 1a, b and c (Ultrasound): Mild dilatation of the right renal calyces without pelvic dilatation (arrows). The left kidney appears normal. Both kidneys have normal contours and are of normal length.

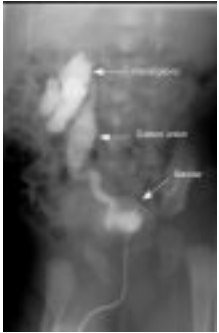1b



1c



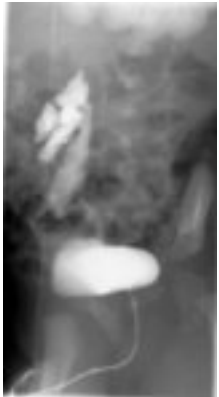1d



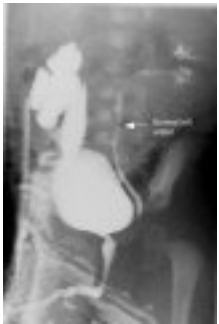Vesicoureteric Reflux

Image 1d, 1e, 1f and 1g (Micturating Cystourethrogram): Images from the same patient showing spontaneous severe vesicoureteric reflux with filling of a grossly dilated and tortuous right ureter. These appearance are consistent with Grade V reflux. On the left, there is filling of a non-distended left renal collecting system with normal appearing calyces. There is early tortuosity of the left ureter. The bladder contour is within normal limits.

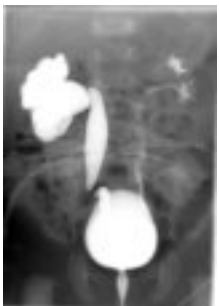1e



1f



1g



Teaching Points

- An ultrasound is considered the most appropriate initial investigation



- Able to assess renal size and morphology
- Determine if there is an outflow obstruction, e.g. PUJ Obstruction
- Further investigations are based on the child's age and the presence of risk factors for Vesicoureteric Reflux (VUR) or the grade of reflux disease if identified. These may include
 - Micturating Cystourethrogram
 - Radionuclide scan
 - MAG3 Renography

Recurrent or Atypical Urinary Tract Infection

- Recurrent urinary tract infection (UTI) is defined as either [1](#)
 - ? 2 episodes of acute pyelonephritis
 - One episode of acute pyelonephritis AND one episode of cystitis
 - ? 3 episodes of cystitis
- Atypical urinary tract infection (UTI) is defined as [1](#)
 - Systemically unwell
 - Poor urine flow
 - Abdominal or bladder mass
 - Raised creatinine
 - Septicaemia
 - Failure to respond to antibiotics within 48hrs
 - Infection with non E .coli organisms

Technetium-99m Dimercaptosuccinic Acid (DMSA) Scan

- Currently considered the reference standard for the detection of renal scarring in children with a history of urinary tract infection (UTI) [1](#)
- The study involves the intravenous injection of DMSA and scanning the kidneys with a gamma camera approximately 2-6 hours later
- The role of a DMSA scan varies between institutions but in general, it is used to detect renal scarring in patients who have evidence of vesicoureteric reflux (VUR). [2](#) This study can also detect acute pyelonephritis, however, there is a 10% false negative rate and the findings often do not alter clinical management. [3](#) In view of this, the scan is not commonly used for this purpose in Australia
- For the detection of renal scarring, it is recommended that the scan be delayed by at least 6 weeks (preferably 3-6 months) following resolution of infection to reduce false positive results
- Currently, the long term implications of finding renal parenchymal defects on DMSA remains unquantified, however, the risk for future renal impairment, hypertension and poor quality of life is thought to be low [4](#)
- For information for consumers on DMSA scans [InsideRadiology](#)

Paediatric Urinary Tract Infection (UTI)

- UTIs are relatively common in children, affecting 3.6% of boys and 11.3% of girls [5](#)
- However, the estimated prevalence of renal scarring in this population is approximately 5% (occurring more frequently in those with vesicoureteric reflux) and the risk that this will affect future renal function, blood pressure and quality of life is even lower [1](#)
- The current evidence suggests that routine imaging of all children with a first episode of UTI is

- neither clinically nor cost effective. Instead, investigations should be targeted at the very young (6)
- Generally the more aggressive a protocol the higher the sensitivity for detection of VUR and scarring but this is at a higher financial and radiation cost [7](#)
- **Paediatric UTI is still very much a controversial area and consensus is lacking on the selection and sequence of tests. Therefore, the suggested pathway are general guidelines only**

Micturating Cystourethrogram (MCU)

- Considered the reference standard for detection and grading of vesicoureteric reflux (VUR). It is also the most reliable method of evaluating associated urethral abnormalities such as posterior urethral valves [8](#)
- Involves catheterisation of the bladder and infusion of contrast media to fill the bladder. Images are taken both during filling and during micturition to check for anatomical abnormalities and VUR
- Grading of reflux is most widely based on the International Reflux System [9](#)
 - Grade 1: Reflux into normal calibre ureter only
 - Grade 2: Reflux into normal calibre ureter, renal pelvis, and calyces
 - Grade 3: Mild ureteral and pelvicalyceal dilatation but no or mild blunting of the calyceal fornices
 - Grade 4: Moderate ureteral and pelvicalyceal dilatation, with blunting of the calyceal fornices
 - Grade 5: Marked ureteral and pelvic dilatation and tortuosity, marked blunting of the calyceal fornices, and lack of papillary impressions in most calyces
- The optimal timing of the MCU in relation to the diagnosis of UTI is uncertain with some advocating the documentation of sterile urine to avoid false negative and false positive results. [8](#) Generally it is considered appropriate to wait until after completion of treatment for UTI and symptomatic improvement
- The precise relationship between VUR and renal scarring is still uncertain. Although acute pyelonephritis on a background of VUR can be damaging to the kidneys, renal scarring can also be found in the absence of VUR. It is also clear that not all small kidneys in the setting of VUR occur as a result of scarring from repeated UTIs. [1](#) Renal damage that has previously been thought to be related to scarring related to pyelonephritis is now increasingly being thought to be due to congenital origins [10-12](#)
- Disadvantages of MCU include
 - Risk of infection and urethral trauma
 - Exposure to ionising radiation
 - May be distressing to patients and parents
- For information for consumers on the MCU procedure [InsideRadiology](#)

Alternatives to Micturating Cystourethrogram (MCU)

- Contrast-enhanced voiding urosonography may be an alternative to MCU in girls depending on the local expertise. The sensitivity for the detection of VUR ranges from 86 to 93% with a specificity of 44 to 95% [1](#)
- A recent study comparing MCU with contrast induced voiding urosonography found using MCU as the reference standard that urosonography had a sensitivity of 100 percent and specificity of 84 percent for the detection of reflux detection and grading. [13](#) The efficacy of urosonography is well documented [14](#)
- Although direct and indirect radionuclide cystograms are occasionally considered in the evaluation

of VUR, there is little evidence to support its routine use in the investigation of children with a UTI. [1](#) However, some consider that they should be used to follow-up VUR as they involve a lower radiation dose and are less traumatic than an MCU

Magnetic Resonance Urography (MRU)

- MR urography is a new and evolving field of renal tract imaging and it provides both anatomical and functional information about the urinary tract in a single test without the need for ionizing radiation or iodinated contrast media [15](#)
- This technique has the potential to replace IVP and nuclear medicine renography in certain groups of patients
- MRU provides excellent anatomic depiction of the kidney and entire collecting system including the ureter and its insertion. This is useful in assessing congenital and other anatomic abnormalities of the renal tract including ectopic ureter, crossing vessels, ectopic kidneys, horseshoe kidneys, PUJ and VUJ. A study compared MRU to conventional modalities in a variety of congenital anomalies with surgical evaluation as reference and reported following sensitivities : MRU 86%, IVP 63%, Nuc Med 50%, US 44% and MCU 41% [16](#)
- Studies that compared MRU with DMSA for renal scarring reported a sensitivity of 77% and a specificity of 87% and suggested that MR urography is equal and in some cases superior to DMSA renal scintigraphy in the evaluation of both acute pyelonephritis and renal scarring [17,18](#)
- Recently, it has been recognized as an important new technique in assessing urinary tract function. MR can provide accurate assessments of split renal function as well as renal tract obstruction. It is particularly helpful in delineating obstructive and non-obstructive hydronephrosis, an important evaluation in pre and post-operative assessment of PUJ obstruction [19](#)

Mercaptoacetyl triglycerine (MAG3) Renography

- Mercaptoacetyl triglycerine (MAG3) is the preferred agent in paediatric practice [20](#)
- Useful to quantify an obstructive uropathy and can also provide information on renal vascularity and renal function
- The scan involves the intravenous administration of Tc-99m, MAG3, and diuretic, followed by serial imaging over approximately 30 minutes to 1 hour
- MAG3 renogram can be used to distinguish between a true obstruction and other causes of pelvicalyceal dilatation [20](#)

Simple Urinary Tract Infection

- Defined as a urinary tract infection (UTI) which responds well to antibiotics within 48hrs and without any features of recurrent or atypical UTI [1](#)

Renal Tract Ultrasound

- Considered the most appropriate initial investigation of urinary tract infections (UTI) in children
- Safe and non-invasive method to assess the structure of the urinary tract including renal size and morphology, pelvicalyceal and ureteric dilatation, ureterocoeles, bladder wall hypertrophy and residual bladder volume

- Ultrasound cannot reliably exclude vesicoureteric reflux (VUR). Based on a systematic review of 11 studies, the sensitivity for detecting an abnormality in the setting of VUR ranged from 10.5 to 90.9% and the specificity from 14.6 to 93.8%. [21](#) If high grade VUR is suspected on ultrasound, considering a Micturating Cystourethrogram is appropriate [22](#)
- Ultrasound may also detect severe parenchymal scarring but not as effectively as DMSA or MRU scanning. [1](#) The sensitivity ranges from 47.0 to 69.0% and the specificity from 80.4 to 100% depending on the timing of the ultrasound [21](#)
- Ultrasound should be performed at the earliest convenience unless there are atypical features in which case an obstruction or abscess may need to be excluded with an acute ultrasound [4](#)
- For information for consumers on paediatric ultrasound [InsideRadiology](#)

References

Date of literature search: July 2014

The search methodology is available on request. [Email](#)

References are graded from Level I to V according to the Oxford Centre for Evidence-Based Medicine, Levels of Evidence. [Download the document](#)

- [1.](#) National Collaborating Centre for Women's and Children's Health. **Urinary Tract Infection in Children: Diagnosis, Treatment and Long-term Management.** Clinical guideline 2007. August 2007. (Guidelines). 2007.
- [2.](#) Gordon I, Barkovics M, Pindoria S, Cole TJ, Woolf AS. **Primary vesicoureteric reflux as a predictor of renal damage in children hospitalized with urinary tract infection: a systematic review and meta-analysis.** J Am Soc Nephrol. 2003;14(3):739-44. (Level II evidence). [View the reference](#)
- [3.](#) Groshar D, Moskovitz B, Gorenberg M, Frankel A, Jerusalemi J, Livne PM, et al. **Quantitative SPECT of technetium-99m-DMSA uptake in the kidneys of normal children and in kidneys with vesicoureteral reflux: detection of unilateral kidney disease.** J Nucl Med. 1994;35(3):445-9. (Level III evidence). [View the reference](#)
- [4.](#) **Practice parameter: the diagnosis, treatment, and evaluation of the initial urinary tract infection in febrile infants and young children.** American Academy of Pediatrics. Committee on Quality Improvement. Subcommittee on Urinary Tract Infection. Pediatrics. 1999;103(4 Pt 1):843-52. (Evidence based recommendations). [View the reference](#)
- [5.](#) Coulthard MG, Lambert HJ, Keir MJ. **Occurrence of renal scars in children after their first referral for urinary tract infection.** Bmj. 1997;315(7113):918-9. (Level II evidence). [View the reference](#)
- [6.](#) Jantunen ME, Siitonen A, Ala-Houhala M, Ashorn P, Fohr A, Koskimies O, et al. **Predictive factors associated with significant urinary tract abnormalities in infants with pyelonephritis.** Pediatr Infect Dis J. 2001;20(6):597-601. (Level III evidence). [View the reference](#)
- [7.](#) La Scola C, De Mutiis C, Hewitt IK, Puccio G, Toffolo A, Zucchetta P, et al. **Different guidelines for imaging after first UTI in febrile infants: yield, cost, and radiation.** Pediatrics. 2013;131(3):e665-71. (Level II evidence). [View the reference](#)
- [8.](#) Auringer ST. **Pediatric urology update.** Urol Clin North Am. 1997;24(3):673-81. (Review article). [View the reference](#)
- [9.](#) Lebowitz RL, Olbing H, Parkkulainen KV, Smellie JM, Tamminen-Mobius TE. **International system of radiographic grading of vesicoureteric reflux. International Reflux Study in Children.** Pediatr Radiol. 1985;15(2):105-9. (Grading system). [View the reference](#)
- [10.](#) Salo J, Ikaheimo R, Tapiainen T, Uhari M. **Childhood urinary tract infections as a cause of**



- chronic kidney disease.** Pediatrics. 2011;128(5):840-7. (Level II evidence). [View the reference](#)
11. Ardissino G, Dacco V, Testa S, Bonaudo R, Claris-Appiani A, Taioli E, et al. **Epidemiology of chronic renal failure in children: data from the Italkid project.** Pediatrics. 2003;111(4 Pt 1):e382-7. (Level II evidence). [View the reference](#)
 12. Wennerstrom M, Hansson S, Jodal U, Stokland E. **Primary and acquired renal scarring in boys and girls with urinary tract infection.** J Pediatr. 2000;136(1):30-4. (Level II evidence). [View the reference](#)
 13. Wong LS, Tse KS, Fan TW, Kwok KY, Tsang TK, Fung HS, et al. **Voiding urosonography with second-generation ultrasound contrast versus micturating cystourethrography in the diagnosis of vesicoureteric reflux.** Eur J Pediatr. 2014;Epub ahead of print. (Level II evidence). [View the reference](#)
 14. Tse KS, Wong LS, Lau HY, Fok WS, Chan YH, Tang KW, et al. **Paediatric vesicoureteric reflux imaging: where are we? Novel ultrasound-based voiding urosonography.** Hong Kong Med J. 2014(Epub ahead of print). [View the reference](#)
 15. Cerwinka WH, Kirsch AJ. **Magnetic resonance urography in pediatric urology.** Curr Opin Urol. 2010;20(4):323-9. (Review article). [View the reference](#)
 16. Payabvash S, Kajbafzadeh AM, Saeedi P, Sadeghi Z, Elmi A, Mehdizadeh M. **Application of magnetic resonance urography in diagnosis of congenital urogenital anomalies in children.** Pediatr Surg Int. 2008;24(9):979-86. (Level III evidence). [View the reference](#)
 17. Kavanagh EC, Ryan S, Awan A, McCoubrey S, O'Connor R, Donoghue V. **Can MRI replace DMSA in the detection of renal parenchymal defects in children with urinary tract infections?** Pediatr Radiol. 2005;35(3):275-81. (Level III evidence). [View the reference](#)
 18. Lonergan GJ, Pennington DJ, Morrison JC, Haws RM, Grimley MS, Kao TC. **Childhood pyelonephritis: comparison of gadolinium-enhanced MR imaging and renal cortical scintigraphy for diagnosis.** Radiology. 1998;207(2):377-84. (Level III evidence). [View the reference](#)
 19. Jones RA, Grattan-Smith JD, Little S. **Pediatric magnetic resonance urography.** J Magn Reson Imaging. 2011;33(3):510-26. (Review article). [View the reference](#)
 20. D'Errico G. **The role of nuclear medicine in evaluation of vesicoureteral reflux and/or reflux nephropathy.** Rays. 2002;27(2):149-54. (Review article). [View the reference](#)
 21. Whiting P, Westwood M, Bojke L, Palmer S, Richardson G, Cooper J, et al. **Clinical effectiveness and cost-effectiveness of tests for the diagnosis and investigation of urinary tract infection in children: a systematic review and economic model.** Health Technol Assess. 2006;10(36):iii-iv, xi-xiii, 1-154. (Level I-II evidence). [View the reference](#)
 22. Roberts KB. **Urinary tract infection: clinical practice guideline for the diagnosis and management of the initial UTI in febrile infants and children 2 to 24 months.** Pediatrics. 2011;128(3):595-610. (Clinical practice guideline). [View the reference](#)

Information for Consumers

Information from this website	Information from the Royal Australian and New Zealand College of Radiologists' website
Consent to Procedure or Treatment Radiation Risks of X-rays and Scans	Magnetic Resonance Imaging (MRI) Radiation Risk of Medical Imaging for



Magnetic Resonance Imaging (MRI)	Adults and Children
Renal Scan	Ultrasound
Ultrasound	Nuclear Medicine
	Nuclear Medicine DMSA Scan
	Nuclear Medicine Renal Scan
	Children's (Paediatric) Abdominal Ultrasound
	Children's (Paediatric) Micturating Cystourethrogram
	Children's (Paediatric) Renal Ultrasound
	Making Your Child's Test or Procedure Less Stressful

Copyright

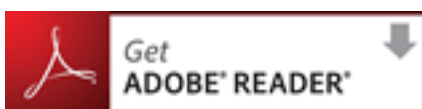
© Copyright 2015, Department of Health Western Australia. All Rights Reserved. This web site and its content has been prepared by The Department of Health, Western Australia. The information contained on this web site is protected by copyright.

Legal Notice

Please remember that this leaflet is intended as general information only. It is not definitive and The Department of Health, Western Australia can not accept any legal liability arising from its use. The information is kept as up to date and accurate as possible, but please be warned that it is always subject to change

File Formats

Some documents for download on this website are in a Portable Document Format (PDF). To read these files you might need to download Adobe Acrobat Reader.



[Legal Matters](#)