

# Diagnostic Imaging Pathways - Paediatric, Hip Pain

## Population Covered By The Guidance

This pathway provides guidance on imaging a child with hip pain.

**Date reviewed: July 2014**

**Date of next review: 2017/2018**

**Published: July 2014**

## Quick User Guide

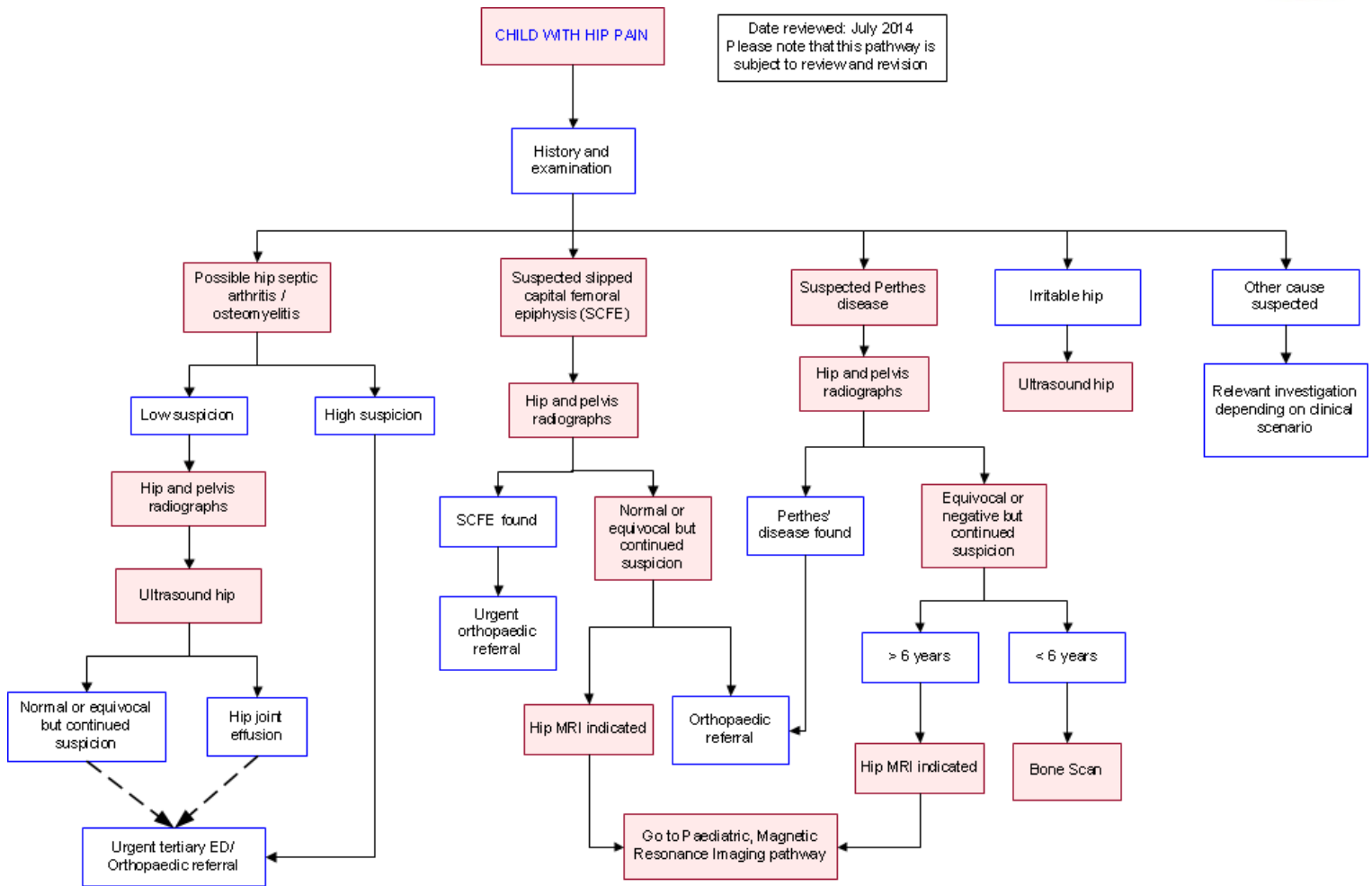
Move the mouse cursor over the **PINK** text boxes inside the flow chart to bring up a pop up box with salient points.

Clicking on the **PINK** text box will bring up the full text.

The relative radiation level (RRL) of each imaging investigation is displayed in the pop up box.

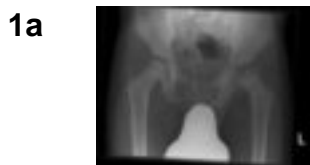SYMBOL	RRL	EFFECTIVE DOSE RANGE
	None	0
	Minimal	< 1 millisieverts
	Low	1-5 mSv
	Medium	5-10 mSv
	High	>10 mSv

## Pathway Diagram



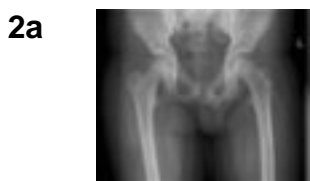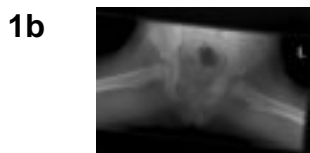
## Image Gallery

*Note: These images open in a new page*



### Perthes Disease

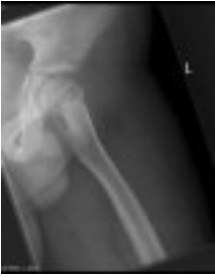Image 1a and 1b (Plain Radiography): Frontal views in a neutral position and abduction with external rotation. The left hip shows marked fragmentation and resorption of bone and broadening of the femoral head and neck in keeping with advanced Perthes Disease.



### Slipped Capital Femoral Epiphysis (SCFE)

Image 2a and 2b (Plain Radiography): SCFE is demonstrated in the left hip.

2b



## Teaching Points

- Plain hip and pelvic radiographs are appropriate initial investigations where possible. Perthes' disease is suspected. Where there are equivocal initial imaging results or continued clinical suspicion and the child is over 6 years then hip MRI is recommended, if the child is under 6 years then bone scan is recommended.
- Where there is a low suspicion of possible hip septic arthritis/osteomyelitis, hip radiographs are an appropriate initial imaging modality. Ultrasound can also be used to help establish diagnosis. Where the patient is of low risk but there is continued clinical suspicion or hip effusion is detected on ultrasound then urgent ED/Orthopaedic referral should be sought. Patients deemed as highly suspicious for these pathologies should be directly referred to ED/Orthopaedics.
- Plain hip and pelvic radiographs are appropriate initial investigations where possible suspected slipped capital femoral epiphysis (SCFE) is a potential diagnosis. Where there are normal/equivocal initial imaging findings or continued clinical suspicion then hip MRI is recommended.
- Ultrasound is recommended for the imaging of irritable hip.

## Imaging in Slipped Capital Femoral Epiphysis (SCFE)

- SCFE is a Salter Harris I fracture through the proximal femoral growth plate [10](#)
- Can be mechanically stable, where a patient can still bear weight, or mechanically unstable which typically presents as an acute physeal fracture and inability to weight-bear [11](#)
- Early symptoms can be subtle and ambiguous and the diagnosis is easily overlooked. Commonly, the early symptom is that of a dull ache that is exacerbated by exercise. The diagnosis may only become apparent when a stable slip progresses to an unstable one [11](#)
- AP and frog leg or lateral radiographs are the first investigation of choice [12](#)
- Approximately 13% of slipped capital femoral epiphyses may not be visible on AP radiographs [13](#)
- A line drawn along the lateral aspect of the femoral neck should intersect 20% of the femoral epiphysis and, if not present, indicates medial displacement of the epiphysis [14](#)
- Other findings on an AP radiograph include loss of epiphyseal height and variable physeal widening and irregularity [15](#)
- There is a high rate of bilateral involvement, with over 20% at the time of diagnosis and over 50% overall in one study [16](#)
- There is limited evidence for routine screening with MRI although cases of 'pre-slip' have been described that were only detectable with MRI
- The earliest imaging finding, evident only on MRI, is focal widening of the physis, with or without synovitis, but without slippage of the femoral head (pre-slip) [15,17](#)
- The MRI diagnosis of an early slipped capital femoral epiphysis relies on recognition of a morphologic change at the head/neck junction and abnormal signal intensity centred at the

physis, indicative of oedema [10](#)

- Patients with SCFE are at risk of avascular necrosis, chondrolysis and premature osteoarthritis [12,18](#)

## Imaging in Septic Arthritis / Osteomyelitis

- Osteomyelitis and septic arthritis should be considered in the differential diagnosis of any child with limb pain, even if there is a history of trauma. It is most common in young infants, is usually monoarticular and is frequently localised to the hip or knee joints. It can be a difficult diagnosis to make and with potentially severe consequences and for these reasons referral to a paediatric tertiary centre is generally recommended [19,20](#)
- Osteomyelitis can be present even in a well looking afebrile child [21](#)
- Septic arthritis is a medical emergency and can result from a penetrating injury, haematogenous spread or spread from adjacent sites of infection. Haematogenous spread is more common in neonates and infants, when vessels cross the growth plate and can seed infection from the adjacent metaphysis [18](#)
- In one study less than one third of patients with septic arthritis had any abnormality on radiographs with changes of osteomyelitis and septic arthritis sometimes taking up to 7-10 days to become apparent [20](#)
- After radiographs, hip ultrasound is the next appropriate investigation for possible septic arthritis. It is quick, free of ionising radiation and can evaluate for a hip joint effusion or soft tissue collection. It is, however, not specific and generally cannot distinguish between a transient synovitis or septic arthritis. Other aetiologies such as Perthes disease can also result in a hip joint effusion. A negative hip ultrasound does not exclude the presence of septic arthritis [22](#)
- With negative radiographs and ultrasound and continued suspicion of infection, bone scan and MRI are options. MRI has the advantage of no ionising radiation but, due to the fact many of these children are very young, often requires general anaesthesia or sedation. Bone scan involves ionising radiation but can often be performed without sedation. It is of limited value in distinguishing transient synovitis from septic arthritis [23](#)
- Whilst MRI cannot reliably distinguish between septic arthritis and transient synovitis, the findings of signal abnormality in the bone marrow and signal alterations and enhancement of surrounding soft tissue suggest the diagnosis of septic arthritis [24](#)

## Magnetic Resonance Imaging (MRI)

- The best investigation will depend on the age of the child. MRI is generally regarded as the investigation of choice but if the child is less than 6 and MRI will likely require GA, then bone scan may be more appropriate
- Using a combination of unenhanced and post gadolinium MRI sequences the diagnosis of Perthes' disease can be confidently made, even in the presence of normal or equivocal radiographs [2](#)
- Dynamic gadolinium enhanced subtraction MR also allows assessment of revascularisation patterns [7](#)
- MRI can distinguish Perthes' disease from other epiphyseal conditions such as Meyer's dysplasia and can find other causes of hip pain such as apophyseal injury or fracture [2](#)
- When the complication of progressive subluxation is suspected MRI can substitute for arthrography which usually requires general anaesthesia [4](#)
- Diffusion weighted imaging MRI may be a way of distinguishing between Perthes' disease

- with favourable and unfavourable prognosis [9](#)
- There is limited evidence for routine screening with MRI although cases of 'pre-slip' have been described that were only detectable with MRI
  - The earliest imaging finding, evident only on MRI, is focal widening of the physis, with or without synovitis, but without slippage of the femoral head (pre-slip) [15,17](#)
  - The MRI diagnosis of an early slipped capital femoral epiphysis relies on recognition of a morphologic change at the head/neck junction and abnormal signal intensity centred at the physis, indicative of oedema [10](#)
  - With negative radiographs and ultrasound and continued suspicion of infection, bone scan and MRI are options. MRI has the advantage of no ionising radiation but, due to the fact many of these children are very young, often requires general anaesthesia or sedation. Bone scan involves ionising radiation but can often be performed without sedation. It is of limited value in distinguishing transient synovitis from septic arthritis [23](#)
  - Whilst MRI cannot reliably distinguish between septic arthritis and transient synovitis, the findings of signal abnormality in the bone marrow and signal alterations and enhancement of surrounding soft tissue suggest the diagnosis of septic arthritis [24](#)

## Ultrasound

- After radiographs, hip ultrasound is the next appropriate investigation for possible septic arthritis. It is quick, free of ionising radiation and can evaluate for a hip joint effusion or soft tissue collection. It is, however, not specific and generally cannot distinguish between a transient synovitis or septic arthritis. Other aetiologies such as Perthes disease can also result in a hip joint effusion. A negative hip ultrasound does not exclude the presence of septic arthritis [22](#)

## Plain Radiographs

- AP pelvis and frog leg lateral radiographs are the initial investigation of choice with radiographs being the main imaging modality for both diagnosis and follow-up [4](#)
- Both hips are involved in approximately 15% of patients and it is therefore important to include both hips on radiographs [1,5](#)
- Changes of Perthes' disease can take 3-4 months to become apparent on radiographs [4](#)
- AP and frog leg or lateral radiographs are the first investigation of choice [12](#)
- Approximately 13% of slipped capital femoral epiphyses may not be visible on AP radiographs [13](#)

## Bone Scan

- In the past, pin hole scintigraphy (bone scan) was considered the gold standard for assessing prognosis as it could assess the degree and type of revascularisation [8](#)
- With negative radiographs and ultrasound and continued suspicion of infection, bone scan and MRI are options. MRI has the advantage of no ionising radiation but, due to the fact many of these children are very young, often requires general anaesthesia or sedation. Bone scan involves ionising radiation but can often be performed without sedation. It is of limited value in distinguishing transient synovitis from septic arthritis [23](#)

## References

References are graded from Level I to V according to the Oxford Centre for Evidence-Based Medicine, Levels of Evidence. [Download the document](#)

1. Barker DJ, Hall AJ. **The epidemiology of Perthes' disease.** Clin Orthop Relat Res 1986;209:89-94 (Review article)
2. Dillman JR, Hernandez RJ. **MRI of Legg-Calve-Perthes Disease.** AJR 009;193:1394-407 (Review article)
3. Mont MA, Jones LC, Hungerford DS. **Nontraumatic osteonecrosis of the femoral head: ten year later.** J Bone Joint Surg Am 2006;88:1117-32 (Review article)
4. Dimeglio A, Canavese F. **Imaging in Legg-Calve-Perthes disease.** Orthop Clin North Am 2011;42(3):297-302 (Review article)
5. Wiig O, Terjesen T, Svenningsson S, Lie S. **The epidemiology and aetiology of Perthes' disease in Norway.** J Bone Joint Surg Br 2006;88-B:1217-23 (Level III evidence)
6. Sebag G, Le Pointe HD, Klein I et al. **Dynamic gadolinium-enhanced subtraction MR imaging – a simple technique for the early diagnosis of Legg-Calve-Perthes disease: preliminary results.** Pediatr Radiol 1997;27:216-20 (Level IV evidence)
7. Lamer S, Dorgeret S, Khairouni A et al. **Femoral head vascularisation in Legg-Calve Perthes disease: comparison of dynamic gadolinium-enhanced subtraction MRI with bone scintigraphy.** Pediatr Radiol 2002;32(8):580-5 (Level III / IV evidence)
8. Conte F, De Rosa V, Zekri H et al. **Confirmation of the early prognostic value of one scanning and pinhole imaging of the hip in Legg-Calve-Perthes disease.** J Nucl Med 2003;44:1761-6 (Level III evidence)
9. Merlini L, Combescure C, De Rosa V, Anooshiravani M, Hanquinet S. **Diffusion-weighted imaging findings in Perthes disease with dynamic gadolinium-enhanced subtracted (DGS) MR correlation: a preliminary study.** Pediatr Radiol 2010;40:318-25 (Level III evidence)
10. Dwek JR. **The hip: MR imaging of uniquely pediatric disorders.** Magn Reson Imaging Clin N Am 2009;17:509-20 (Review article)
11. Kocher MS, Tucker R. **Pediatric athlete hip disorders.** Clin Sports Med 2006;25:241-53 (Review article)
12. Hubbard AM. **Imaging of pediatric hip disorders.** Radiol Clin North Am 2001;39(4):721-32 (Review article)
13. Cowell HR. **The significance of early diagnosis and treatment of slipping capital femoral epiphysis.** Clin Orthop 1966;48:89-94 (Review article)
14. Klein A, Joplin RJ, Reidy JA, Hanelin J. **Roentgenographic features of slipped capital femoral epiphysis.** AJR 1951;66:361-74
15. Uman H, Liebling MS, Moy L et al. **Slipped capital femoral epiphysis: a physeal lesion diagnosed by MRI, with radiographic and CT correlation.** Skeletal Radiol 1998;27(3):139-44 (Level III evidence)
16. Jerre R, Billing L, Hansson G, Karlsson J, Wallin J. **Bilaterality in slipped capital femoral epiphysis: importance of a reliable radiographic method.** J Pediatr Orthop B 1996;5(2):80-4 (Level III evidence)
17. Lalaji A, Umans H, Schneider R et al. **MRI features of confirmed pre-slip capital femoral epiphysis: a report of two cases.** Skeletal Radiol 2002;31:362-5 (Review article)
18. Shirley ML, Laxer RM. **Approach to acute limb pain in childhood.** Pediatr Rev 2006;27(5):170-9 (Review article)
19. Bayam L, Bruce CE, Sampath J, Bayam FB, Abernethy L. **Importance of communication between medical specialties: A case series.** Injury 2008;39:623-6 (Level IV evidence)
20. Al Saadi MM, Al Zamil FA, Bokhary NA et al. **Acute septic arthritis in children.** Ped Int



- 2009;51:377-80 (Level II/ III evidence)
21. Ferguson LP, Beattie TF. **Osteomyelitis in the well looking afebrile child.** BMJ 2002;324:1380-1 (Review article)
  22. Zamzam, MM. **The role of ultrasound in differentiating septic arthritis from transient synovitis of the hip in children.** J Pediatr Orthop B 2006;15:418-22 (Level III evidence)
  23. Connolly LP, Treves ST. **Assessing the limping child with skeletal scintigraphy.** J Nucl Med 1998;39:1056-61 (Review article)
  24. Yang WJ, Im SA, Lim GY et al. **MR imaging of transient synovitis: differentiation from septic arthritis.** Pediatr Radiol 2006;36:1154-8 (Level III evidence).

## Information for Consumers

Information from this website	Information from the Royal Australian and New Zealand College of Radiologists' website
<p><a href="#">Consent to Procedure or Treatment</a></p> <p><a href="#">Radiation Risks of X-rays and Scans</a></p> <p style="padding-left: 40px;"><a href="#">Bone Scan</a></p> <p><a href="#">Magnetic Resonance Imaging (MRI)</a></p> <p style="padding-left: 40px;"><a href="#">Ultrasound</a></p> <p style="padding-left: 40px;"><a href="#">Plain Radiography (X-ray)</a></p>	<p><a href="#">Magnetic Resonance Imaging (MRI)</a></p> <p style="padding-left: 40px;"><a href="#">Plain Radiography/X-rays</a></p> <p><a href="#">Radiation Risk of Medical Imaging for Adults and Children</a></p> <p style="padding-left: 40px;"><a href="#">Ultrasound</a></p> <p style="padding-left: 40px;"><a href="#">Nuclear Medicine</a></p> <p style="padding-left: 40px;"><a href="#">Nuclear Medicine Bone Scan</a></p> <p><a href="#">Making Your Child's Test or Procedure Less Stressful</a></p>

### Copyright

© Copyright 2015, Department of Health Western Australia. All Rights Reserved. This web site and its content has been prepared by The Department of Health, Western Australia. The information contained on this web site is protected by copyright.

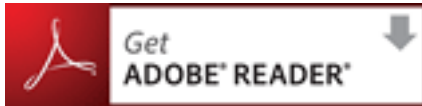### Legal Notice

Please remember that this leaflet is intended as general information only. It is not definitive and The Department of Health, Western Australia can not accept any legal liability arising from its use. The information is kept as up to date and accurate as possible, but please be warned that it is

always subject to change

## File Formats

Some documents for download on this website are in a Portable Document Format (PDF). To read these files you might need to download Adobe Acrobat Reader.



[Legal Matters](#)