

# Diagnostic Imaging Pathways - Paediatric, Limp

## Population Covered By The Guidance

This pathway provides guidance on imaging a child with a newly developed limp.

**Date reviewed: July 2014**

**Date of next review: 2017/2018**

**Published: July 2014**

## Quick User Guide

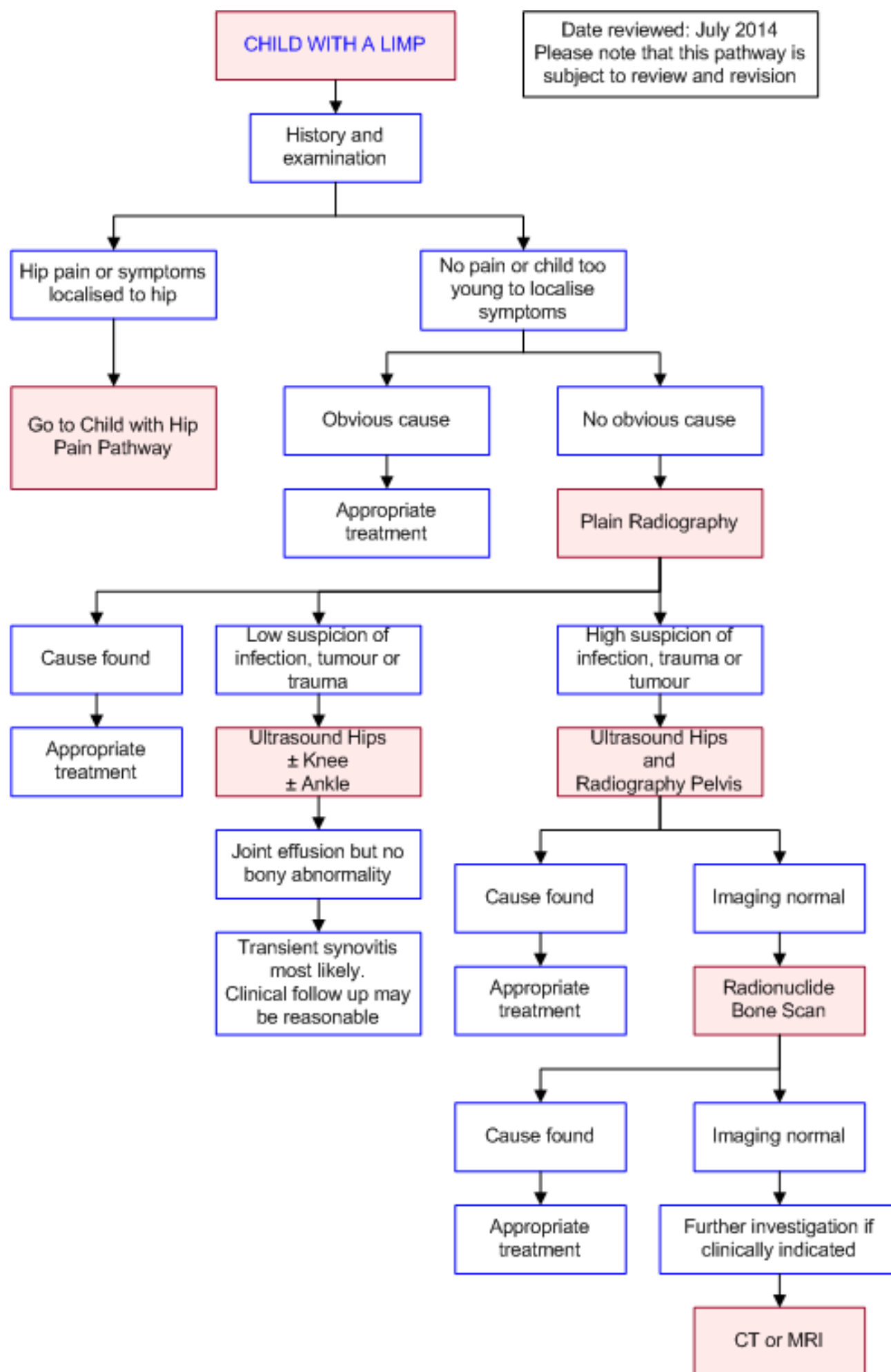
Move the mouse cursor over the **PINK** text boxes inside the flow chart to bring up a pop up box with salient points.

Clicking on the **PINK** text box will bring up the full text.

The relative radiation level (RRL) of each imaging investigation is displayed in the pop up box.

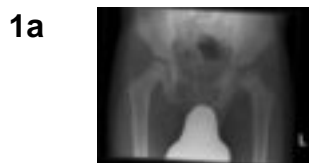SYMBOL	RRL	EFFECTIVE DOSE RANGE
	None	0
	Minimal	< 1 millisieverts
	Low	1-5 mSv
	Medium	5-10 mSv
	High	>10 mSv

## Pathway Diagram



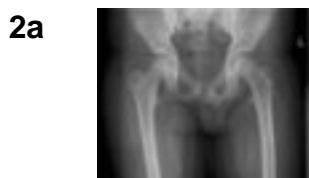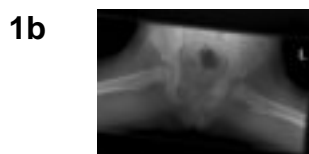## Image Gallery

*Note: These images open in a new page*



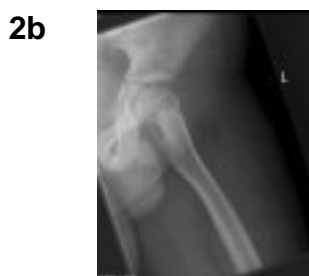### Perthes Disease

Image 1a and 1b (Plain Radiography): Frontal views in a neutral position and abduction with external rotation. The left hip shows marked fragmentation and resorption of bone and broadening of the femoral head and neck in keeping with advanced Perthes Disease.



### Slipped Capital Femoral Epiphysis (SCFE)

Image 2a and 2b (Plain Radiography): SCFE is demonstrated in the left hip.



## Teaching Points

- Depending on the age of the child and his/her ability to localize pain, as well as a thorough clinical history and examination, the choice of investigation is dictated by the most likely cause
  - Initially, plain films and ultrasonography are recommended
  - If further investigations are required, consideration should be given to a radionuclide scan, CT or MRI

## Radionuclide Bone Scan

- Is an excellent test for evaluating the limping child where the history and examination have failed to localise an area of abnormality [1](#)
- A bone scan was effective in localising an area of abnormality in 54% of limping children with normal initial x-rays [5](#)
- Has a high sensitivity and specificity for the detection of osteomyelitis [5,6,7](#)
- Particularly useful for identifying infections around the pelvis and spine [8](#)
- Limitations

- False negative scans with some tumours [8](#)
- The need for sedation in some children [2](#)
- Low sensitivity for septic arthritis [1](#)

## Computed Tomography (CT) and Magnetic Resonance Imaging (MRI)

- These imaging modalities have no role in the initial workup of children with a limp but may be useful in later investigation for suspected causes of limp
- Computed Tomography (CT)
  - Useful in selective clinical circumstances including imaging of suspected cortical abnormalities [1](#)
  - More widely available and less expensive than MRI but does involve exposure to radiation
- Magnetic Resonance Imaging (MRI)
  - Imaging modality of choice if symptoms are believed secondary to spinal pathology such as vertebral osteomyelitis [13](#)

## Ultrasound

- Is generally the preferred first line imaging modality for the investigation of hip symptoms in the young child (<8 years) in the absence of trauma [1](#)
- Is the preferred first line investigation when a patient presents with limp and is unable to localise symptoms, and for the diagnosis of transient synovitis [12](#)
- Advantages
  - Non-invasive
  - Requires no sedation
  - Widely available
  - Inexpensive
- Sensitive for detection of a hip joint effusion and if necessary can guide aspiration [9,10,11](#)

## Plain Radiography

- Usually the most appropriate initial imaging modality for the investigation of the limping child [1](#)
- In children who can localise a region of tenderness, radiographs should visualise the joint above and below the point of maximal tenderness [1](#)
- If the child is too young to localise pain options include imaging the entire lower extremity or radionuclide bone scan [1](#)
- Plain radiographs are frequently normal in the limping child [2,3](#)
- If clinical symptoms persist despite a normal initial xray, repeat radiography in 7-10 days may reveal an undisplaced fracture

## References

References are graded from Level I to V according to the Oxford Centre for Evidence-Based Medicine, Levels of Evidence. [Download the document](#)

- [1.](#) Flynn JM, Widmann RF. **The limping child: evaluation and diagnosis.** J Am Acad Orthop Surg.



- 2001;9:89-98. (Review article)
2. Englaro EE, Gelfand MJ, Paltiel HJ. **Bone scintigraphy in preschool children with lower extremity pain of unknown origin.** J Nucl Med. 1992;33:351-4. (Level IV evidence)
  3. Blatt SD, Rosenthal BM, Barnhart DC. **Diagnostic utility of lower extremity radiographs of young children with gait disturbance.** Pediatrics. 1991;87:138-40. (Level IV evidence)
  4. McConnochie KM, Roghmann KJ, Pasternack J, Monroe DJ, Monaco LP. **Prediction rules for selective radiographic assessment of extremity injuries in children and adolescents.** Pediatrics. 1990;86:45-57. (Level III evidence)
  5. Aronson J, Garvin K, Seibert J, Glasier C, Tursky EA. **Efficiency of the bone scan for occult limping toddlers.** J Pediatr Orthop. 1992;12:38-44. (Level III evidence)
  6. Myers MT, Thompson GH. **Imaging the child with a limp.** Pediatr Clin North Am. 1997;44:637-58. (Review article)
  7. Scott RJ, Christogersen MR, Robertson WW Jr, et al. **Acute osteomyelitis in children: a review of 116 cases.** J Pediatr Orthop. 1990;10:649-52. (Level III evidence)
  8. McCoy JR, Morrissy RT, Seibert J. **Clinical experience with the technetium-99 scan in children.** Clin Orthop. 1981;154:175-80. (Level III evidence)
  9. Royal SG. **Investigation of the irritable hip.** J Pediatr Orthop. 1992;12:396-7. (Level III evidence)
  10. Alexander JE, Seibert JJ, Glasier CM, et al. **High-resolution hip ultrasound in the limping child.** J Clin Ultrasound. 1989;17:19-24. (Level IV evidence)
  11. Zawin JK, Hoffer FA, Rand FF, Teele RL. **Joint effusion in children with an irritable hip: US diagnosis and aspiration.** Radiology. 1993;187:459-63. (Level II evidence). [View the reference](#)
  12. Terjesen T, Osthus P. **Ultrasound in the diagnosis and follow-up of transient synovitis of the hip.** J Pediatr Orthop. 1991;11:608-13. (Level III evidence)
  13. Fernandez M, Carrol CL, Baker CJ. **Discitis and vertebral osteomyelitis in children: an 18-year review.** Pediatrics. 2000;105:1299-304. (Level III evidence)

## Information for Consumers

Information from this website	Information from the Royal Australian and New Zealand College of Radiologists' website
<p><a href="#">Consent to Procedure or Treatment</a></p> <p><a href="#">Radiation Risks of X-rays and Scans</a></p> <p><a href="#">Bone Scan</a></p> <p><a href="#">Computed Tomography (CT)</a></p> <p><a href="#">Magnetic Resonance Imaging (MRI)</a></p> <p><a href="#">Ultrasound</a></p> <p><a href="#">Plain Radiography (X-ray)</a></p>	<p><a href="#">Computed Tomography (CT)</a></p> <p><a href="#">Magnetic Resonance Imaging (MRI)</a></p> <p><a href="#">Plain Radiography/X-rays</a></p> <p><a href="#">Radiation Risk of Medical Imaging for Adults and Children</a></p> <p><a href="#">Ultrasound</a></p> <p><a href="#">Nuclear Medicine</a></p> <p><a href="#">Nuclear Medicine Bone Scan</a></p>

[Making Your Child's Test or Procedure  
Less Stressful](#)

## Copyright

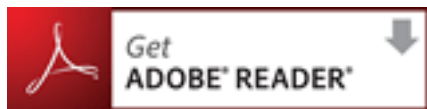
© Copyright 2015, Department of Health Western Australia. All Rights Reserved. This web site and its content has been prepared by The Department of Health, Western Australia. The information contained on this web site is protected by copyright.

## Legal Notice

Please remember that this leaflet is intended as general information only. It is not definitive and The Department of Health, Western Australia can not accept any legal liability arising from its use. The information is kept as up to date and accurate as possible, but please be warned that it is always subject to change

## File Formats

Some documents for download on this website are in a Portable Document Format (PDF). To read these files you might need to download Adobe Acrobat Reader.



## [Legal Matters](#)