

Diagnostic Imaging Pathways - Bleeding (First Trimester)

Population Covered By The Guidance

This pathway provides guidance on the imaging of pregnant patients with unexplained first trimester bleeding.

Date reviewed: October 2013

Date of next review: 2017/2018

Published: November 2013

Quick User Guide

Move the mouse cursor over the **PINK** text boxes inside the flow chart to bring up a pop up box with salient points.

Clicking on the **PINK** text box will bring up the full text.

The relative radiation level (RRL) of each imaging investigation is displayed in the pop up box.

SYMBOL	RRL	EFFECTIVE DOSE RANGE
	None	0
	Minimal	< 1 millisieverts
	Low	1-5 mSv
	Medium	5-10 mSv
	High	>10 mSv

Pathway Diagram

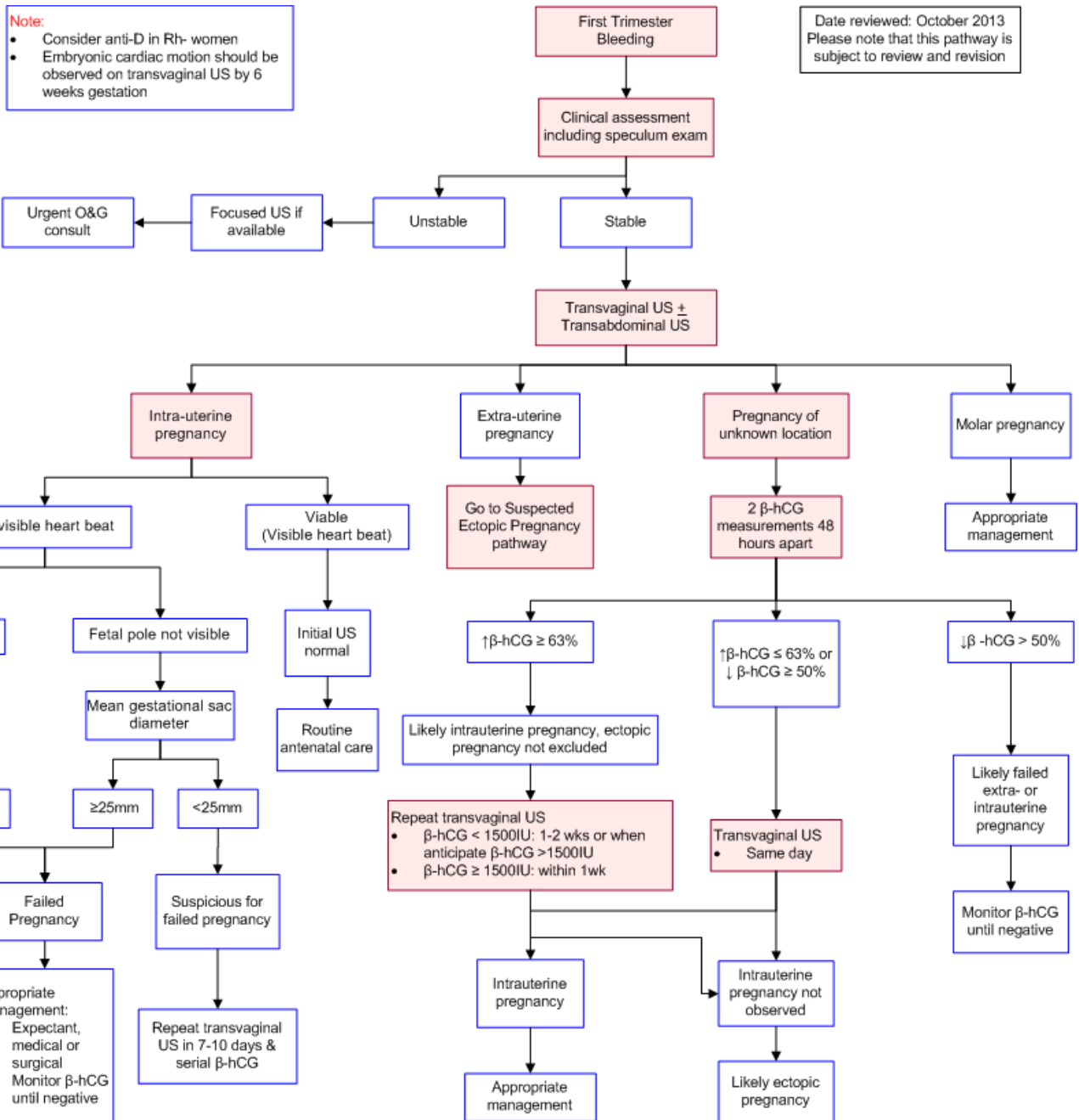
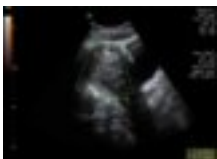

Image Gallery

Note: These images open in a new page

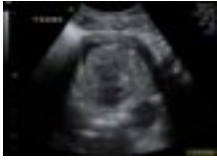1a



Failed Pregnancy

Image 1a and 1b (Ultrasound): This scan shows an anteverted uterus measuring 102 mm in axial length. Within the uterine cavity is echogenic material measuring 67 x 35 x 50 mm. A small amount of fluid is seen superior to this. The appearance is consistent with retained products of conception.

1b



Teaching Points

- Major causes of first trimester bleeding are
 - Ectopic pregnancy
 - Threatened or impending miscarriage
 - Uterine, cervical or vaginal pathology; e.g. infection
 - Physiological; e.g. implantation bleeding
- The first step in establishing a cause of bleeding is to obtain a detailed history and perform a physical and speculum examination
- Transvaginal US is more sensitive than trans-abdominal US and can detect a viable gestation earlier in pregnancy
- Depending on the findings at ultrasonography, further biochemical investigations and medical or surgical interventions may be necessary

Causes of First Trimester Bleeding

- Causes of bleeding in early pregnancy include
 - Ectopic pregnancy
 - Threatened or impending miscarriage
 - Cervical, vaginal or uterine pathology; e.g. infection
 - Physiological e.g. bleeding due to implantation of the pregnancy (typically 10-14 days after fertilisation), cervical ectropion
- Ultrasound in the first trimester is not routinely recommended but is often performed for the following indications [3-7](#)
 - Assessment of gestational age and sac
 - Detection of early pregnancy failure
 - Assessment of fetal number
 - Early detection of major fetal abnormalities
 - Nuchal translucency
 - Assessment of ovaries, uterus and adnexa
 - Exclusion or confirmation of ectopic pregnancy
 - Patients with a previous ectopic pregnancy

Transvaginal Ultrasonography

- More sensitive than transabdominal ultrasonography and allows earlier gestational sac visualisation and earlier diagnoses of viable intrauterine or ectopic pregnancies [14](#)
- Superior to transabdominal US in visualising fetal anatomy and detecting fetal structural and chromosomal abnormalities [12,15](#)
- In intrauterine pregnancy of uncertain viability, cut-off transvaginal US measurements for the diagnosis of early pregnancy demise must be highly specific with a low false-positive rate (FPR) to

avoid harmful misdiagnosis. A cut-off of CRL ≥ 7 mm and MSD ≥ 25 mm is based on recommendations from a multicentre observational study and systematic review [16,17](#) and is included in the Society of Radiologists in Ultrasound, Australian Society for Ultrasound in Medicine and the National Institute for Health and Clinical Excellence and the Royal College of Obstetricians and Gynaecologists clinical guidelines [1,5,18](#)

- At 6-9 weeks gestation, CRL has less interobserver variability than MSD on transvaginal US [19](#)
- Visualisation of embryonic cardiac activity confirming live intrauterine pregnancy is generally visible transvaginally by 46 days menstrual age [2](#)
- Ultrasonography is less accurate in the presence of bleeding [20](#)
- Patients with indeterminate ultrasonography findings require further evaluation with follow-up transvaginal ultrasound and/or serial quantitative β -hCG levels as about 10-20% of these patients may have a final diagnosis of ectopic pregnancy [21-23](#)

Transabdominal Ultrasonography

- Useful screening test for early pregnancy complications such as threatened abortion, ectopic pregnancy, blighted ovum and trophoblastic disease [8,9](#)
- Correlation of sonographic findings with simultaneous maternal serum human chorionic gonadotropin (β -HCG) levels is useful in evaluation of early pregnancy complications, particularly when a living embryo is not visualised [9,10](#)
- Allows identification of an intrauterine pregnancy, which is the single most important finding for the exclusion of ectopic gestation as the presence of both intra- and extra-uterine pregnancy is very rare [9](#)
- Enables examination of early fetal anatomy and measurement of nuchal translucency, thus allowing screening of a majority of fetal structural and chromosomal abnormalities in early pregnancy [11,12](#)
- Allows assessment of the outcome of early first-trimester pregnancies with slow embryonic heart rates (embryonic HR <70 bpm is associated with fetal demise in 100% of patients; and if the embryonic HR is <90 bpm in the first trimester, close follow-up of the pregnancy is recommended) [13](#)
- Follow-up second trimester US is still required to detect significant abnormalities missed on first trimester US and for placental localisation [11](#)

Serum Human Chorionic Gonadotrophin (β -hCG) Levels in Pregnancy of Unknown Location

- β -hCG levels must be interpreted together with the clinical picture and US findings, and should not be used solely to determine the pregnancy location and determine management. β -hCG levels can overlap between viable and nonviable intrauterine pregnancy and ectopic pregnancy and are affected by multiple gestation [1,18,24,25](#)
- Serum β -hCG ratios from serial β -hCGs (e.g. β -hCG at 48hrs compared to 0 hrs) perform better compared to single β -hCG levels in dictating appropriate management alongside imaging and clinical findings [26](#)
- The level of evidence is low and heterogenous. At present, timing of diagnostic testing is consensus based. [1](#) The pathway is adapted from the National Institute for Health and Clinical Excellence and Royal College of Obstetricians and Gynaecologists clinical guideline. [1](#) Further research of higher quality is needed
- A β -hCG rise $>63\%$ in 48 hours has 87% sensitivity, 98% specificity, 90% positive predictive value and 97% negative predictive value for diagnosis of viable intrauterine pregnancy, with a positive

- and negative likelihood ratio of 42.8 and 0.13 respectively [27](#)
- Serum β -hCG levels double approximately every 48 hours in 85% of normal intrauterine pregnancies of between 4 and 6 weeks' gestation [28](#)
 - The slowest reported rise over 48 hours associated with a viable intrauterine pregnancy is 53% [29](#)
 - 80% of ectopic pregnancies are associated with a rise in β -hCG of < 66% [22,28](#)

References

Date of literature search: June 2013

The search methodology is available on request. [Email](#)

References are graded from Level I to V according to the Oxford Centre for Evidence-Based Medicine, Levels of Evidence. [Download the document](#)

1. National Collaborating Centre for Women's and Children's Health, National Institute for Health and Clinical Excellence. **NICE clinical guideline 154: Ectopic pregnancy and miscarriage: Diagnosis and initial management in early pregnancy of ectopic pregnancy and miscarriage.** London: Royal College of Obstetricians and Gynaecologists; 2012 [updated 2012 December; cited 2013 July 1]. (Evidence based guideline). [View the reference](#)
2. Rempen A. **Diagnosis of viability in early pregnancy with vaginal sonography.** J Ultrasound Med. 1990;9(12):711-6. (Level II evidence)
3. Ewigman B, Lefevre M, Hesser J. **A randomized trial of routine prenatal ultrasound.** Obstet Gynecol. 1990;76(2):189-94. (Level II evidence)
4. Sohaey R, Woodward P, Zwiebel WJ. **First-trimester ultrasound: the essentials.** Semin Ultrasound CT MR. 1996;17(1):2-14. (Review article)
5. Australasian Society for Ultrasound in Medicine. **Guidelines for the performance of first trimester ultrasound.** ASUM guidelines; 2005 July [updated 2012 August]. (Evidence based guidelines)
6. Snijders R. **First-trimester ultrasound.** Clin Perinatol. 2001;28(2):333-52,viii. (Review article)
7. Bucher HC, Schmidt JG. **Does routine ultrasound scanning improve outcome in pregnancy? Meta-analysis of various outcome measures.** BMJ. 1993;3;307(6895):13-7. (Level I evidence)
8. Wong TW, Lau CC, Yeung A, Lo L, Tai CM. **Efficacy of transabdominal ultrasound examination in the diagnosis of early pregnancy complications in an emergency department.** J Accid Emerg Med. 1998;15(3):155-8. (Level II evidence)
9. Braffman BH, Coleman BG, Ramchandani P, Arger PH, Nodine CF, Dinsmore BJ, et al. **Emergency Department screening for ectopic pregnancy - A prospective US study.** Radiology. 1994;190(3):797-802. (Level II evidence)
10. Nyberg DA, Mack LA, Laing FC, Jeffrey RB. **Early-pregnancy complications - endovaginal sonographic findings correlated with human chorionic-gonadotropin levels.** Radiology. 1988;167(3):619-22. (Level III evidence)
11. Whitlow BJ, Chatzipapas IK, Lazanakis ML, Kadir RA, Economides DL. **The value of sonography in early pregnancy for the detection of fetal abnormalities in an unselected population.** Br J Obstet Gynaecol. 1999;106(9):929-36. (Level II evidence)
12. Braithwaite JM, Armstrong MA, Economides DL. **Assessment of fetal anatomy at 12 to 13 weeks of gestation by transabdominal and transvaginal sonography.** Br J Obstet Gynaecol. 1996;103(1):82-5. (Level II evidence)
13. Benson CB, Doubilet PM. **Slow embryonic heart rate in early first trimester: indicator of poor pregnancy outcome.** Radiology. 1994;192(2):343-4. (Level III evidence)
14. Pennell RG, Needleman L, Pajak T, Baltarowich O, Vilaro M, Goldberg BB, et al. **Prospective**



- comparison of vaginal and abdominal sonography in normal early pregnancy.** J Ultrasound Med. 1991;10(2):63-7. (Level II evidence)
15. Economides DL, Whitlow BJ, Kadir R, Lazanakis M, Verdin SM. **First trimester sonographic detection of chromosomal abnormalities in an unselected population.** Br J Obstet Gynaecol. 1998;105(1):58-62. (Level II evidence)
16. Abdallah Y, Daemen A, Kirk E, Pexsters A, Najji O, Stalder C, et al. **Limitations of current definitions of miscarriage using mean gestational sac diameter and crown-rump length measurements: a multicenter observational study.** Ultrasound Obstet Gynecol. 2011;38(5):497-502. (Level II evidence)
17. Jeve Y, Rana R, Bhide A, Thangaratnam S. **Accuracy of first-trimester ultrasound in the diagnosis of early embryonic demise: a systematic review.** Ultrasound Obstet Gynecol. 2011;38(5):489-96. (Level II evidence)
18. Doubilet PM, Benson CB, Bourne T, Blaivas M. **Diagnostic criteria for nonviable pregnancy early in the first trimester.** N Engl J Med. 2013;369(15):1443-51. (Evidence based guidelines)
19. Pexsters A, Luts J, Van Schoubroeck D, Bottomley C, Van Calster B, Van Huffel S, et al. **Clinical implications of intra- and interobserver reproducibility of transvaginal sonographic measurement of gestational sac and crown-rump length at 6–9 weeks' gestation.** Ultrasound Obstet Gynecol. 2011;38(5):510-15. (Level II/III evidence)
20. Barnhart KT, Fay CA, Suescum M, Sammel MD, Appleby D, Shaunik A, et al. **Clinical factors affecting the accuracy of ultrasonography in symptomatic first-trimester pregnancy.** Obstet Gynecol. 2011;117(2 Pt 1):299-306. (Level II evidence)
21. Dart R, Burke G, Dart L. **Subclassification of indeterminate pelvic ultrasonography: prospective evaluation of the risk of ectopic pregnancy.** Ann Emerg Med. 2002;39(4):382-8. (Level II evidence)
22. Dart RG, Mitterando J, Dart LM. **Rate of change of serial beta-human chorionic gonadotropin values as a predictor of ectopic pregnancy in patients with indeterminate transvaginal ultrasound findings.** Ann Emerg Med. 1999;34(6):703-10. (Level III evidence)
23. Juliano ML, Sauter BM. **Fetal outcomes in first trimester pregnancies with an indeterminate ultrasound.** J Emerg Med. 2012;43(3):417-22. (Level II evidence)
24. Mehta TS, Levine D, Beckwith B. **Treatment of ectopic pregnancy: is a human chorionic gonadotropin level of 2,000 mIU/mL a reasonable threshold?** Radiology. 1997;205(2):569-73. (Level III evidence)
25. Kadar N, Bohrer M, Kemmann E, Shelden R. **The discriminatory human chorionic gonadotropin zone for endovaginal sonography: a prospective, randomized study.** Fertil Steril. 1994;61(6):1016-20. (Level II evidence)
26. van Mello NM, Mol F, Opmeer BC, Ankum WM, Barnhart K, Coomarasamy A, et al. **Diagnostic value of serum hCG on the outcome of pregnancy of unknown location: a systematic review and meta-analysis.** Hum Reprod Update. 2012;18(6):603-17. (Level II evidence)
27. Daus K, Mundy D, Graves W, Slade BA. **Ectopic pregnancy: what to do during the 20-day window.** J Reprod Med. 1989;34(2):162-6. (Level III evidence)
28. Symonds IM. **Ectopic pregnancy: modern management.** Cur Obs Gynaecol. 1998;8(1):27-31. (Review article)
29. Barnhart KT, Sammel MD, Rinaudo PF, Zhou L, Hummel AC, Guo W. **Symptomatic patients with an early viable intrauterine pregnancy: HCG curves redefined.** Obstet Gynecol. 2004;104(1):50-5. (Level III evidence)

Information for Consumers

Information from this website

Information from the Royal
Australian and New Zealand

	College of Radiologists' website
Consent to Procedure or Treatment Radiation Risks of X-rays and Scans Ultrasound	Radiation Risk of Medical Imaging During Pregnancy Radiation Risk of Medical Imaging for Adults and Children Ultrasound Transvaginal Ultrasound

Copyright

© Copyright 2015, Department of Health Western Australia. All Rights Reserved. This web site and its content has been prepared by The Department of Health, Western Australia. The information contained on this web site is protected by copyright.

Legal Notice

Please remember that this leaflet is intended as general information only. It is not definitive and The Department of Health, Western Australia can not accept any legal liability arising from its use. The information is kept as up to date and accurate as possible, but please be warned that it is always subject to change

File Formats

Some documents for download on this website are in a Portable Document Format (PDF). To read these files you might need to download Adobe Acrobat Reader.

