

# Diagnostic Imaging Pathways - Endometriosis (Suspected)

## Population Covered By The Guidance

This pathway provides guidance on the investigation of adult patients with suspected endometriosis.

**Date reviewed: August 2014**

**Date of next review: 2017/2018**






**Published: December 2014**

## Quick User Guide

Move the mouse cursor over the **PINK** text boxes inside the flow chart to bring up a pop up box with salient points.

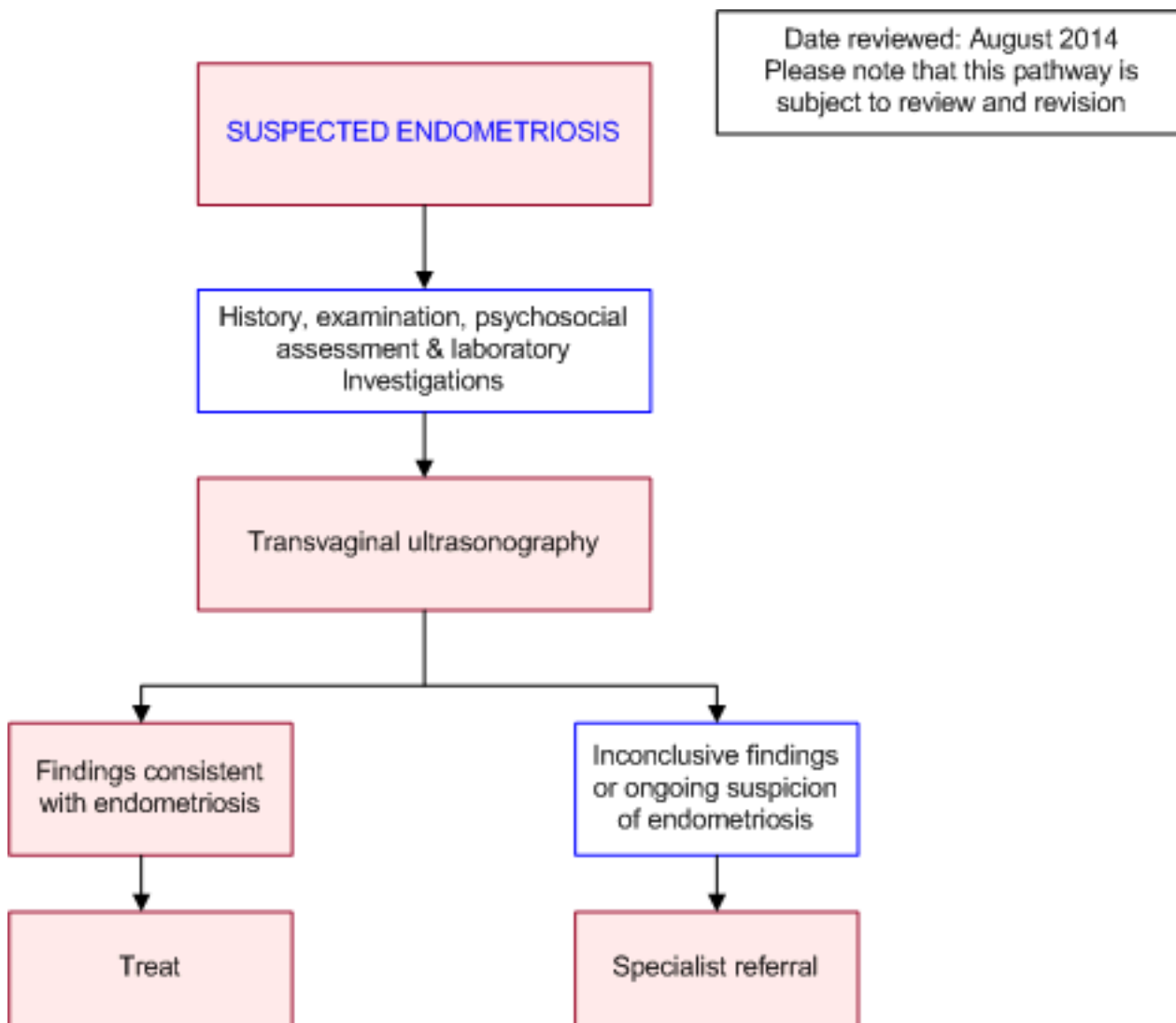
Clicking on the **PINK** text box will bring up the full text.

The relative radiation level (RRL) of each imaging investigation is displayed in the pop up box.

SYMBOL	RRL	EFFECTIVE DOSE RANGE
	None	0
	Minimal	< 1 millisieverts
	Low	1-5 mSv
	Medium	5-10 mSv
	High	>10 mSv

## Pathway Diagram

Date reviewed: August 2014  
Please note that this pathway is  
subject to review and revision



## Image Gallery

Coming Soon

## Teaching Points

- Transvaginal Ultrasonography should be the initial choice of imaging investigation in the assessment of endometriosis
- Where inconclusive specialist gynaecological opinion should be sought early where the decision for use of more specialised imaging modalities like MRI and specialised ultrasonography can be made
- Rarely diagnostic laparoscopy can be used to aid in assisting the diagnosis of endometriosis

## Endometriosis

- Endometriosis is defined as endometrial like tissue outside of the uterus. The presence of this tissue initiates a chronic inflammatory reaction, subsequent scar tissue and adhesions [1](#)
- There are three types of endometriotic lesions delineated in the literature specifically: superficial endometriosis, ovarian endometriomas and deeply infiltrating endometriosis (DIE) [2](#)

- The primary symptoms associated with endometriosis are pelvic pain, dysmenorrhea and dyspareunia [3](#)
- From an epidemiological perspective it is estimated that 6-10 percent of the general female population experience endometriosis [4](#)
- There exists a growing body of evidence [5-7](#) linking endometriosis with the development of certain types of ovarian cancer
- The precise pathogenesis of endometriosis is unknown, current theories include altered immunity, coelomic metaplasia, retrograde metaplasia and coelomic metaplasia [8](#)
- DIE is a form of endometriosis where endometrial tissue, fibrosis and muscular hyperplasia is found under the peritoneum. It involves structures like the bowel, ureters, rectovaginal space and bladder. [9](#) DIE refers to histological identification of endometriotic lesions that penetrate more than 5mm under the peritoneum. In descending order of frequency DIE involves the uterosacral ligaments, rectosigmoid colon, the vagina and the bladder [10](#)

## Transvaginal Ultrasonography

- The use of Transvaginal Ultrasonography (TVS) is well accepted as a first line investigation for endometriosis
- The gold standard for diagnosis of endometriosis remains laparoscopy [11](#)
- TVS has varying performance in regards to the diagnosis of geographically distinct locations of Deep Infiltrating Endometriosis
- TVS has excellent diagnostic capacity in the diagnosis of DIE involving the rectosigmoid with the results from a meta-analysis revealing pooled sensitivity, specificity, LR+ and LR- of 0.91, 0.98, 30.36 and 0.09 respectively [11](#)
- Similarly TVS has established efficacy in the diagnosis of ovarian endometriata with a systematic review demonstrating LR+ ratios ranging from 7.6-29.8 and LR- ratios ranging from 0.1-0.4
- There exists in the literature the use of Transrectal Ultrasonography (TRUS) in the detection of DIE. When compared to TVUS the results are similar [2](#) with other studies showing the superiority of TVUS in detecting DIE in certain locations. [10](#) Both are adept in the detection of DIE however given cost and patient tolerance factors TVUS should be preferred over TRUS
- Information for consumers on Transvaginal Ultrasonography [InsideRadiology](#)

## Treatment

- In a recently published review [12](#) of existing systematic reviews on the Cochrane database the following assessments were made in regards to interventions in the treatment of endometriosis
- Low quality evidence benefit for GnRH analogues over placebo or no treatment in regards to pain relief
- Moderate quality evidence for the use of levonorgestrel- release intrauterine system (LNG-IUD) over expectant management, very low quality evidence for beneficial effect of danazol when compared to placebo
- Inconclusive evidence of benefit for the use of NSAIDs in the treatment of pain
- Moderate quality evidence in regards to pain relief for laparoscopic surgery compared to diagnostic laparoscopy only
- Moderate quality evidence for better live birth and ongoing pregnancy rates after laparoscopic surgery compared to diagnostic laparoscopy

## Specialist Referral

- Specialist gynaecological opinion should be sought if initial imaging investigations are inconclusive
- The decision to use more detailed investigations like MRI and specialised ultrasonography to investigate for endometriosis can then be made. In rare instances diagnostic laparoscopy may be considered in the assessment of endometriosis
- MRI is an accepted modality in the investigation of endometriosis and is a useful adjunct to US with a primary advantage being the ability to acquire imaging of the anterior and posterior compartments of the pelvis simultaneously
- An overview of studies using 1.5T MRI to detect DIE revealed a range of sensitivity ranging from 0.73 [13](#) to 0.90 [14](#) employing the use of 3.0T MRI increased diagnostic accuracy with sensitivity and specificity of 0.96 and 1.00 respectively [15](#)
- In the literature, studies have detailed the superiority of MRI and its ability to detect uterosacral and vaginal endometriosis when compared to Rectal Endoscopic Sonography and TVUS [16,17](#)
- Information for consumers on MRI [InsideRadiology](#)

## References

Date of literature search: April 2014

The search methodology is available on request. [Email](#)

References are graded from Level I to V according to the Oxford Centre for Evidence-Based Medicine, Levels of Evidence. [Download the document](#)

- [1.](#) Kennedy S, Bergqvist A, Chapron C, D'Hooghe T, Dunselman G, Greb R, et al. **ESHRE guideline for the diagnosis and treatment of endometriosis.** Hum Reprod. 2005;20(10):2698-704. (Evidence based guideline). [View the reference](#)
- [2.](#) Piketty M, Chopin N, Dousset B, Millischer-Bellaische AE, Roseau G, Leconte M, et al. **Preoperative work-up for patients with deeply infiltrating endometriosis: transvaginal ultrasonography must definitely be the first-line imaging examination.** Hum Reprod. 2009;24(3):602-7. (Level I evidence). [View the reference](#)
- [3.](#) Rock JA, Markham SM. **Pathogenesis of endometriosis.** Lancet. 1992;340(8830):1264-7. (Review article). [View the reference](#)
- [4.](#) Giudice LC, Kao LC. **Endometriosis.** Lancet. 2004;364(9447):1789-99. (Review article). [View the reference](#)
- [5.](#) Pearce CL, Templeman C, Rossing MA, Lee A, Near AM, Webb PM, et al. **Association between endometriosis and risk of histological subtypes of ovarian cancer: a pooled analysis of case-control studies.** Lancet Oncol. 2012;13(4):385-94. (Level III evidence). [View the reference](#)
- [6.](#) Heidemann LN, Hartwell D, Heidemann CH, Jochumsen KM. **The relation between endometriosis and ovarian cancer - a review.** Acta Obstet Gynecol Scand. 2014;93(1):20-31. (Level II/III evidence). [View the reference](#)
- [7.](#) Van Gorp T, Amant F, Neven P, Vergote I, Moerman P. **Endometriosis and the development of malignant tumours of the pelvis. A review of literature.** Best Pract Res Clin Obstet Gynaecol. 2004;18(2):349-71. (Review article). [View the reference](#)
- [8.](#) Macer ML, Taylor HS. **Endometriosis and infertility: a review of the pathogenesis and treatment of endometriosis-associated infertility.** Obstet Gynecol Clin North Am. 2012;39(4):535-49. (Review article). [View the reference](#)
- [9.](#) Bianek-Bodzak A, Szurowska E, Sawicki S, Liro M. **The importance and perspective of magnetic resonance imaging in the evaluation of endometriosis.** Biomed Res Int.



- 2013;2013:436589. (Review article). [View the reference](#)
10. Bazot M, Malzy P, Cortez A, Roseau G, Amouyal P, Darai E. **Accuracy of transvaginal sonography and rectal endoscopic sonography in the diagnosis of deep infiltrating endometriosis.** Ultrasound Obstet Gynecol. 2007;30(7):994-1001. (Level II evidence). [View the reference](#)
  11. Hudelist G, English J, Thomas A, Tinelli A, Singer C, Keckstein J. **Diagnostic accuracy of transvaginal ultrasound for non invasive diagnosis of bowel endometriosis: systematic review and meta analysis.** Ultrasound Obstet Gynaecol. 2011;37(3):257-63. (Level I evidence). [View the reference](#)
  12. Brown J, Farquhar C. **Endometriosis: an overview of Cochrane Reviews.** Cochrane Database Syst Rev. 2014;3:CD009590. (Level I evidence).
  13. Roy C, Balzan C, Thoma V, Sauer B, Wattiez A, Leroy J. **Efficiency of MR imaging to orientate surgical treatment of posterior deep pelvic endometriosis.** Abdom Imaging. 2009;34(2):251-9. (Level II evidence). [View the reference](#)
  14. Azot M, Darai E, Hourani R, Thomassin I, Cortez A, Uzan S, et al. **Deep pelvic endometriosis: MR imaging for diagnosis and prediction of extension of disease.** Radiology. 2004;232(2):379-89. (Level I evidence). [View the reference](#)
  15. Hottat N, Larrousse C, Anaf V, Noel JC, Matos C, Absil J, et al. **Endometriosis: contribution of 3.0-T pelvic MR imaging in preoperative assessment--initial results.** Radiology. 2009;253(1):126-34. (Level II evidence). [View the reference](#)
  16. Bazot M, Bornier C, Dubernard G, Roseau G, Cortez A, Darai E. **Accuracy of magnetic resonance imaging and rectal endoscopic sonography for the prediction of location of deep pelvic endometriosis.** Hum Reprod. 2007;22(5):1457-63. (Level II evidence). [View the reference](#)
  17. Bazot M, Lafont C, Rouzier R, Roseau G, Thomassin-Naggara I, Darai E. **Diagnostic accuracy of physical examination, transvaginal sonography, rectal endoscopic sonography, and magnetic resonance imaging to diagnose deep infiltrating endometriosis.** Fertil Steril. 2009;92(6):1825-33. (Level II evidence). [View the reference](#)

## Information for Consumers

Information from this website	Information from the Royal Australian and New Zealand College of Radiologists' website
<p><a href="#">Consent to Procedure or Treatment</a></p> <p><a href="#">Radiation Risks of X-rays and Scans</a></p> <p><a href="#">Magnetic Resonance Imaging (MRI)</a></p> <p><a href="#">Ultrasound</a></p>	<p><a href="#">Magnetic Resonance Imaging (MRI)</a></p> <p><a href="#">Radiation Risk of Medical Imaging During Pregnancy</a></p> <p><a href="#">Radiation Risk of Medical Imaging for Adults and Children</a></p> <p><a href="#">Ultrasound</a></p> <p><a href="#">Transvaginal Ultrasound</a></p>

## Copyright


© Copyright 2015, Department of Health Western Australia. All Rights Reserved. This web site and its content has been prepared by The Department of Health, Western Australia. The information contained on this web site is protected by copyright.

## Legal Notice

Please remember that this leaflet is intended as general information only. It is not definitive and The Department of Health, Western Australia can not accept any legal liability arising from its use. The information is kept as up to date and accurate as possible, but please be warned that it is always subject to change

## File Formats

Some documents for download on this website are in a Portable Document Format (PDF). To read these files you might need to download Adobe Acrobat Reader.



[Legal Matters](#)