

# Diagnostic Imaging Pathways - Paediatric, Hydronephrosis (Antenatal)

## Population Covered By The Guidance

This pathway provides guidance for imaging newborn and paediatric patients with antenatally detected hydronephrosis.

**Date reviewed: February 2017**

**Date of next review: February 2020**






**Published: July 2017**

## Quick User Guide

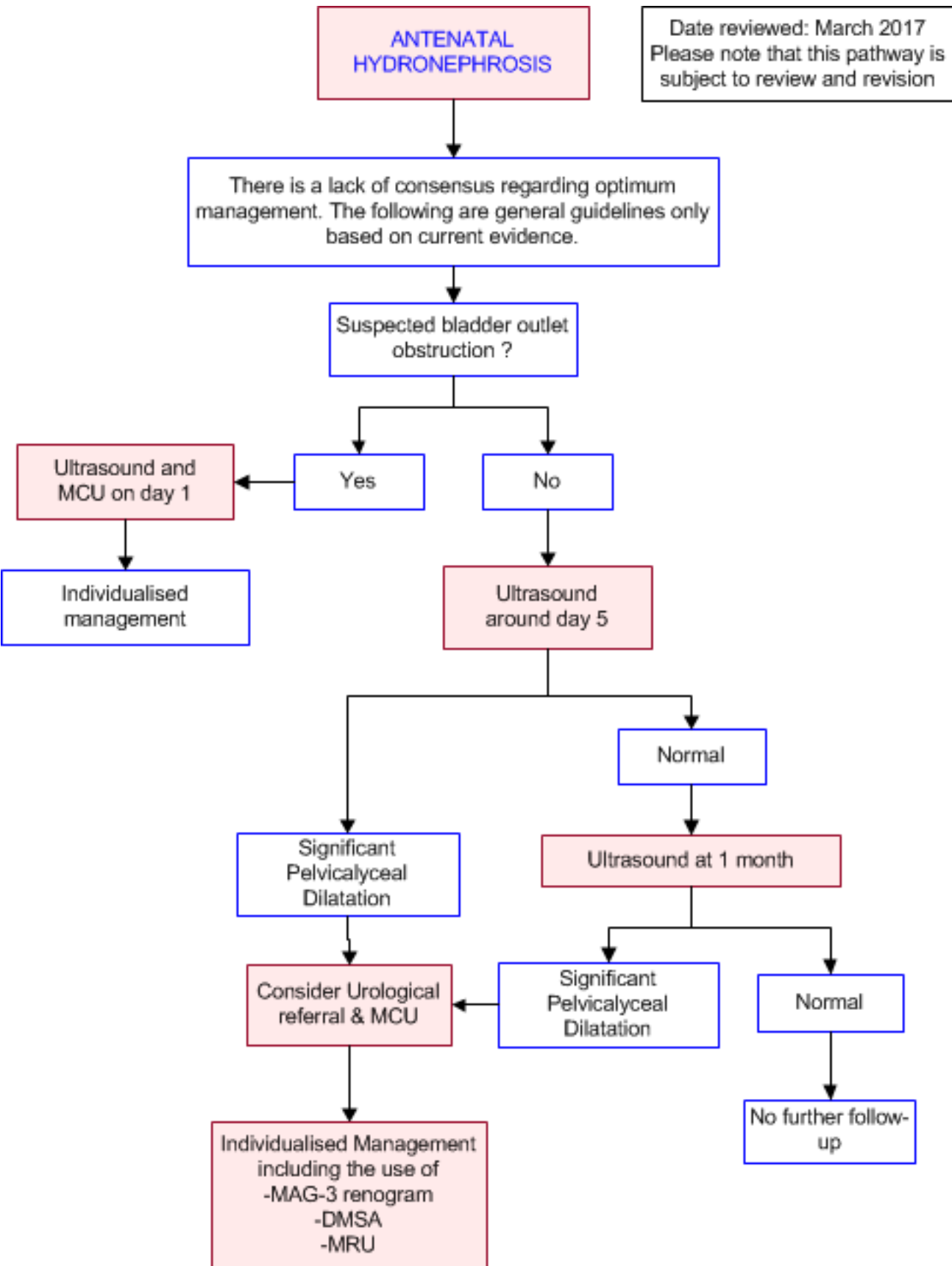
Move the mouse cursor over the **PINK** text boxes inside the flow chart to bring up a pop up box with salient points.

Clicking on the **PINK** text box will bring up the full text.

The relative radiation level (RRL) of each imaging investigation is displayed in the pop up box.

SYMBOL	RRL	EFFECTIVE DOSE RANGE
	None	0
	Minimal	< 1 millisieverts
	Low	1-5 mSv
	Medium	5-10 mSv
	High	>10 mSv

## Pathway Diagram



## Image Gallery

*Note: Images coming soon*

## Teaching Points

- Antenatal hydronephrosis affect 1-5% of pregnancies.
- The post-natal investigation and management of hydronephrosis is controversial as this finding does not necessarily imply obstruction and many will resolve spontaneously.
- Ultrasound should be performed at 5-10 days after birth and repeated at 4 weeks if normal. This offers a safe and non-invasive method to monitor renal tract abnormalities.
- Moderate and severe hydronephrosis on ultrasound scans shows be followed-up with a micturating cystourethrogram (MCU) to exclude vesicoureteric reflux which occurs in up to 38% of cases.
- MAG-3 renograms are used to identify assess obstruction which is mostly due to pelviureteric junction (PUJ) obstruction.
- An Individualised approach is suggested for the use of MAG-3 renogram, Technetium-99m Dimercaptosuccinic Acid (DMSA) Scan and/or Magnetic Resonance Urography.

## Antenatal Hydronephrosis

- With the introduction of routine ultrasound in pregnancy, antenatal hydronephrosis is being increasingly detected and is currently found in 1-5% of pregnancies. [1, 2](#) However, this finding does not necessarily imply obstruction or impaired renal function and most cases improve spontaneously. Therefore, this is a controversial area in paediatrics and there is a lack of consensus on optimum management. The following are general guidelines only based on best available evidence
- Antenatal hydronephrosis is defined as a renal pelvis anteroposterior diameter of >4mm less than 33 weeks gestation and >7mm less than 40 weeks on ultrasound [3-5](#)
- The most widely accepted grading system for hydronephrosis is the Society of Foetal Urology hydronephrosis (SFU) system, although experts have proposed the Urinary Tract Dilation (UTD) classification as a replacement [2, 6-8](#)
- Since further evaluation is needed to establish the clinical accuracy and utility of the UTD classification, The SFU system is listed below

<b>Grade 0</b>	No or minimal collecting system visible - considered normal
<b>Grade I</b>	Just the renal pelvis visible with an axial diameter <5-7 mm - usually considered normal
<b>Grade II</b>	Axial renal pelvis diameter 5/7-10 mm; some calices with normal forniceal shape visible
<b>Grade III</b>	Marked dilatation of the renal calices and pelvis >10 mm with reduced forniceal and papillary differentiation without parenchymal narrowing
<b>Grade IV</b>	Gross dilatation of the collecting system with narrowing of the parenchyma



- The risk of postnatal pathology is 12% for mild, 45% for moderate and 88% for severe antenatal hydronephrosis.(1) Overall, only a minority of neonates will require surgical intervention. [5, 9](#) Mild hydronephrosis is more likely to stabilise or improve compared to higher grades [5, 10](#)
- Common causes of antenatal hydronephrosis include pelviureteric junction (PUJ) obstruction, vesicoureteric reflux (VUR), posterior urethral valves, duplication anomalies (ureterocoele/ectopic ureter), megaureter and multicystic dysplastic kidney [5](#)

## Ultrasound

- Ultrasound is a safe and non-invasive method to monitor the structure of the urinary tract including renal size and morphology, pelvicalyceal and ureteric dilatation, ureterocoeles and bladder wall thickness
- In addition to hydronephrosis, associated findings which should also be documented include the volume of amniotic fluid, cycling of the bladder, visualisation of the ureter, presence of the contralateral kidney and abnormal organ findings [11](#)
- All neonates with documented antenatal hydronephrosis should have ultrasound scans at 5-10 days after birth and a repeat scan at 4 weeks if normal as false negatives are not uncommon at birth.[3, 5](#) If both scans are normal, the vast majority will not have any renal tract abnormalities and therefore do not require any further imaging [5, 7, 12](#)
- Mild hydronephrosis can be followed up by sequential ultrasound.[5](#) Although studies are conflicting with some showing a benign clinical course(13-15) and others showing deterioration over time [16](#)

## Micturating Cystourethrogram

- The role of a micturating cystourethrogram (MCU) is in the detection of vesicoureteric reflux (VUR) and urethral abnormalities such as posterior urethral valves.
- MCU should be performed on all neonates with unilateral or bilateral hydronephrosis with renal pelvic APD > 10 mm, SFU grade 3-4 or ureteric dilatation. [5, 7](#)
- The incidence of VUR in antenatal hydronephrosis ranges from 8 - 38% and up to 60% of patients with VUR will have a normal initial postnatal ultrasound. [3, 5](#)
- In cases of suspected bladder outlet obstruction, an MCU should be performed as early as possible. For the evaluation of possible VUR, an MCU can be delayed for up to one month after birth. [3](#)
- Disadvantages of MCU include:
  - Risk of infection and urethral trauma
  - Exposure to ionising radiation
  - May be distressing to patients and parents

## Mercaptoacetyltriglycine (MAG-3) Renogram

- Pelviureteric junction obstruction should be considered in infants with moderate or severe hydronephrosis, where dilating VUR is excluded and radionuclide scans performed with a diuretic are dynamic studies which allow for assessment of obstruction. [5, 17](#)
- Mercaptoacetyltriglycine (MAG-3) or a diethylene triamine pentaacetic acid (DTPA) can both be used, however, MAG-3 is preferred due to its favourable renal excretion properties, which allow for more

accurate assessment of renal drainage. However, DTPA is inexpensive and widely available. [5, 18, 19](#)

- Renograms require careful interpretation as they can be affected by the level of hydration, the region of interest selected for analysis and failure of the immature kidney to respond to the diuretic. (18) Some institutions perform a "well-tempered renogram" with intravenous hydration and a urethral catheter in-situ to minimise the effect of these variables. [17](#)
- Disadvantages of radionuclide scans include:
  - Exposure to ionising radiation
  - Can be difficult to interpret
  - "Well-tempered renograms" are invasive
  - Variable accuracy reported in the literature [3, 18](#)

## Technetium-99m Dimercaptosuccinic Acid (DMSA) Scan

- Currently considered the reference standard for the detection of renal scarring and differential renal function in children, particularly those with evidence of vesicoureteric reflux. [18](#)
- The study involves the intravenous injection of DMSA and scanning the kidneys with a gamma camera approximately 2-6 hours later.
- Currently, the long term implications of finding renal parenchymal defects on DMSA remains unquantified, however, the risk for future renal impairment, hypertension and poor quality of life is thought to be low. [3](#)

## Magnetic Resonance Urography (MRU)

- Magnetic Resonance Urography offers excellent anatomical visualisation and multiplanar 3D reconstruction as well as an assessment of differential renal function and drainage. [20, 21](#) It provides detailed information on renal pathology within a single study which correlates well with surgical findings. [19, 22, 23](#)
- MRU can accurately demonstrate all the common causes of antenatally detected hydronephrosis and guide subsequent management. [22, 24](#)
- Gadolinium-DTPA dimeglumine is used to assess the excretion and drainage of the kidneys.
- Advantages include:
  - Assessment of anatomical structure and function in a single study
  - Avoids ionising radiation
- Disadvantages include:
  - Require sedation and anaesthesia in young children
  - Relatively expensive with limited availability and requiring local expertise

## References

of literature search: February 2017

References are graded from Level I to V according to the Oxford Centre for Evidence-Based Medicine, Levels of Evidence. [Download the document](#)

1. Lee RS, Cendron M, Kinnamon DD, Nguyen HT. **Antenatal hydronephrosis as a predictor of postnatal outcome: A meta-analysis.** Pediatrics. 2006;118(2):586-93. (Meta-analysis). [View the reference](#)
2. Han M, Kim HG, Lee JD, Park SY, Sur YK. **Conversion and reliability of two urological grading**

**systems in infants: the Society for Fetal Urology and the urinary tract dilatation classifications system.** *Pediatr Radiol.* 2017;47(1):65-73. (Level II evidence). [View the reference](#)

3. Kitchens DM, Herndon CDA. **Antenatal hydronephrosis.** *Current urology reports.* 2009;10(2):126-33. (Review article). [View the reference](#)
4. Afroz R, Shakoor S, Salat MS, Munim S. **Antenatal renal pelvic dilatation and foetal outcomes - review of cases from a tertiary care center in Karachi, Pakistan.** *J Pak Med Assoc.* 2016;66(12):1597-601. (Level III evidence). [View the reference](#)
5. Sinha A, Bagga A, Krishna A, Bajpai M, Srinivas M, Uppal R, et al. **Revised guidelines on management of antenatal hydronephrosis.** *Indian Journal of Nephrology.* 2013;23(2):83-97. (Guidelines). [View the reference](#)
6. Fernbach SK, Maizels M, Conway JJ. **Ultrasound grading of hydronephrosis - Introduction to the system used by the Society for Fetal Urology.** *Pediatric radiology.* 1993;23(6):478-80. (Guidelines). [View the reference](#)
7. Riccabona M, Avni FE, Blickman JG, Dacher J-N, Darge K, Lobo ML, et al. **Imaging recommendations in paediatric urology: minutes of the ESPR workgroup session on urinary tract infection, fetal hydronephrosis, urinary tract ultrasonography and voiding cystourethrography, Barcelona, Spain, June 2007.** *Pediatric radiology.* 2008;38(2):138-45. (Level V evidence). [View the reference](#)
8. Hodhod A, Capolicchio JP, Jednak R, El-Sherif E, El-Doray Ael A, El-Sherbiny M. **Evaluation of Urinary Tract Dilatation Classification System for Grading Postnatal Hydronephrosis.** *J Urol.* 2016;195(3):725-30. (Level II evidence). [View the reference](#)
9. Ismaili K, Hall M, Donner C, Thomas D, Vermeylen D, Avni FE. **Results of systematic screening for minor degrees of fetal renal pelvis dilatation in an unselected population.** *American journal of obstetrics and gynecology.* 2003;188(1):242-6. (Level II evidence). [View the reference](#)
0. Sidhu G, Beyene J, Rosenblum ND. **Outcome of isolated antenatal hydronephrosis: a systematic review and meta-analysis.** *Pediatric Nephrology.* 2006;21(2):218-24. (Level II evidence). [View the reference](#)
1. Hindryckx A, De Catte L. **Prenatal diagnosis of congenital renal and urinary tract malformations.** *Facts, Views & Vision in ObGyn.* 2011;3(3):165-74. (Review article). [View the reference](#)
2. Moorthy I, Joshi N, Cook JV, Warren M. **Antenatal hydronephrosis: Negative predictive value of normal postnatal ultrasound - a 5-year study.** *Clinical radiology.* 2003;58(12):964-70. (Level III evidence). [View the reference](#)
3. Coelho GM, Bouzada MCF, Pereira AK, Figueiredo BF, Leite MRS, Oliveira DS, et al. **Outcome of isolated antenatal hydronephrosis: a prospective cohort study.** *Pediatric Nephrology.* 2007;22(10):1727-34. (Level III evidence). [View the reference](#)
4. de Kort EHM, Oetomo SB, Zegers SHJ. **The long-term outcome of antenatal hydronephrosis up to 15 millimetres justifies a noninvasive postnatal follow-up.** *Acta Paediatrica.* 2008;97(6):708-13. (Level II evidence). [View the reference](#)
5. Sairam S, Al-Habib A, Sasson S, Thilaganathan B. **Natural history of fetal hydronephrosis diagnosed on mid-trimester ultrasound.** *Ultrasound in obstetrics & gynecology.* 2001;17(3):191-6. (Level II evidence). [View the reference](#)
6. Signorelli M, Cerri V, Taddei F, Grolli C, Bianchi UA. **Prenatal diagnosis and management of mild fetal pyelectasis: implications for neonatal outcome and follow-up.** *European Journal of Obstetrics Gynecology and Reproductive Biology.* 2005;118(2):154-9. (Level III evidence). [View the reference](#)
7. Rosenblum S, Pal A, Reidy K. **Renal development in the fetus and premature infant.** *Semin Fetal Neonatal Med.* 2017;22(2):58-66. (Review article). [View the reference](#)
8. Woodward M, Frank D. **Postnatal management of antenatal hydronephrosis.** *Bju International.* 2002;89(2):149-56. (Review article). [View the reference](#)
9. Sadeghi-Bojd S, Kajbafzadeh AM, Ansari-Moghadam A, Rashidi S. **Postnatal Evaluation and Outcome of Prenatal Hydronephrosis.** *Iran J Pediatr.* 2016;26(2):e3667. (Level II/III evidence). [View the reference](#)
0. Grattan-Smith JD, Jones RA. **Magnetic Resonance Urography in Children.** *Magnetic Resonance*



- Imaging Clinics of North America. 2008;16(3):515-31. (Review article). [View the reference](#)
1. Cerwinka WH, Damien Grattan-Smith J, Kirsch AJ. **Magnetic resonance urography in pediatric urology.** Journal of pediatric urology. 2008;4(1):74-82. (Review article). [View the reference](#)
  2. Leppert A, Nadalin S, Schirg E, Petersen C, Kardorff R, Galanski M, et al. **Impact of magnetic resonance urography on preoperative diagnostic workup in children affected by hydronephrosis: Should IVU be replaced?** Journal of Pediatric Surgery. 2002;37(10):1441-5. (Level III evidence). [View the reference](#)
  3. El-Nahas AR, Abou El-Ghar ME, Refae HF, Gad HM, El-Diasty TA. **Magnetic resonance imaging in the evaluation of pelvi-ureteric junction obstruction: an all-in-one approach.** Bju International. 2007;99(3):641-5. (Level III/IV evidence). [View the reference](#)
  4. McMann LP, Kirsch AJ, Scherz HC, Smith EA, Jones RA, Shehata BM, et al. **Magnetic resonance urography in the evaluation of prenatally diagnosed hydronephrosis and renal dysgenesis.** Journal of Urology. 2006;176(4):1786-92. (Level III evidence). [View the reference](#)

## Information for Consumers

Information from this website	Information from the Royal Australian and New Zealand College of Radiologists' website
<p><a href="#">Consent to Procedure or Treatment</a></p> <p><a href="#">Radiation Risks of X-rays and Scans</a></p> <p><a href="#">Renal Scan</a></p> <p><a href="#">Ultrasound</a></p>	<p><a href="#">Iodine-Containing Contrast Medium</a></p> <p><a href="#">Radiation Risk of Medical Imaging During Pregnancy</a></p> <p><a href="#">Radiation Risk of Medical Imaging for Adults and Children</a></p> <p><a href="#">Ultrasound</a></p> <p><a href="#">Nuclear Medicine DMSA Scan</a></p> <p><a href="#">Nuclear Medicine Renal Scan</a></p> <p><a href="#">Children's (Paediatric) Abdominal Ultrasound</a></p> <p><a href="#">Children's (Paediatric) Micturating Cystourethrogram</a></p> <p><a href="#">Children's (Paediatric) Renal Ultrasound</a></p> <p><a href="#">Making Your Child's Test or Procedure Less Stressful</a></p>



## Copyright

Copyright 2017, Department of Health Western Australia. All Rights Reserved. This web site and its content has been prepared by The Department of Health, Western Australia. The information contained on this web site is protected by copyright.

## Disclaimer Notice

Please remember that this leaflet is intended as general information only. It is not definitive and The Department of Health, Western Australia can not accept any legal liability arising from its use. The information is kept as up to date and accurate as possible, but please be warned that it is always subject to change

## Formats

The documents for download on this website are in a Portable Document Format (PDF). To read these files you will need to download Adobe Acrobat Reader.

