

Diagnostic Imaging Pathways - Dementia

Population Covered By The Guidance

This pathway provides guidance on the imaging investigation of adult patients with cognitive decline, once systemic causes have been excluded.

Date reviewed: September 2014

Date of next review: 2017/2018






Published: December 2014

Quick User Guide

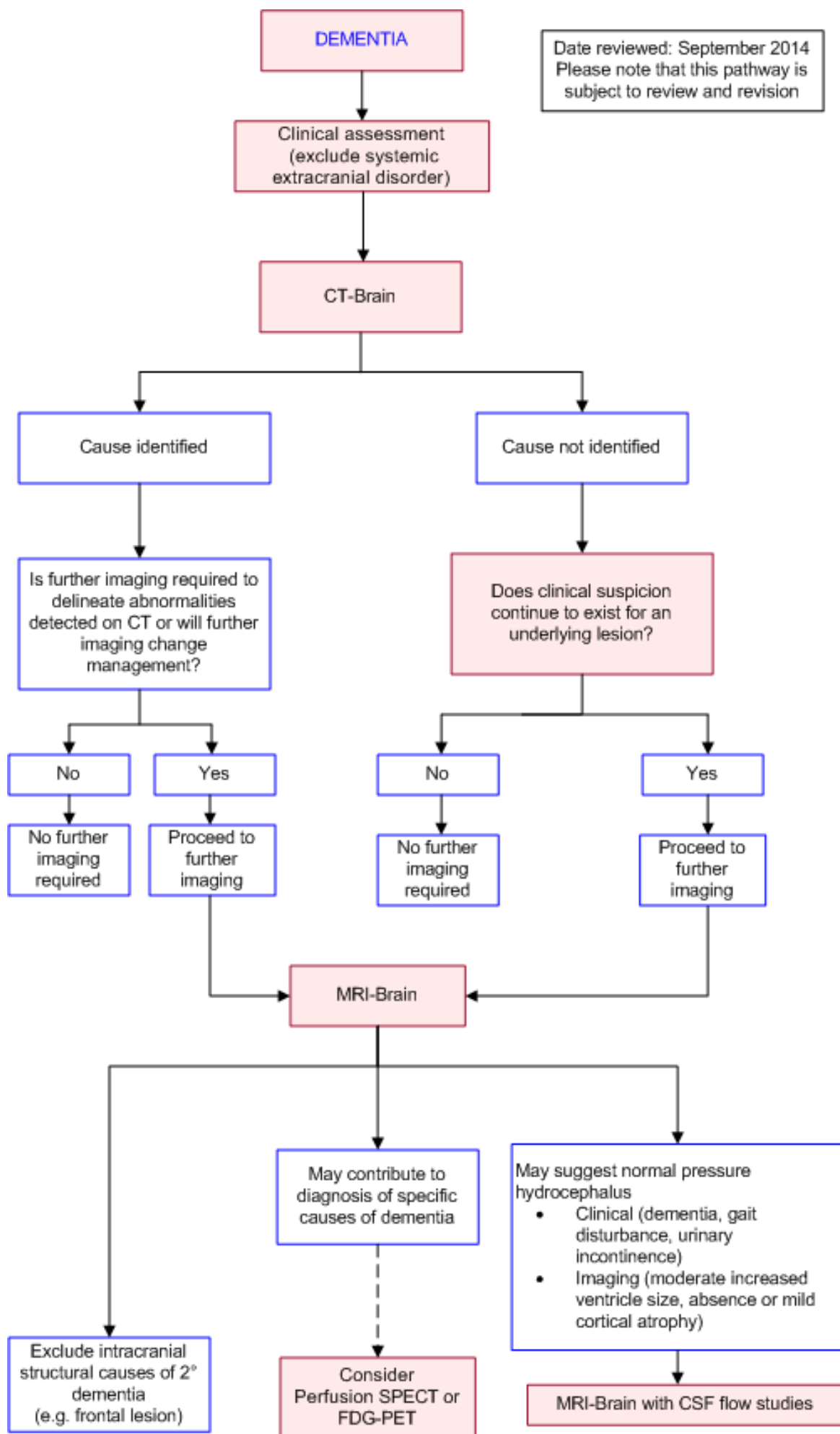
Move the mouse cursor over the **PINK** text boxes inside the flow chart to bring up a pop up box with salient points.

Clicking on the **PINK** text box will bring up the full text.

The relative radiation level (RRL) of each imaging investigation is displayed in the pop up box.

SYMBOL	RRL	EFFECTIVE DOSE RANGE
	None	0
	Minimal	< 1 millisieverts
	Low	1-5 mSv
	Medium	5-10 mSv
	High	>10 mSv

Pathway Diagram



Images

Coming soon

Teaching Points

- Dementia is a disorder that is characterised by impairment of memory and at least one other cognitive domain (aphasia, apraxia, agnosia or executive functioning). There must be a decline from previous level of function that is severe enough to interfere with daily function and independence
- There are many causes of dementia, though Alzheimer's disease and Vascular Dementia are the commonest. There are approximately 36 million people with dementia worldwide [1](#)
- Initial assessment of a patient thought to be dementing should include a systematic search for a reversible cause
- Imaging has a role in assessing for tumours, haematomas and hydrocephalus which may be treated. These may be visualised on contrast enhanced CT of the brain
- MRI, SPECT and PET modalities have a role in certain circumstances, after consultation with a specialist

Clinical Assessment and Neuroimaging In Dementia

- The neurological history and examination are essential components of the diagnostic work up of dementia and may reveal important clues to the aetiology of the patient's cognitive decline [2](#)
- Alzheimer's disease is the most common type of dementia and NINCDS-ADRDA criteria for probable AD has been the predominant criterion in use. [3](#) These have recently been revised to reflect the rapid advances in the understanding of AD and include the following stages of Alzheimer's disease
 1. Dementia due to Alzheimer's disease [4](#)
 2. Mild cognitive impairment (MCI) due to Alzheimer's disease [5](#)
 3. Preclinical Alzheimer's disease [6](#)
 4. Neuropathologic Assessment of Alzheimer's disease during autopsy [7](#)
- Neuroimaging (CT or MRI) is indicated to exclude other (treatable) intracranial disorders that might cause dementia, such as stroke, intra-axial or extra-axial tumours, subdural haematomas, hydrocephalus, and Creutzfeldt-Jakob disease [2, 3](#)
- There is now increasing awareness of the difficulty altering the disease course in AD once fully established hence there has been a paradigm shift that the earlier the intervention the better. [8](#) It is also now acknowledged that amyloid β ($A\beta$) deposition now precedes cerebral atrophy and cognitive decline [9,10](#)
- The American Academy of Neurology recommends structural neuroimaging with either a non-contrast head CT or MRI in the routine initial evaluation of all patients with dementia. [11](#) Various other guidelines including The National Institute of Health and Care Excellence(NICE), European Federation of the Neurological Societies(EFNS) and US based diagnostic guidelines recommend the use of neuroimaging using CT or MRI with a preference to MRI where available [6,12,13](#)

Magnetic Resonance Imaging (MRI) with CSF Flow Studies

- By gating the MRI to the cardiac cycle and CSF oscillatory flow, movement of the CSF can be monitored to identify blockages, especially in the aqueduct between the third and fourth ventricles. Hyperdynamic flow demonstrated in the aqueduct supports a diagnosis of NPH [14](#)
- Increased CSF flow void through cerebral aqueduct on MRI appears to correlate with a good response to shunt surgery [15](#)

Computed Tomography (CT)

- May show general or regionalised atrophy, white matter low attenuation which in part may relate to vascular disease, space-occupying lesions, and vascular disease [16-18](#)
- May demonstrate gross hippocampal atrophy, which may suggest Alzheimer's disease [18-20](#)
- Limitations [17](#)
 - Limited soft tissue resolution
 - May miss old haemorrhagic foci
 - Poor visualisation of the posterior fossa
 - Less sensitive to ocular disease than MRI
 - May miss early infarction

Magnetic Resonance Imaging (MRI)

- Higher sensitivity than CT in detecting most intracranial pathologies. [21](#) The overall sensitivity and specificity of MRI in detection of space occupying lesions is 88.9 percent and 91.9 percent respectively compared to CT where sensitivity and specificity is 80.1 percent and 85.4 percent respectively [22](#)
- MR-based volumetric measurements of the hippocampal formation allow differentiation of patients with probable AD from normal elderly individuals [23,24](#)
- Patients with normal pressure hydrocephalus with the classic clinical triad (dementia, gait disturbance, and urinary incontinence) and CT/MRI findings of enlarged ventricles and absence of or only mild cortical atrophy, are more likely to respond to shunt and may benefit from further imaging with SPECT cisternography [25](#)
- Advantages [17](#)
 1. Allows assessment of grey and white matter bulk; and global and regional volume
 2. More accurate assessment of the morphological features of hydrocephalus
 3. Ability to image small, small vessel ischaemic disease, lacunar strokes and posterior fossa lesions
 4. Superior to CT in imaging subacute haemorrhage
 5. Permits direct visualisation of hippocampal formation
- Disadvantages
 1. Contraindicated in patients with metallic implants
 2. Relative contraindications (claustrophobic, anxious patients)
 3. Limited availability and high expense
 4. Increased risk of motion artefact due to longer image acquisition times

Position Emission Tomography (PET) (Fluorodeoxyglucose [FDG])



- Depending on ligand, provides information on [17,26](#)
 1. Neuronal function
 2. Glucose metabolism
 3. Cerebral blood flow
 4. Receptor characteristics (e.g. density, affinity)
- Assists in confirming the diagnosis of Alzheimer's disease (shows characteristic reductions in glucose metabolic rates and cerebral blood flow in patients with probable and definitive AD in the parietal, temporal, and posterior cingulate regions)
- Can differentiate patients with Alzheimer's disease from patients with other dementias (such as vascular dementia, fronto-temporal dementia, and Huntington's disease) and from cognitively intact people
- 91 percent sensitivity and 86 percent specificity in the diagnosis of Alzheimer's disease. [27,28](#) This meta-analysis found FDG-PET to have superior diagnostic accuracy when compared to other methods such as clinical guidelines, MRI, CT, SPECT and biomarkers [28](#)
- FDG-PET has a higher accuracy than Magnetic Resonance Imaging for the diagnosis of early AD [29](#)
- A growing field in PET imaging is that of specific radiotracers such as amyloid radiotracers like 11C-PiB or 18F tracers (there are several e.g. 18F-florbetaben) which have been found to outperform 18F-FDG in visual analysis comparing the two in the identification of AD. [30](#) A 2012 meta analysis comparing the two regarding the diagnostic accuracy for the prediction of short term conversion to AD in patients with MCI(Mild Cognitive Impairment) found FDG-PET with a sensitivity of 78.7 percent and 74 percent respectively and PIB-PET 93.5 percent and 56.2 percent respectively [31](#)
- Amyloid radiotracers may also have application in distinguishing AD from frontotemporal lobar degeneration (FTLD). [32,33](#) When compared against FDG, PIB was more sensitive (89 percent versus 73 percent) but less specific (83 percent versus 98 percent)
- FDG-PET has a 90 percent sensitivity and 80 percent specificity in being able to distinguish Dementia with Lewy bodies (DLB) from AD
- PET also has been found to accurately distinguish normal functioning patients from those with MCI [34](#)

Single Photon Emission Computed Tomography (SPECT)

- Physiological imaging technique using a 99m-Tc, or 131-I tracer, that is most useful in providing information on neuronal function (e.g. cerebral blood flow) [17](#)
- May assist in the evaluation of the differential diagnosis of dementing illness
- Direct comparison of PET versus SPECT in the diagnosis of neurodegenerative dementias suggests that PET has a superiority of SPECT though the evidence base is somewhat limited [35](#)
- Assists in confirming the diagnosis of Alzheimer's disease (reveals bilateral temporo-parietal, posterior cingulate gyrus and/or hippocampal hypoperfusion and hemispheric asymmetry in Alzheimer's disease - consistent functional patterns in Alzheimer's disease) [18](#)
- A systematic review into the ability of SPECT in differentiating types of dementias found the following [36](#)
 - 79.7 percent sensitive and 79.9 percent specific in distinguishing AD from frontotemporal dementia (FTD)
 - 74.5 percent sensitive and 72.4 percent specific in distinguishing AD from vascular dementia (VD)
 - 70.2 percent sensitive and 76.2 percent specific in distinguishing AD from dementia with Lewy bodies (DLB)
 - 76.1 percent sensitive and 85.4 percent specific in distinguishing AD from normal controls
- Routine use of SPECT for diagnosis of Alzheimer's disease is not currently recommended, as a

- normal SPECT does not exclude the diagnosis of Alzheimer's disease
- Advantages
 - Gives functional information
 - More widely available compared to PET scan
- Limitations: lower spatial resolution than PET (does not identify deep structures as well)

SPECT Nuclear Medicine Cisternography

- Useful in the evaluation of patients with normal pressure hydrocephalus as it allows distinction of patients who are likely to respond to shunt from non-responders [37](#)

References

Date of literature search: June 2014

The search methodology is available on request. [Email](#)

References are graded from Level I to V according to the Oxford Centre for Evidence-Based Medicine, Levels of Evidence. [Download the document](#)

1. Wortmann M. **Dementia: a global health priority - highlights from an ADI and World Health Organization report.** *Alzheimers Res Ther.* 2012;4(5):40. (Review article). [View the reference](#)
2. **Practice parameter for diagnosis and evaluation of dementia. Report of the Quality Standards Subcommittee of the American Academy of Neurology.** *Neurology.* 1994;44(11):2203-6. (Consensus statement). [View the reference](#)
3. McKhann G, Drachman D, Folstein M, Katzman R, Price D, Stadlan EM. **Clinical diagnosis of Alzheimer's disease: Report of the NINCDS-ARDA Work Group under the auspices of Department of Health and Human Services Task Force on Alzheimer's disease.** *Neurology.* 1984;34(7):939-44. [View the reference](#)
4. McKhann GM, Knopman DS, Chertkow H, Hyman BT, Jack CR, Jr., Kawas CH, et al. **The diagnosis of dementia due to Alzheimer's disease: recommendations from the National Institute on Aging-Alzheimer's Association workgroups on diagnostic guidelines for Alzheimer's disease.** *Alzheimers Dement.* 2011;7(3):263-9. (Guideline document). [View the reference](#)
5. Albert MS, DeKosky ST, Dickson D, Dubois B, Feldman HH, Fox NC, et al. **The diagnosis of mild cognitive impairment due to Alzheimer's disease: recommendations from the National Institute on Aging-Alzheimer's Association workgroups on diagnostic guidelines for Alzheimer's disease.** *Alzheimers Dement.* 2011;7(3):270-9. (Guideline document). [View the reference](#)
6. Jack CR, Jr., Albert MS, Knopman DS, McKhann GM, Sperling RA, Carrillo MC, et al. **Introduction to the recommendations from the National Institute on Aging-Alzheimer's Association workgroups on diagnostic guidelines for Alzheimer's disease.** *Alzheimers Dement.* 2011;7(3):257-62. (Review article)
7. Hyman BT, Phelps CH, Beach TG, Bigio EH, Cairns NJ, Carrillo MC, et al. **National Institute on Aging-Alzheimer's Association guidelines for the neuropathologic assessment of Alzheimer's disease.** *Alzheimers Dement.* 2012;8(1):1-13. (Guideline document). [View the reference](#)

[reference](#)

8. Villemagne VL, Burnham S, Bourgeat P, Brown B, Ellis KA, Salvado O, et al. **Amyloid beta deposition, neurodegeneration, and cognitive decline in sporadic Alzheimer's disease: a prospective cohort study** Lancet Neurol. 2013;12(4):357-67. (Level I evidence). [View the reference](#)
9. Jack CR, Jr., Knopman DS, Weigand SD, Wiste HJ, Vemuri P, Lowe V, et al. **An operational approach to National Institute on Aging-Alzheimer's Association criteria for preclinical Alzheimer disease.** Ann Neurol. 2012;71(6):765-75. (Guidelines document). [View the reference](#)
10. Jack CR, Jr., Knopman DS, Jagust WJ, Petersen RC, Weiner MW, Aisen PS, et al. **Tracking pathophysiological processes in Alzheimer's disease: an updated hypothetical model of dynamic biomarkers.** Lancet Neurol. 2013;12(2):207-16. (Review article). [View the reference](#)
11. Knopman DS, DeKosky ST, Cummings JL, Chui H, Corey-Bloom J, Relkin N, et al. **Practice parameter: diagnosis of dementia (an evidence-based review). Report of the Quality Standards Subcommittee of the American Academy of Neurology.** Neurology. 2001;56(9):1143-53. (Level I evidence). [View the reference](#)
12. Dubois B, Feldman HH, Jacova C, Dekosky ST, Barberger-Gateau P, Cummings J, et al. **Research criteria for the diagnosis of Alzheimer's disease: revising the NINCDS-ADRDA criteria.** Lancet Neurol. 2007;6(8):734-46. (Review article). [View the reference](#)
13. Hort J, O'Brien JT, Gainotti G, Pirttila T, Popescu BO, Rektorova I, et al. **EFNS guidelines for the diagnosis and management of Alzheimer's disease.** Eur J Neurol. 2010;17(10):1236-48. (Evidence Based Guidelines). [View the reference](#)
14. Factora R, Luciano M. **Normal pressure hydrocephalus: diagnosis and new approaches to treatment.** Clin Geriatr Med. 2006;22(3):645-57. (Review article). [View the reference](#)
15. Bradley WG, Jr., Whittemore AR, Kortman KE, Watanabe AS, Homyak M, Teresi LM, et al. **Marked cerebrospinal fluid void: indicator of successful shunt in patients with suspected normal-pressure hydrocephalus.** Radiology. 1991;178(2):459-66. (Level III evidence). [View the reference](#)
16. Scheltens P. **Early diagnosis of dementia: neuroimaging.** J Neurol. 1999;246(1):16-20. (Review article). [View the reference](#)
17. Small GW, Leiter F. **Neuroimaging for diagnosis of dementia.** J Clin Psychiatry. 1998;59 Suppl 11:4-7. (Review article). [View the reference](#)
18. Jobst KA, Hindley NJ, King E, Smith AD. **The diagnosis of Alzheimer's disease: a question of image?** J Clin Psychiatry. 1994;55 Suppl:22-31. (Level II/III evidence). [View the reference](#)
19. Jobst KA, Smith AD, Szatmari M, Molyneux A, Esiri ME, King E, et al. **Detection in life of confirmed Alzheimer's disease using a simple measurement of medial temporal lobe atrophy by computed tomography.** Lancet. 1992;340(8829):1179-83. (Level IV evidence). [View the reference](#)
20. de Leon MJ, George AE, Stylopoulos LA, Smith G, Miller DC. **Early marker for Alzheimer's disease: the atrophic hippocampus.** Lancet. 1989;2(8664):672-3. (Level III evidence). [View the reference](#)
21. Jagust WJ, Eberling JL. **MRI, CT, SPECT, PET: their use in diagnosing dementia.** Geriatrics. 1991;46(2):28-35. (Review article). [View the reference](#)
22. Bermingham SL. **The appropriate use of neuroimaging in the diagnostic work-up of dementia: an economic literature review and cost-effectiveness analysis.** Ont Health Technol Assess Ser. 2014;14(2):1-67. (Level II evidence). [View the reference](#)
23. Jack CR, Jr., Petersen RC, O'Brien PC, Tangalos EG. **MR-based hippocampal volumetry in the diagnosis of Alzheimer's disease.** Neurology. 1992;42(1):183-8. (Level III evidence). [View the reference](#)
24. Pantel J, Schroder J, Schad LR, Friedlinger M, Knopp MV, Schmitt R, et al. **Quantitative magnetic resonance imaging and neuropsychological functions in dementia of the Alzheimer type.** Psychol Med. 1997;27(1):221-9. (Level III evidence). [View the reference](#)



25. Vanneste J, Augustijn P, Tan WF, Dirven C. **Shunting normal pressure hydrocephalus: the predictive value of combined clinical and CT data.** J Neurol Neurosurg Psychiatry. 1993;56(3):251-6. (Level III evidence). [View the reference](#)
26. Daniela P, Orazio S, Alessandro P, Mariano NF, Leonardo I, Pasquale Anthony DR, et al. **A survey of FDG- and amyloid-PET imaging in dementia and GRADE analysis.** Biomed Res Int. 2014;2014:785039. (Level II evidence). [View the reference](#)
27. Marcus C, Mena E, Subramaniam RM. **Brain PET in the diagnosis of Alzheimer's disease.** Clin Nucl Med. 2014;39(10):e413-22; quiz e23-6. (Review article)
28. Bloudek LM, Spackman DE, Blankenburg M, Sullivan SD. **Review and meta-analysis of biomarkers and diagnostic imaging in Alzheimer's disease.** J Alzheimers Dis. 2011;26(4):627-45. (Level I evidence)
29. Ishii K. **PET Approaches for diagnosis of dementia.** AJNR Am J Neuroradiol. 2014;35(11):2030-8. (Review article). [View the reference](#)
30. Ng S, Villemagne VL, Berlangieri S, Lee ST, Cherk M, Gong SJ, et al. **Visual assessment versus quantitative assessment of 11C-PIB PET and 18F-FDG PET for detection of Alzheimer's disease.** J Nucl Med. 2007;48(4):547-52. (Level III evidence). [View the reference](#)
31. Zhang S, Han D, Tan X, Feng J, Guo Y, Ding Y. **Diagnostic accuracy of 18 F-FDG and 11 C-PIB-PET for prediction of short-term conversion to Alzheimer's disease in subjects with mild cognitive impairment.** Int J Clin Pract. 2012;66(2):185-98. (Level I evidence)
32. Rabinovici GD, Rosen HJ, Alkalay A, Kornak J, Furst AJ, Agarwal N, et al. **Amyloid vs FDG-PET in the differential diagnosis of AD and FTL D.** Neurology. 2011;77(23):2034-42. (Level II evidence). [View the reference](#)
33. Vandenberghe R, Adamczuk K, Van Laere K. **The interest of amyloid PET imaging in the diagnosis of Alzheimer's disease.** Curr Opin Neurol. 2013;26(6):646-55. (Review article). [View the reference](#)
34. Okello A, Koivunen J, Edison P, Archer HA, Turkheimer FE, Nagren K, et al. **Conversion of amyloid positive and negative MCI to AD over 3 years: an 11C-PIB PET study.** Neurology. 2009;73(10):754-60. (Level II evidence). [View the reference](#)
35. Davison CM, O'Brien JT. **A comparison of FDG-PET and blood flow SPECT in the diagnosis of neurodegenerative dementias: a systematic review.** Int J Geriatr Psychiatry. 2014;29(6):551-61. (Review article). [View the reference](#)
36. Yeo JM, Lim X, Khan Z, Pal S. **Systematic review of the diagnostic utility of SPECT imaging in dementia.** Eur Arch Psychiatry Clin Neurosci. 2013;263(7):539-52. (Level I evidence). [View the reference](#)
37. Larsson A, Arlig A, Bergh AC, Bilting M, Jacobsson L, Stephensen H, et al. **Quantitative SPECT cisternography in normal pressure hydrocephalus.** Acta Neurol Scand. 1994;90(3):190-6. (Level II evidence). [View the reference](#)

Information for Consumers

Information from this website	Information from the Royal Australian and New Zealand College of Radiologists' website
Consent to Procedure or Treatment Radiation Risks of X-rays and Scans	Computed Tomography (CT) Contrast Medium (Gadolinium versus

Computed Tomography (CT)	Iodine)
Magnetic Resonance Imaging (MRI)	Gadolinium Contrast Medium
Positron Emission Tomography (PET)	Iodine-Containing Contrast Medium
	Magnetic Resonance Imaging (MRI)
	Plain Radiography/X-rays
	Radiation Risk of Medical Imaging During Pregnancy
	Radiation Risk of Medical Imaging for Adults and Children
	Cerebral Perfusion Study
	Nuclear Medicine
	PET Scan
	SPECT-CT Scan

Copyright

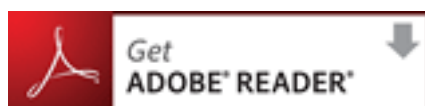
© Copyright 2015, Department of Health Western Australia. All Rights Reserved. This web site and its content has been prepared by The Department of Health, Western Australia. The information contained on this web site is protected by copyright.

Legal Notice

Please remember that this leaflet is intended as general information only. It is not definitive and The Department of Health, Western Australia can not accept any legal liability arising from its use. The information is kept as up to date and accurate as possible, but please be warned that it is always subject to change

File Formats

Some documents for download on this website are in a Portable Document Format (PDF). To read these files you might need to download Adobe Acrobat Reader.



[Legal Matters](#)