

# Diagnostic Imaging Pathways - Transient Ischaemic Attack

## Population Covered By The Guidance

This pathway provides guidance on the imaging of adult patients presenting with a history of suspected transient ischaemic attack.

**Date reviewed: September 2016**

**Date of next review: September 2019**






**Published: July 2017**

### Quick User Guide

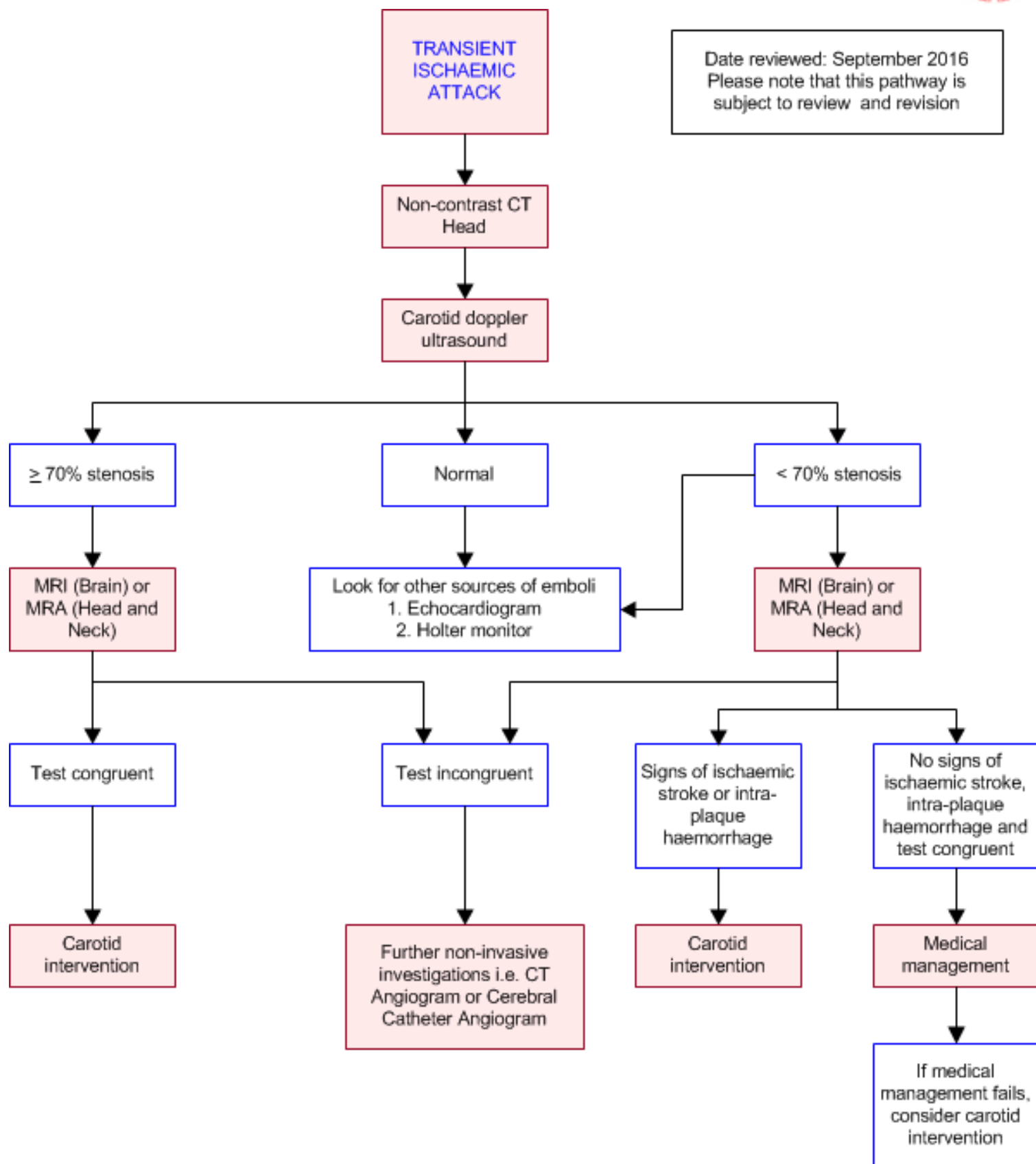
Move the mouse cursor over the **PINK** text boxes inside the flow chart to bring up a pop up box with salient points.

Clicking on the **PINK** text box will bring up the full text.

The relative radiation level (RRL) of each imaging investigation is displayed in the pop up box.

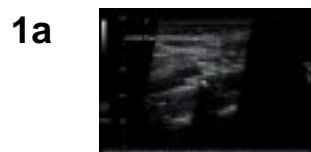SYMBOL	RRL	EFFECTIVE DOSE RANGE
	None	0
	Minimal	< 1 millisieverts
	Low	1-5 mSv
	Medium	5-10 mSv
	High	>10 mSv

## Pathway Diagram



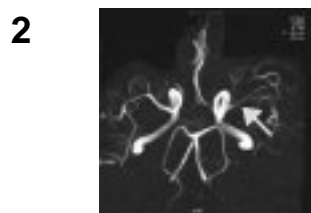
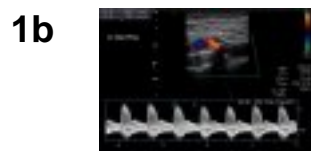## Image Gallery

**Note: These images open in a new page**



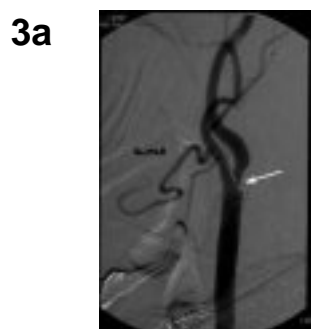
### Left Common and Internal Carotid Artery Stenosis

Image 1a and 1b (Carotid Doppler): Moderate amount of plaque at the origin of the left common carotid artery (arrow) extending into the internal carotid artery. Velocity measurements indicate stenosis in the order of 70%.



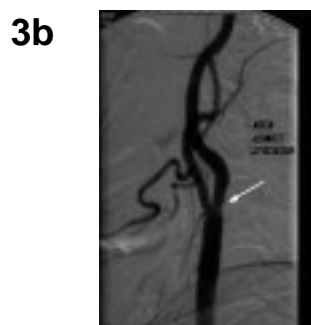### Left Middle Cerebral Artery Stenosis

Image 2 (MR Angiography): Narrowing of the left middle cerebral artery with reduced flow (arrow).



### Left Internal Carotid Artery Stenosis

Image 3a and 3b (Digital Subtraction Angiography): Pre- and post-angioplasty views of a left internal carotid artery stenosis (arrows).



## Teaching Points

- Patients with TIA should preferably undergo neuroimaging evaluation within 24 hours of symptoms onset
- A non-contrast computed tomography (CT) is the initial imaging modality of choice in suspected TIA to identify haemorrhage, ischaemia or space occupying lesion
- Carotid Doppler ultrasound should be performed to assess for extracranial arterial stenosis or plaque
- If the carotid arteries are normal (i.e. no plaque) or had <70% stenosis, alternative sources of cerebral emboli should be considered

### **(Echocardiogram/Holter)**

- **After carotid Doppler, Magnetic Resonance Imaging (MRI)-Brain and Magnetic Resonance Angiography (MRA)-Head and Neck should be considered to assess for ischaemic changes in brain parenchyma and carotid artery stenosis with plaque characteristics respectively**
- **If there is uncertainty as to the degree of carotid stenosis, further non-invasive imaging with CT Angiography is recommended. If two noninvasive tests are discordant, Cerebral Catheter Angiogram should be considered**
- **Treatment options include medical management, carotid endarterectomy or carotid angioplasty/stenting for athero-occlusive disease of the carotid artery**

## **Transient Ischaemic Attack (TIA)**

- **Approximately half of the early risk of stroke after a TIA occurs within the first 48hrs and therefore early diagnostic workup and treatment is mandatory. [2, 3](#)**  
**The ABCD<sup>2</sup> tool has been suggested as a means of risk stratifying patients with TIA [2](#)**
  - **A Age ? 60 years (1 point)**
  - **B Blood pressure: systolic ? 140 or diastolic ? 90mmHg (1 point)**
  - **C Clinical features: unilateral weakness (2 points), speech impairment without weakness (1 point)**
  - **D Duration: ? 60mins (2 points) or 10-59 mins (1 point)**
  - **D Diabetes: Present (1 point)**

**Total Score >4 = high risk, ?4 = low risk**

- **High risk patients should have imaging within 24 hours, be considered for admission or referral to a TIA clinic for urgent assessment and be treated as for an acute stroke. Low risk patients should have a head CT as soon as possible (within 48-72hrs) and should be referred to a general practitioner, private specialist or TIA clinic for ongoing assessment. Carotid duplex ultrasound is recommended for patients with carotid territory symptoms (eg, amaurosis fugax, dysphasia) [1, 2, 4](#)**

## **Computed Tomography (CT)**

- **A non-contrast CT is the initial imaging modality of choice in transient ischaemic attack**
- **CT Brain is useful to exclude conditions that could mimic TIA such as haemorrhage or brain tumour and should be carried out in all patients [2](#)**
- **May reveal an area of brain infarction appropriate to TIA symptoms in 15-30% of patients (which may influence subsequent management, especially the**

- timing of an eventual carotid endarterectomy) [5, 6](#)
- CT has high specificity (1.00, 95% CI 0.94 – 1.00) and low sensitivity (0.39, 95% CI 0.16 – 0.69) [7](#)
- Advantages
  - Widely available and less expensive than MRI
  - Excellent sensitivity for detecting acute haemorrhage [8](#)
- Disadvantages
  - Less sensitive than DWI for the detection of acute ischaemia within first 12 hours [7, 8](#)
  - Ionizing radiation – this may be of significance in younger patients

## Carotid Doppler Ultrasound (US)

- Recommended for all patients with carotid artery territory symptoms (e.g., amaurosis fugax, dysphasia) who would potentially be candidates for carotid re-vascularisation
- Screening modality of choice for the study of vessels involved in causing symptoms of transient ischaemic attacks [9,10](#)
- ~87% sensitivity and ~75% specificity in identifying severe internal carotid artery stenosis [10, 11](#)
- In some centres, Doppler ultrasonography is viewed as a screening test and patients with > 50% stenosis in the ipsilateral carotid artery with symptomatic disease are referred for further imaging in the form of MRA or CTA
- Advantages: non-invasive, relatively inexpensive and widely available
- Disadvantages
  - More "operator dependant" compared to other imaging modalities
  - Difficult to distinguish between 'trickle flow' seen in severe stenosis, and complete occlusion

## Magnetic Resonance Imaging (MRI)

- MRI involves static magnetic field and non-ionizing radiation to acquire diagnostic images
- MRI is ideal for soft tissue imaging like Brain and Spine
- Advantages:
  - Does not involve ionising radiation
  - Superior soft tissue contrast and hence better yield than CT
- Disadvantages:
  - Limited availability
  - Longer acquisition time
  - Not suitable for patients with metal implants or foreign body

## Magnetic Resonance Angiography (MRA)

- **Traditional non-enhanced MRA (Time of Flight MRA) is a non-invasive procedure utilising flow-related enhancement. Contrast-enhanced MRA (CE MRA) is a relatively new form of imaging involving a time-optimised bolus of gadolinium-based intravenous contrast to define the vasculature [12, 13](#)**
- **The sensitivity and specificity for MRA in the detection of intracranial artery stenosis and occlusions has varied between 85%-100% and 91%-97% respectively in comparison to digital subtraction angiography [14-16](#)**
- **Some studies [17](#) suggest that a higher agreement rate exists between Carotid Doppler ultrasound + MRA rather than between Carotid Doppler ultrasound + CTA and a recently published meta-analysis indicates MRA as the most accurate test for the identification of critical (>70%) stenosis in both symptomatic and asymptomatic subjects [18](#)**
- **A strategy using combination of carotid Doppler ultrasound and MRA, reserving Digital Subtraction Angiography (DSA) for incongruent results, has been found to maximise quality adjusted life expectancy, and was cost effective alternative to using DSA alone [9](#)**
- **More recent studies support the use of contrast enhanced MRA as a diagnostic alternative to DSA in the preoperative evaluation of patients prior to carotid endarterectomy [19, 20](#)**
- **Advantages**
  - non-invasive
  - relatively less expensive and safer than catheter cerebral angiography
- **Limitations: [21](#)**
  - MR scanners are not widely available
  - Overestimates the degree of arterial stenosis especially in high grade narrowing
  - Difficulties in depiction of distal and small vessels which is exacerbated in older patients
  - Limited sensitivity for the detection of small cerebral aneurysms (
  - Carotid atheromatous ulceration is not reliably visualised

## Carotid Intervention [22, 23](#)

- **Three major randomized trials have demonstrated the superiority of Carotid Endarterectomy plus medical therapy over medical therapy alone for symptomatic patients with a high-grade (>70% angiographic stenosis) atherosclerotic carotid stenosis [24-26](#)**
- **For patients with a TIA or ischaemic stroke within past 6 months and ipsilateral severe (>70% stenosis) carotid artery stenosis as documented by non-invasive imaging, Carotid Endarterectomy (CEA) or Carotid Artery**

**Stenting (CAS) is recommended if peri-operative morbidity and mortality risk is estimated to be**

## **Catheter Cerebral Angiogram**

- **Digital Subtraction Angiography, the most widely used method of conventional catheter-based angiography, remains the gold standard for evaluating the cerebral vessels with regard to determining the degree of arterial stenosis and the presence of dissection, vasculopathy, vasculitis or occult lesion such as vascular malformation [38](#)**
- **Rarely performed in acute setting due to availability of non-invasive modalities such as CTA and MRA**
- **Involves risk of stroke (0.14 to 1 percent) and TIA (0.4 to 3 percent) [39, 40](#)**

## **References**

Date of literature search: May 2016

References are graded from Level I to V according to the Oxford Centre for Evidence-Based Medicine, Levels of Evidence. [Download the document](#)

- 1. Easton JD, Saver JL, Albers GW, Alberts MJ, Chaturvedi S, Feldmann E, et al. Definition and evaluation of transient ischemic attack: a scientific statement for healthcare professionals from the American Heart Association/American Stroke Association Stroke Council; Council on Cardiovascular Surgery and Anesthesia; Council on Cardiovascular Radiology and Intervention; Council on Cardiovascular Nursing; and the Interdisciplinary Council on Peripheral Vascular Disease. The American Academy of Neurology affirms the value of this statement as an educational tool for neurologists. *Stroke; a journal of cerebral circulation.* 2009;40(6):2276-93. (Guidelines). [View the reference](#)**
- 2. Silvestri GA, Gonzalez AV, Jantz MA, Margolis ML, Gould MK, Tanoue LT, et al. Methods for staging non-small cell lung cancer: Diagnosis and management of lung cancer, 3rd ed: American College of Chest Physicians evidence-based clinical practice guidelines. *Chest.* 2013;143(5 Suppl):e211S-50S. (Guidelines). [View the reference](#)**
- 3. Johnston SC, Rothwell PM, Nguyen-Huynh MN, Giles MF, Elkins JS, Bernstein AL, et al. Validation and refinement of scores to predict very early stroke risk after transient ischaemic attack. *Lancet (London, England).* 2007;369(9558):283-92. (Level II Evidence). [View the reference](#)**
- 4. National Institute of Clinical Studies. Emergency department stroke and transient ischaemic attack care bundle - Information and implementation**



- package. 2009 :(Guidelines). [View the reference](#)
5. Evans GW, Howard G, Murros KE, Rose LA, Toole JF. Cerebral infarction verified by cranial computed tomography and prognosis for survival following transient ischemic attack. *Stroke; a journal of cerebral circulation*. 1991;22(4):431-6. (Level III Evidence). [View the reference](#)
  6. Dennis M, Bamford J, Sandercock P, Molyneux A, Warlow C. Computed tomography in patients with transient ischaemic attacks: when is a transient ischaemic attack not a transient ischaemic attack but a stroke? *Journal of neurology*. 1990;237(4):257-61. (Level III Evidence). [View the reference](#)
  7. Brazzelli M, Sandercock PA, Chappell FM, Celani MG, Righetti E, Arestis N, et al. Magnetic resonance imaging versus computed tomography for detection of acute vascular lesions in patients presenting with stroke symptoms. *The Cochrane database of systematic reviews*. 2009(4):Cd007424. (Level I Evidence). [View the reference](#)
  8. Sanelli PC, Sykes JB, Ford AL, Lee JM, Vo KD, Hallam DK. Imaging and treatment of patients with acute stroke: an evidence-based review. *AJNR American journal of neuroradiology*. 2014;35(6):1045-51. (Review Article). [View the reference](#)
  9. Kent KC, Kuntz KM, Patel MR, Kim D, Klufas RA, Whittemore AD, et al. Perioperative imaging strategies for carotid endarterectomy. An analysis of morbidity and cost-effectiveness in symptomatic patients. *Jama*. 1995;274(11):888-93. (Level III Evidence). [View the reference](#)
  10. Nederkoorn PJ, Mali WP, Eikelboom BC, Elgersma OE, Buskens E, Hunink MG, et al. reoperative diagnosis of carotid artery stenosis: accuracy of noninvasive testing. *Stroke; a journal of cerebral circulation*. 2002;33(8):2003-8. (Level II Evidence). [View the reference](#)
  11. Blakeley DD, Oddone EZ, Hasselblad V, Simel DL, Matchar DB. Noninvasive carotid artery testing. A meta-analytic review. *Annals of internal medicine*. 1995;122(5):360-7. (Level I Evidence). [View the reference](#)
  12. Sohn CH, Sevick RJ, Frayne R. Contrast-enhanced MR angiography of the intracranial circulation. *Magnetic resonance imaging clinics of North America*. 2003;11(4):599-614. (Review Article). [View the reference](#)
  13. Clifton AG. MR angiography. *British medical bulletin*. 2000;56(2):367-77. (Review Article). [View the reference](#)
  14. Hirai T, Korogi Y, Ono K, Nagano M, Maruoka K, Uemura S, et al. Prospective evaluation of suspected stenoocclusive disease of the intracranial artery: combined MR angiography and CT angiography compared with digital subtraction angiography. *AJNR American journal of neuroradiology*. 2002;23(1):93-101. (Level III Evidence). [View the reference](#)
  15. Korogi Y, Takahashi M, Mabuchi N, Miki H, Shiga H, Watabe T, et al.





- Intracranial vascular stenosis and occlusion: diagnostic accuracy of three-dimensional, Fourier transform, time-of-flight MR angiography. Radiology. 1994;193(1):187-93. (Level III Evidence). [View the reference](#)**
- 16. Stock KW, Radue EW, Jacob AL, Bao XS, Steinbrich W. Intracranial arteries: prospective blinded comparative study of MR angiography and DSA in 50 patients. Radiology. 1995;195(2):451-6. (Level III Evidence). [View the reference](#)**
  - 17. Wardlaw JM, Chappell FM, Best JJ, Wartolowska K, Berry E. Non-invasive imaging compared with intra-arterial angiography in the diagnosis of symptomatic carotid stenosis: a meta-analysis. Lancet (London, England). 2006;367(9521):1503-12. (Level I Evidence). [View the reference](#)**
  - 18. Chappell FM, Wardlaw JM, Young GR, Gillard JH, Roditi GH, Yip B, et al. Carotid artery stenosis: accuracy of noninvasive tests-individual patient data meta-analysis. Radiology. 2009;251(2):493-502. (Level I Evidence). [View the reference](#)**
  - 19. Remonda L, Senn P, Barth A, Arnold M, Lovblad KO, Schroth G. Contrast-enhanced 3D MR angiography of the carotid artery: comparison with conventional digital subtraction angiography. AJNR American journal of neuroradiology. 2002;23(2):213-9. (Level II Evidence). [View the reference](#)**
  - 20. Westwood ME, Kelly S, Berry E, Bamford JM, Gough MJ, Airey CM, et al. Use of magnetic resonance angiography to select candidates with recently symptomatic carotid stenosis for surgery: systematic review. BMJ (Clinical research ed). 2002;324(7331):198. (Level I Evidence). [View the reference](#)**
  - 21. Korogi Y, Takahashi M, Nakagawa T, Mabuchi N, Watabe T, Shiokawa Y, et al. Intracranial vascular stenosis and occlusion: MR angiographic findings. AJNR American journal of neuroradiology. 1997;18(1):135-43. (Level III Evidence). [View the reference](#)**
  - 22. Kernan WN, Ovbiagele B, Black HR, Bravata DM, Chimowitz MI, Ezekowitz MD, et al. Guidelines for the prevention of stroke in patients with stroke and transient ischemic attack: a guideline for healthcare professionals from the American Heart Association/American Stroke Association. Stroke; a journal of cerebral circulation. 2014;45(7):2160-236. (Guidelines). [View the reference](#)**
  - 23. Setacci C, Argentero A, Cremonesi A, de Donato G, Galzerano G, Lanza G, et al. Guidelines on the diagnosis and treatment of extracranial carotid artery stenosis from the Italian Society for Vascular and Endovascular Surgery. The Journal of cardiovascular surgery. 2014;55(1):119-31. (Guidelines). [View the reference](#)**
  - 24. North American Symptomatic Carotid Endarterectomy Trial Collaborators. Beneficial effect of carotid endarterectomy in symptomatic patients with high-grade carotid stenosis. The New**

- England journal of medicine. 1991;325(7):445-53. (Level I Evidence). [View the reference](#)
25. **European Carotid Surgery Trialists' Collaborative Group. MRC European carotid surgery trial: interim results for symptomatic patients with severe (70-99%) or with mild (0-29%) carotid stenosis. Lancet (London, England). 1991;337(8752):1235-43. (Level II Evidence). [View the reference](#)**
  26. **Mayberg MR, Wilson SE, Yatsu F, Weiss DG, Messina L, Hershey LA, et al. Carotid endarterectomy and prevention of cerebral ischemia in symptomatic carotid stenosis. Veterans affairs cooperative studies program 309 trialist group. Jama. 1991;266(23):3289-94. (Level II Evidence). [View the reference](#)**
  27. **Saam T, Hetterich H, Hoffmann V, Yuan C, Dichgans M, Poppert H, et al. Meta-analysis and systematic review of the predictive value of carotid plaque hemorrhage on cerebrovascular events by magnetic resonance imaging. Journal of the American College of Cardiology. 2013;62(12):1081-91. (Level I Evidence). [View the reference](#)**
  28. **Gupta A, Baradaran H, Schweitzer AD, Kamel H, Pandya A, Delgado D, et al. Carotid plaque MRI and stroke risk: a systematic review and meta-analysis. Stroke; a journal of cerebral circulation. 2013;44(11):3071-7. (Level I Evidence). [View the reference](#)**
  29. **Brinjikji W, Huston J, 3rd, Rabinstein AA, Kim GM, Lerman A, Lanzino G. Contemporary carotid imaging: from degree of stenosis to plaque vulnerability. Journal of neurosurgery. 2016;124(1):27-42. (Review Article). [View the reference](#)**
  30. **Anderson GB, Steinke DE, Petruk KC, Ashforth R, Findlay JM. Computed tomographic angiography versus digital subtraction angiography for the diagnosis and early treatment of ruptured intracranial aneurysms. Neurosurgery. 1999;45(6):1315-20. (Level II Evidence). [View the reference](#)**
  31. **Tomandl BF, Klotz E, Handschu R, Stemper B, Reinhardt F, Huk WJ, et al. Comprehensive imaging of ischemic stroke with multisection CT. Radiographics : a review publication of the Radiological Society of North America, Inc. 2003;23(3):565-92. (Review Article). [View the reference](#)**
  32. **Katz DA, Marks MP, Napel SA, Bracci PM, Roberts SL. Circle of Willis: evaluation with spiral CT angiography, MR angiography, and conventional angiography. Radiology. 1995;195(2):445-9. (Level II Evidence). [View the reference](#)**
  33. **Knauth M, von Kummer R, Jansen O, Hahnel S, Dorfler A, Sartor K. Potential of CT angiography in acute ischemic stroke. AJNR American journal of neuroradiology. 1997;18(6):1001-10. (Level II Evidence). [View the reference](#)**
  34. **Shrier DA, Tanaka H, Numaguchi Y, Konno S, Patel U, Shibata D. CT angiography in the evaluation of acute stroke. AJNR American journal**



- of neuroradiology. 1997;18(6):1011-20. (Level III Evidence). [View the reference](#)
35. Wildermuth S, Knauth M, Brandt T, Winter R, Sartor K, Hacke W. Role of CT angiography in patient selection for thrombolytic therapy in acute hemispheric stroke. *Stroke; a journal of cerebral circulation*. 1998;29(5):935-8. (Level III Evidence). [View the reference](#)
36. Verro P, Tanenbaum LN, Borden NM, Sen S, Eshkar N. CT angiography in acute ischemic stroke: preliminary results. *Stroke; a journal of cerebral circulation*. 2002;33(1):276-8. (Level III Evidence). [View the reference](#)
37. Silvennoinen HM, Ikonen S, Soinnie L, Railo M, Valanne L. CT angiographic analysis of carotid artery stenosis: comparison of manual assessment, semiautomatic vessel analysis, and digital subtraction angiography. *AJNR American journal of neuroradiology*. 2007;28(1):97-103. (Level III Evidence). [View the reference](#)
38. Latchaw RE, Alberts MJ, Lev MH, Connors JJ, Harbaugh RE, Higashida RT, et al. Recommendations for imaging of acute ischemic stroke: a scientific statement from the American Heart Association. *Stroke; a journal of cerebral circulation*. 2009;40(11):3646-78. (Guidelines). [View the reference](#)
39. Johnston DC, Chapman KM, Goldstein LB. Low rate of complications of cerebral angiography in routine clinical practice. *Neurology*. 2001;57(11):2012-4. (Level III Evidence). [View the reference](#)
40. Willinsky RA, Taylor SM, TerBrugge K, Farb RI, Tomlinson G, Montanera W. Neurologic complications of cerebral angiography: prospective analysis of 2,899 procedures and review of the literature. *Radiology*. 2003;227(2):522-8. (Level II Evidence). [View the reference](#)

## Further Reading

1. Barnett HJM, Meldrum HE, Eliasziw M, for the North American Symptomatic Carotid Endarterectomy Trial (NASCET) collaborators. The appropriate use of carotid endarterectomy. *CMAJ*. 2002;166(9):1169-79. (Review article)
2. CAVATAS investigators Endovascular versus surgical treatment in patients with carotid stenosis in the Carotid and Vertebral Artery Transluminal Angioplasty Study (CAVATAS): a randomised trial. *Lancet*. 2001;357:1729-37. (Level II evidence)
3. Barnett HJM, Taylor DW, Eliasziw M, et al, for the North American Symptomatic Carotid Endarterectomy Trial Collaborators. Benefit of carotid endarterectomy in patients with symptomatic moderate or severe stenosis. *N Engl J Med*. 1998;339:1415-25



## Information for Consumers

Information from this website	Information from the Royal Australian and New Zealand College of Radiologists' website
<p><a href="#">Consent to Procedure or Treatment</a></p> <p><a href="#">Radiation Risks of X-rays and Scans</a></p> <p><a href="#">Angiography (Angiogram)</a></p> <p><a href="#">Computed Tomography (CT)</a></p> <p><a href="#">Computed Tomography (CT) Angiography</a></p> <p><a href="#">Magnetic Resonance Angiography (MRA)</a></p> <p><a href="#">Magnetic Resonance Imaging (MRI)</a></p> <p><a href="#">Ultrasound (Doppler)</a></p>	<p><a href="#">Angiography</a></p> <p><a href="#">Computed Tomography (CT)</a></p> <p><a href="#">Contrast Medium (Gadolinium versus Iodine)</a></p> <p><a href="#">Gadolinium Contrast Medium</a></p> <p><a href="#">Iodine-Containing Contrast Medium</a></p> <p><a href="#">Magnetic Resonance Imaging (MRI)</a></p> <p><a href="#">Radiation Risk of Medical Imaging During Pregnancy</a></p> <p><a href="#">Radiation Risk of Medical Imaging for Adults and Children</a></p>

### Copyright

© Copyright 2017, Department of Health Western Australia. All Rights Reserved. This web site and its content has been prepared by The Department of Health, Western Australia. The information contained on this web site is protected by copyright.

### Legal Notice

Please remember that this leaflet is intended as general information only. It is

**not definitive and The Department of Health, Western Australia can not accept any legal liability arising from its use. The information is kept as up to date and accurate as possible, but please be warned that it is always subject to change**

## File Formats

Some documents for download on this website are in a Portable Document Format (PDF). To read these files you might need to download Adobe Acrobat Reader.



[Legal Matters](#)