

# Diagnostic Imaging Pathways - Head Injury (Adult)

## Population Covered By The Guidance

This pathway provides guidance on imaging adults with a recent head injury. The Canadian CT Head Rules have been used to formulate the guideline.

**Date reviewed: May 2018**

**Date of next review: May 2021**






**Published: June 2018**

## Quick User Guide

Move the mouse cursor over the **PINK** text boxes inside the flow chart to bring up a pop up box with salient points.

Clicking on the **PINK** text box will bring up the full text.

The relative radiation level (RRL) of each imaging investigation is displayed in the pop up box.

SYMBOL	RRL	EFFECTIVE DOSE RANGE
	None	0
	Minimal	< 1 millisieverts
	Low	1-5 mSv
	Medium	5-10 mSv
	High	>10 mSv

## Pathway Diagram



Date reviewed: May 2018  
 Please note this pathway is subject to review and revision

Under 16 years:  
 Paediatric Head Trauma Pathway

ADULT WITH ACUTE BLUNT HEAD INJURY

- Any of the following:
- Focal neurological deficit
  - Patients on oral anticoagulants/anti-platelet agents or with a bleeding disorder
  - Obvious depressed skull fracture
  - Any sign of base of skull fracture (haemotympanum, 'raccoon' eyes, CSF otorrhoea/rhinorrhoea, Battle's sign)
  - GCS < 13 at any time since injury
  - Post-traumatic seizure
  - Unstable vital signs with major trauma

History of loss of consciousness, amnesia, or disorientation and injury within the previous 24h

No

No

Yes

- High risk (of abnormality requiring neurosurgical intervention)**
- GCS score < 15 at 2h after injury
  - Suspected open or depressed skull fracture
  - Vomiting two or more times
  - Aged 65 or older
- Medium risk (for demonstrating brain injury on CT not requiring neurosurgical intervention)**
- Retrograde amnesia of more than 30 minutes
  - Dangerous mechanism (pedestrian struck by motor vehicle, occupant ejected from motor vehicle, fall from height of more than 1 metre or five stairs)

Yes

Any high risk factors

Any medium risk factors

No high or medium risk factors

CT Head

CT Head or close observation

Very low risk for significant intracranial injury

Patients may not require CT if they can be monitored for a period following presentation

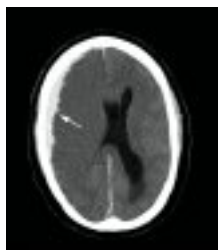Decision to perform imaging should be based on judgement of managing physician

Role of MRI

## Image Gallery

*Note: These images open in a new page*

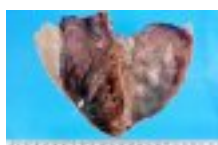1



### Subdural Haematoma

Image 1 (Computed Tomography): Acute post-traumatic right fronto-parietal subdural haematoma with midline shift showing the typical crescent shape (arrow).

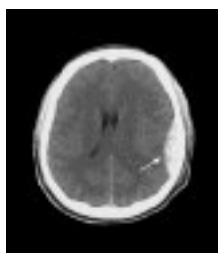
2



### Bilateral Chronic Subdural Haematoma

Image 2 : Post-mortem specimen of the dura matter peeled back to reveal old haematoma within the subdural space (arrow).

3



### Extradural Haematoma

Image 3 (Computed Tomography): Acute traumatic left extradural haematoma (arrow) showing the typical lens or convex shape with compression of the lateral ventricle.

## Teaching Points

- Certain clinical findings mandate urgent CT head - focal neurological deficit, patients on anticoagulation/antiplatelets or suffering with a bleeding diathesis, penetrating skull injury, depressed skull fracture, signs of a base of skull fracture,
- Patients with a history of loss of consciousness (LOC), amnesia/disorientation and a GCS > 13 must be further risk assessed based on clinical findings. The criteria used in this pathway are based on the Canadian CT Head Rule, which is most widely validated clinical decision making tool. Observation or CT head may be indicated
- The decision to perform imaging on patients with no LOC, amnesia or disorientation and GCS 15 should be based on the judgement of the managing physician after history and examination
- Patients who present without loss of consciousness or amnesia are not included by the Canadian CT Head rule, but there is evidence that there is still a risk of intracranial injury if other risk factors from the rule are present

## Computed Tomography (CT) Head

- Generally considered the most appropriate first line investigation for patients with head injury [1](#)
- Is able to detect scalp, bone, extra-axial haematomas and parenchymal injuries [2](#)
- There have been a number of guidelines developed for the use of CT in head injury with various recommendations. The Canadian CT Head Rule is generally considered the best of these guidelines [3](#)
- Although skull radiographs have been historically advocated as a first line investigation, they are now rarely used because of the lack of correlation between a skull fracture and a significant intracranial haematoma [4, 5](#)
- As CT is widely available and relatively inexpensive many hospitals are now using CT as a means of rapidly determining those patients with minor head injuries who can be safely discharged versus those who need admission or neurosurgical opinion [6, 9](#)
- There have been some reported cases of patients who have had a normal head CT and subsequently developed an intracranial haematoma. [10, 11](#) The evidence in the literature suggests that the probability of life-threatening complications after a normal CT is minimal. [12, 13](#) Clinical caution should be exercised in those on anticoagulation/antiplatelet agents which are associated with increased risk of developing intracranial haemorrhage following trauma [14, 15](#)
- Patients who present without loss of consciousness or amnesia are not included by the Canadian CT Head rule, but there is evidence that there is still a risk of intracranial injury if other risk factors from the rule are present. [16](#) The incidence of intracranial injury in patients with GCS 15 has been reported from 1.6% to 7.5% [17, 18](#)
- The decision to perform imaging on patients with no LOC, amnesia or disorientation and GCS 15 should be based on the judgement of the managing physician after history and examination [19](#)

## Canadian CT Head Rule

- The Canadian CT Head Rule (CCHR) was prospectively derived on 3121 patients who had a minor head injury, defined as a GCS of 13 or greater with witnessed loss of consciousness, disorientation or definite amnesia [3, 20, 21](#)
- The authors found that patients with minor head injury could be classified into two levels of risk. Those with one of the five high risk factors are at substantial risk for neurosurgical intervention and CT is considered mandatory in these cases [3, 20, 21](#)
- Patients with either of the two medium risk characteristics could have a clinically important brain injury that would be seen on CT but are not at risk for needing neurosurgical intervention. The authors concluded that these patients could be managed with CT or close observation depending on local resources [3, 20, 21](#)
- Prospective validation was carried out in Canada and reported a sensitivity of 100% and a specificity of 52.1% for clinically important brain injury [22](#)
- External validation of the Canadian CT Head Rule has been disappointing. A Dutch study of 3181 consecutive patients reported a sensitivity of 100% for predicting neurosurgical intervention, but a sensitivity of only 84.5% for clinically important brain injury. Similarly, a retrospective study of 240 patients in Australia found that two, of ten clinically important, brain injuries would have been missed if the Canadian CT Head Rule had been applied [23, 24](#)
- The CCHR has been found to perform variably better than the New Orleans Criteria (NOC) in trials that have compared the two depending on what particular accuracy measure was analysed. [25, 26](#) In an external validation of the CCHR and the NOC, the CCHR was found to have a lower sensitivity than the NOC for neurocranial or clinically important CT findings [23](#)
- Despite this the CCHR remains the most widely researched decision rule and compared to other decision rules remains the most widely validated combined with high sensitivity and acceptable specificity [27, 28](#)
- The NICE Head Injury Guidelines (National Collaborating Centre for Acute Care - National Institute of Clinical Excellence) also recommends CT imaging for patients with post-traumatic seizure or a

GCS of less than 13 at any time since injury [1, 29](#)

- A recent Austrian trial found that by using different parameters to that of the CCHR for the assessment of high-risk patients sustaining mild head trauma a better sensitivity was achieved 90% versus 80 %. External multi centre validation is required to assess the results of this trial better [2](#)

## Magnetic Resonance Imaging (MRI)

- May be used in the subacute setting to evaluate patients with unexplained neurological deficits
- MRI is superior to CT in identifying diffuse axonal or shear injury and small intraparenchymal contusions [30, 31](#)
- Magnetic resonance angiography may be used in some patients to assess for arterial injury or venous sinus occlusion
- Disadvantages
  - Insensitive to acute subarachnoid or parenchymal haemorrhage, and fracture compared with CT [2, 30](#)
  - Limited role in the acute setting due to long acquisition times and difficulty in performing a scan of the critically ill patient who may require life support systems
  - Certain absolute contra- indications; e.g. pacemaker

## References

**Date of literature search: December 2017 - April 2018**

References are graded from Level I to V according to the Oxford Centre for Evidence-Based Medicine, Levels of Evidence. [Download the document](#)

- 1. National Institute for Health and Care Excellence (UK). National institute for health and clinical excellence: guidance. Head injury: triage, assessment, investigation and early management of head injury in children, young people and adults.** London: National Clinical Guideline Centre; 2014. Guideline. [View the reference](#)
- 2. Besenski N. Traumatic injuries: imaging of head injuries.** Eur Radiol. 2002;12(6):1237-52. (Review article). [View the reference](#)
- 3. Stiell IG, Wells GA, Vandemheen K, Clement C, Lesiuk H, Laupacis A, et al. The Canadian CT head rule for patients with minor head injury.** Lancet. 2001;357(9266):1391-6. (Level II evidence). [View the reference](#)
- 4. Teasdale GM, Murray G, Anderson E, Mendelow AD, MacMillan R, Jennett B, et al. Risks of acute traumatic intracranial haematoma in children and adults: implications for managing head injuries.** BMJ. 1990;300(6721):363-7. (Level II evidence). [View the reference](#)
- 5. Alcala Minagorre PJ, Aranaz Andres J, Flores Serrano J, Asensio Garcia L, Herrero Galiana A. Diagnostic utility of radiography in head trauma: a critical review of the literature.** Anales de pediatria (Barcelona, Spain : 2003). 2004;60(6):561-8. (Review article). [View the reference](#)
- 6. Abdul Rahman YS, Al Den AS, Maull KI. Prospective study of validity of neurologic signs in predicting positive cranial computed tomography following minor head trauma.** Prehosp Disaster Med. 2010;25(1):59-62. (Level III evidence). [View the reference](#)
- 7. Holmes JF, Baier ME, Derlet RW. Failure of the Miller criteria to predict significant intracranial injury in patients with a Glasgow coma scale score of 14 after minor head trauma.** Acad Emerg Med. 1997;4(8):788-92. (Level II evidence). [View the reference](#)
- 8. Livingston DH, Loder PA, Hunt CD. Minimal head injury: is admission necessary?** Am Surg.



- 1991;57(1):14-7. (Level III evidence). [View the reference](#)
9. Shackford SR, Wald SL, Ross SE, Cogbill TH, Hoyt DB, Morris JA, et al. **The clinical utility of computed tomographic scanning and neurologic examination in the management of patients with minor head injuries.** J Trauma. 1992;33(3):385-94. (Level III evidence). [View the reference](#)
  10. Deitch D, Kirshner HS. **Subdural hematoma after normal CT.** Neurology. 1989;39(7):985-7. (Level IV evidence). [View the reference](#)
  11. Snoey ER, Levitt MA. **Delayed diagnosis of subdural hematoma following normal computed tomography scan.** Ann Emerg Med. 1994;23(5):1127-31. (Level IV evidence). [View the reference](#)
  12. Isokuortti H, Luoto TM, Kataja A, Brander A, Siironen J, Liimatainen S, et al. **Necessity of monitoring after negative head CT in acute head injury.** Injury. 2014:1340-4. (Level II evidence). [View the reference](#)
  13. Livingston DH, Lavery RF, Passannante MR, Skurnick JH, Baker S, Fabian TC, et al. **Emergency department discharge of patients with a negative cranial computed tomography scan after minimal head injury.** Ann Surg. 2000;232(1):126-32. (Level II evidence). [View the reference](#)
  14. Levine M, Wyler B, Lovecchio F, Roque P, Raja AS. **Risk of intracranial injury after minor head trauma in patients with pre-injury use of clopidogrel.** Am J Emerg Med. 2014;32(1):71-4. (Level III evidence). [View the reference](#)
  15. Batchelor JS, Grayson A. **A meta-analysis to determine the effect of preinjury antiplatelet agents on mortality in patients with blunt head trauma** Br J Neurosurg. 2013;27(1):12-8. (Level II evidence). [View the reference](#)
  16. Easter JS, Haukoos JS, Meehan WP, Novack V, Edlow JA. **Will neuroimaging reveal a severe intracranial injury in this adult with minor head trauma?: The rational clinical examination systematic review.** JAMA. 2015;314(24):2672-81. (Level I evidence). [View the reference](#)
  17. Ono K, Wada K, Takahara T, Shirotani T. **Indications for computed tomography in patients with mild head injury.** Neurol Med Chir (Tokyo). 2007;47(7):291-7; discussion 7-8. (Level II evidence). [View the reference](#)
  18. Smits M, Hunink MGM, Nederkoorn PJ, Dekker HM, Vos PE, Kool DR, et al. **A history of loss of consciousness or post-traumatic amnesia in minor head injury: “conditio sine qua non” or one of the risk factors?** Journal of Neurology, Neurosurgery, and Psychiatry. 2007;78(12):1359-64. (Level II evidence). [View the reference](#)
  19. Royal Australian and New Zealand College of Radiologists. **Adult head trauma.** 2015. (Guideline). [View the reference](#)
  20. Stiell IG, Lesiuk H, Wells GA, McKnight RD, Brison R, Clement C, et al. **The Canadian CT head rule study for patients with minor head injury: rationale, objectives, and methodology for phase I (derivation).** Ann Emerg Med. 2001;38(2):160-9. (Methodology article). [View the reference](#)
  21. Stiell IG, Lesiuk H, Wells GA, Coyle D, McKnight RD, Brison R, et al. **Canadian CT head rule study for patients with minor head injury: methodology for phase II (validation and economic analysis).** Ann Emerg Med. 2001;38(3):317-22. (Methodology article). [View the reference](#)
  22. Stiell IG, Clement CM, Rowe BH, Schull MJ, Brison R, Cass D, et al. **Comparison of the Canadian CT head rule and the New Orleans criteria in patients with minor head injury.** JAMA. 2005;294(12):1511-8. (Level I evidence). [View the reference](#)
  23. Smits M, Dippel DW, de Haan GG, Dekker HM, Vos PE, Kool DR, et al. **External validation of the Canadian CT head rule and the New Orleans Criteria for CT scanning in patients with minor head injury.** JAMA. 2005;294(12):1519-25. (Level I evidence). [View the reference](#)
  24. Rosengren D, Rothwell S, Brown AF, Chu K. **The application of North American CT scan criteria to an Australian population with minor head injury.** Emerg Med Australas. 2004;16(3):195-200. (Level IV evidence). [View the reference](#)



25. Kavalci C, Aksel G, Salt O, Yilmaz MS, Demir A, Kavalci G, et al. **Comparison of the Canadian CT head rule and the new orleans criteria in patients with minor head injury.** World J Emerg Surg. 2014;9:31. (Level III evidence). [View the reference](#)
26. Papa L, Stiell IG, Clement CM, Pawlowicz A, Wolfram A, Braga C, et al. **Performance of the Canadian CT head rule and the New Orleans criteria for predicting any traumatic intracranial injury on computed tomography in a United States level I trauma center.** Acad Emerg Med. 2012;19(1):2-10. (Level III evidence). [View the reference](#)
27. Harnan SE, Pickering A, Pandor A, Goodacre SW. **Clinical decision rules for adults with minor head injury: a systematic review.** J Trauma. 2011;71(1):245-51. (Level I evidence). [View the reference](#)
28. Pandor A, Goodacre S, Harnan S, Holmes M, Pickering A, Fitzgerald P, et al. **Diagnostic management strategies for adults and children with minor head injury: a systematic review and an economic evaluation.** Health Technol Assess. 2011;15(27):1-202. (Level I evidence). [View the reference](#)
29. Bruce DA. **Imaging after head trauma: why, when and which.** Childs Nerv Syst. 2000;16(10-11):755-9. (Review article). [View the reference](#)
30. Orrison WW, Gentry LR, Stimac GK, Tarrel RM, Espinosa MC, Cobb LC. **Blinded comparison of cranial CT and MR in closed head injury evaluation.** AJNR Am J Neuroradiol. 1994;15(2):351-6. (Level II evidence). [View the reference](#)
31. Mittl RL, Grossman RI, Hiehle JF, Hurst RW, Kauder DR, Gennarelli TA, et al. **Prevalence of MR evidence of diffuse axonal injury in patients with mild head injury and normal head CT findings.** AJNR Am J Neuroradiol. 1994;15(8):1583-9. (Level III evidence). [View the reference](#)

## Information for Consumers

Information from this website	Information from the Royal Australian and New Zealand College of Radiologists' website
<p><a href="#">Consent to Procedure or Treatment</a></p> <p><a href="#">Radiation Risks of X-rays and Scans</a></p> <p><a href="#">Computed Tomography (CT)</a></p> <p><a href="#">Magnetic Resonance Imaging (MRI)</a></p>	<p><a href="#">Computed Tomography (CT)</a></p> <p><a href="#">Magnetic Resonance Imaging (MRI)</a></p> <p><a href="#">Radiation Risk of Medical Imaging During Pregnancy</a></p> <p><a href="#">Radiation Risk of Medical Imaging for Adults and Children</a></p>

## Copyright

© Copyright 2018, Department of Health Western Australia. All Rights Reserved. This web site and its content has been prepared by The Department of Health, Western Australia. The information contained on this web site is protected by copyright.

## Legal Notice

Please remember that this leaflet is intended as general information only. It is not definitive and The Department of Health, Western Australia can not accept any legal liability arising from its use. The information is kept as up to date and accurate as possible, but please be warned that it is always subject to change

## File Formats

Some documents for download on this website are in a Portable Document Format (PDF). To read these files you might need to download Adobe Acrobat Reader.



## [Legal Matters](#)