

# Diagnostic Imaging Pathways - Thoracic Aorta Blunt Trauma

## Population Covered By The Guidance

This pathway provides guidance on the imaging of adult patients at risk of aortic injury following blunt trauma.

**Date reviewed: December 2018**

**Date of next review: December 2021**






**Published: July 2019**

## Quick User Guide

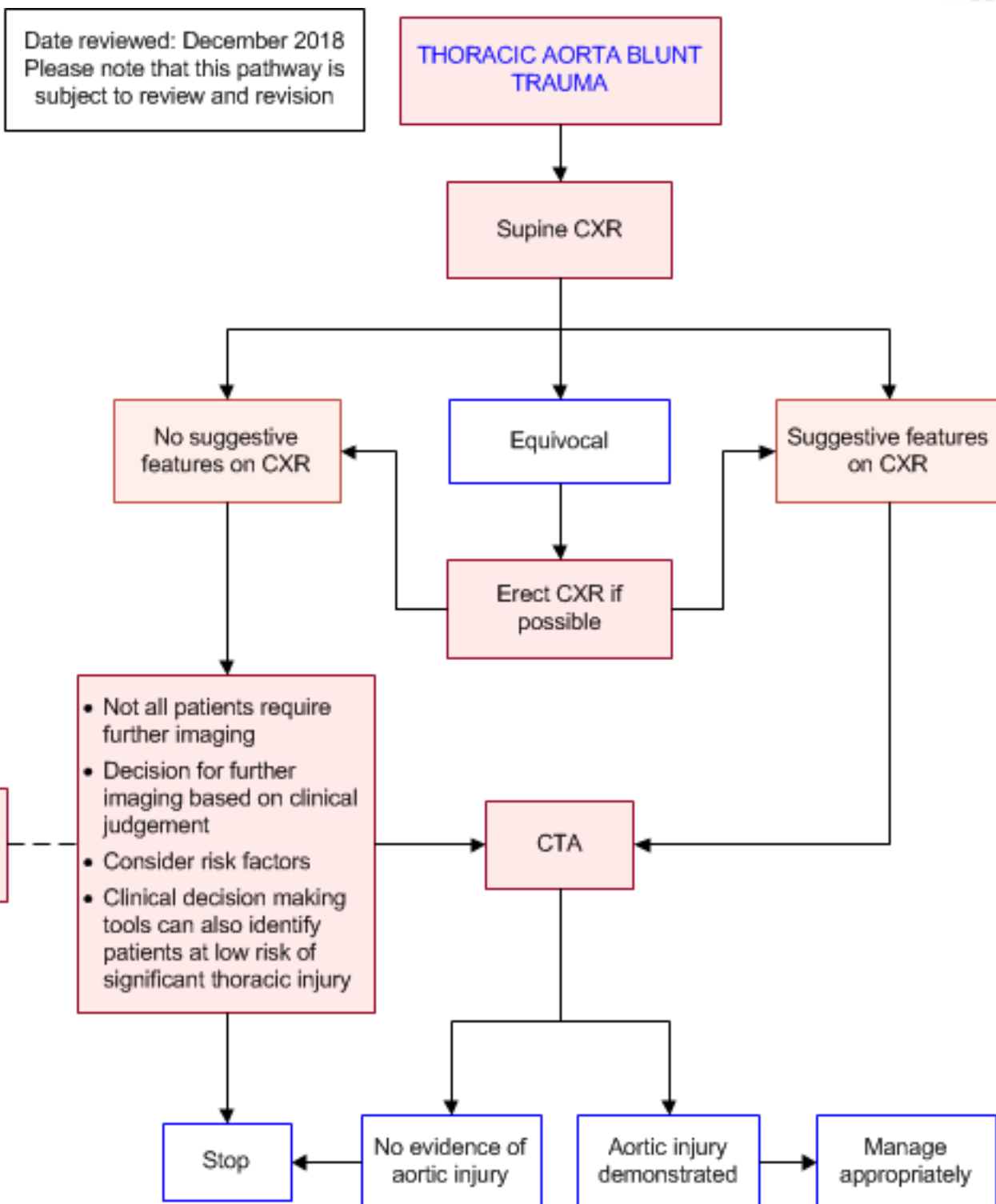
Move the mouse cursor over the **PINK** text boxes inside the flow chart to bring up a pop up box with salient points.

Clicking on the **PINK** text box will bring up the full text.

The relative radiation level (RRL) of each imaging investigation is displayed in the pop up box.

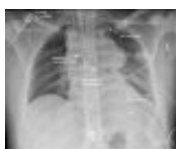SYMBOL	RRL	EFFECTIVE DOSE RANGE
	None	0
	Minimal	< 1 millisieverts
	Low	1-5 mSv
	Medium	5-10 mSv
	High	>10 mSv

## Pathway Diagram



## Image Gallery

Note: These images open in a new page 1



### Blunt Thoracic Aortic Injury

Image 1 (Chest radiography): The classical radiographic signs of a traumatic disruption of the aorta are shown including a widened mediastinum, depressed left main bronchus and left apical cap.

## 2a Blunt Thoracic Aortic Injury

Image 2a, 2b and 2c (CT Angiography): Evidence of an intimal flap and full-thickness rupture of the thoracic aorta at the level of the aortic isthmus (arrows). Subcutaneous emphysema is seen bilaterally with contusions to the left lung.

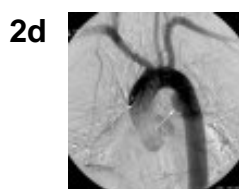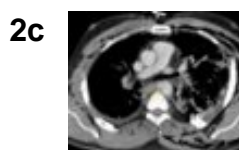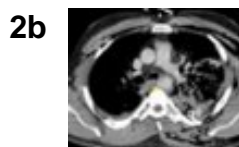
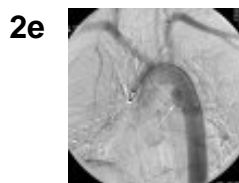


Image 2d and 2e (Aortography): Aortic rupture is confirmed by evidence of delayed contrast flow in the region of the aortic isthmus (arrow) which is best seen in image 2e, where the area of injury retains contrast and appears darker compared to the rest of the aorta.



## Teaching Points

- Blunt thoracic aortic injuries are rare but catastrophic. Presentation can be variable so a high index of suspicion is required
- Contrast-enhanced CT is the definitive investigation for the diagnosis and exclusion of thoracic aortic injury, however it is not necessarily required in all patients with blunt chest trauma
- The initial screening tool for blunt thoracic trauma is a chest radiograph, which may not exclude blunt thoracic aortic injury but may demonstrate other life-threatening injuries. CXR is complementary to more definitive imaging studies
- Although new abnormalities on CXR are not specific for aortic injury, findings should be followed up with CT
- In patients with a normal or equivocal CXR, the decision to proceed to CT should be based on clinical judgement, taking into account the mechanism of injury, patient factors, clinical findings, results of other investigations and disposition
- Invasive aortography is generally reserved for therapeutic purposes

## Thoracic Aorta Blunt Trauma

- Common cause of fatalities at the scene of the accident. Prompt diagnosis and treatment are essential on admission in survivors [1-4](#)
- Over 90% of injuries occur at the aortic isthmus. Most of the rest occur in proximal ascending aorta [1-4](#)
- Prompt diagnosis depends on the level of clinical suspicion and imaging [1-4](#)
- Usual mechanism of injuries include sudden deceleration or crush injuries to the chest causing shearing or bending forces to thoracic aorta, [1-4](#) such as high-speed road trauma >60km/h or falls from height

## Plain Radiography (CXR)

- Initial screening study for evaluation of blunt thoracic trauma [4-7](#)
- In the context of blunt trauma where there is concern for spinal injuries, this is usually supine
- CXR alone is generally not considered sufficient to exclude aortic injury [8](#) but it is rapidly available and is complementary to more definitive studies. [9](#) Other injuries requiring immediate management such as haemothorax and tension pneumothorax are readily demonstrated on CXR [10](#)
- Findings on CXR can be suggestive of mediastinal haematoma, however it is not a specific sign. Mediastinal haematoma in trauma can be due to venous bleeding or an adjacent spine or sternal fracture, with one study reporting only 3% of positive or equivocal CXR findings representing traumatic aortic injury [11](#)
- Although CXR findings are not specific for aortic injury and there is a large proportion of false positives, proceeding to CTA is indicated if suggestive features are present [6,12,13](#)
- Features suggestive of mediastinal haematoma on CXR include: [4,5,14](#)
  - mediastinal widening (>8cm when supine or >6cm when upright)
  - obscuration of aortic arch margin
  - deviation of trachea to the right
  - deviation of nasogastric tube to the right
  - depressed left main bronchus
  - loss of aorto-pulmonary window
  - widening of paraspinal stripes
  - left apical cap, left haemothorax
- Aortic injury may be directly suggested by:
  - irregularity or blurring of the aortic knob contour
  - aortic knob enlargement
- Blunt aortic injuries are also associated with: [14](#)
  - first or second rib fractures
  - clavicle, sternal or thoracic spine fractures
- A combination of signs is more reliable than a single sign [4](#)
- Some studies have demonstrated good negative predictive value of specific CXR signs, [12,15](#) however, CXR alone does not have sufficient sensitivity to rule out traumatic aortic injury
  - Other studies have reported that up to two-thirds of patients with blunt aortic injury may have no mediastinal abnormalities on CXR, even after focussed re-review [10,16](#)
- Erect PA CXRs are superior to portable AP CXRs for imaging the mediastinum [17,18](#) and this should be performed where possible, such as in stable patients where supine and/or AP images have been equivocal
  - In the trauma setting, often only supine AP CXRs are possible which makes the assessment of the mediastinum less accurate

## Risk Factors for Blunt Thoracic Aortic Injury

- Currently, the decision to proceed to CT must be based on clinical judgement, taking into account the mechanism of injury, patient risk factors, clinical signs and symptoms, CXR findings, other investigations and disposition
- It is widely accepted that the majority of blunt aortic injuries are caused by high energy mechanisms with rapid deceleration of the thorax, including motor vehicle crashes, pedestrian vs car, falls and crush injuries. [19-25](#) Overall, blunt aortic injury is uncommon, occurring only in approximately 1% of all vehicular high-speed accidents [23](#)
  - Similarly, an association has been found with long-bone [26](#) and pelvic fractures [26-28](#)

## Selective chest CT

- Although the use of chest CT is now widespread, there is disagreement on whether chest CT should be routinely performed in all patients with a history of blunt trauma [29,30](#)
- Most authors recommend in high clinical suspicion for blunt thoracic aortic injury, [22,31,32](#) however the variable presentation of injuries makes it challenging to determine which patients require CT [9,23,33,34](#)
  - Several studies have found clinical signs and symptoms to be unreliable for ruling out blunt thoracic aortic injury. A third to half of patients may have minimal or no external signs of chest trauma [35,36](#)
  - Half of patients with blunt thoracic aortic injury may have normal vital signs at presentation, [34,37](#) potentially leading to a delay in diagnosis
  - A prospective study found that clinicians' suspicion for any blunt chest injury did not strongly correlate with the presence of injury on subsequent CXR, suggesting that subjective assessment alone does not always reliably determine the need for imaging [38](#)
- Fear of missing potentially life-threatening injuries has led to increased use of chest CT, including as part of the "pan scan", however this approach has its disadvantages, including:
  - Increased risk of radiation-induced cancer, particular in young populations [30,39](#)
  - Increased cost [30](#)
  - Increased time in emergency departments [40](#)
  - No increase in the number of detected life-threatening injuries, despite routine CT use. [40](#) A number of studies have reported that routine chest CT rarely identifies injuries that would have changed management. [41-43](#) Common occult injuries detected on CT include small pulmonary contusions, rib fractures and small pneumothoraces not requiring chest drain insertion
- Many guidelines recommend against the excessive use of CT when it is not warranted, however there are no specific criteria [7,32,44](#)

## Increasing the efficiency of CT use

- Observational studies have identified features that were significantly associated with significant thoracic injuries requiring intervention, including thoracic aortic injuries. A number of authors have attempted to define clinical decision making tools that identify patients at low risk of thoracic injury in blunt chest trauma, using a combination of clinical findings, mechanism of injury and CXR findings
  - Use of these rules aims to reduce the number of normal chest CTs performed
- These clinical decision rules are yet to be externally validated
- A limitation of these studies is that they do not identify whether CT findings change management



compared with CXR findings alone

- Currently, there are no clinical decision rules to identify which patients, with injuries on CXR, will not benefit from additional CT
- Kaiser et al found a number of factors increased the likelihood of occult CT findings in patients with normal CXR: [45](#)
  - Abbreviated injury score of 3 or more
  - Pelvic or extremity abbreviated injury score of 2 or more
  - Age over 30 years
  - Male sex

## Clinical decision rules to predict clinically significant injury on chest CT

Clinical decision rule	Derivation population	Criteria	Implication	Accuracy
Traumatic aortic injury score (TRAINS) <a href="#">26</a>	Derivation cohort n = 1380. Validation cohort n = 260.	1. Widened mediastinum = 4 2. Injury severity score >15 3. Hypotension 14 years, blunt trauma within 6h of ED presentation	1. Abnormal CXR 2. Distracting injury 3. Chest wall tenderness 4. Sternum tenderness 5. Thoracic spine tenderness 6. Scapula tenderness 7. (Chest CT-All only) Rapid deceleration mechanism (fall from >6m, motor vehicle crash >40mph or 64km/h with sudden deceleration)	2. If all criteria are absent may forego CT. If one or more criteria present, cannot exclude thoracic injury but does not indicate need for chest CT - presence of one criterion is associated with prevalence of major clinical injury of 1.9-3.8% <a href="#">31</a>
SCRAP rule <a href="#">48</a>	Derivation cohort n = 434. Validation cohort n = 180.	GCS >8, age ?16 years, Injury Severity Score >12, no paralysis with blunt chest injury		