

Diagnostic Imaging Pathways - Abdominal Plain X-Ray (Indications)

Population Covered By The Guidance

This pathway provides guidance on the indications for a plain abdominal radiograph in adult patients.

Date reviewed: September 2018

Date of next review: September 2021






Published: March 2019

Quick User Guide

Move the mouse cursor over the **PINK** text boxes inside the flow chart to bring up a pop up box with salient points.

Clicking on the **PINK** text box will bring up the full text.

The relative radiation level (RRL) of each imaging investigation is displayed in the pop up box.

SYMBOL	RRL	EFFECTIVE DOSE RANGE
	None	0
	Minimal	< 1 millisieverts
	Low	1-5 mSv
	Medium	5-10 mSv
	High	>10 mSv

Pathway Diagram

Date reviewed: September 2018
Please note that this pathway is
subject to review and revision

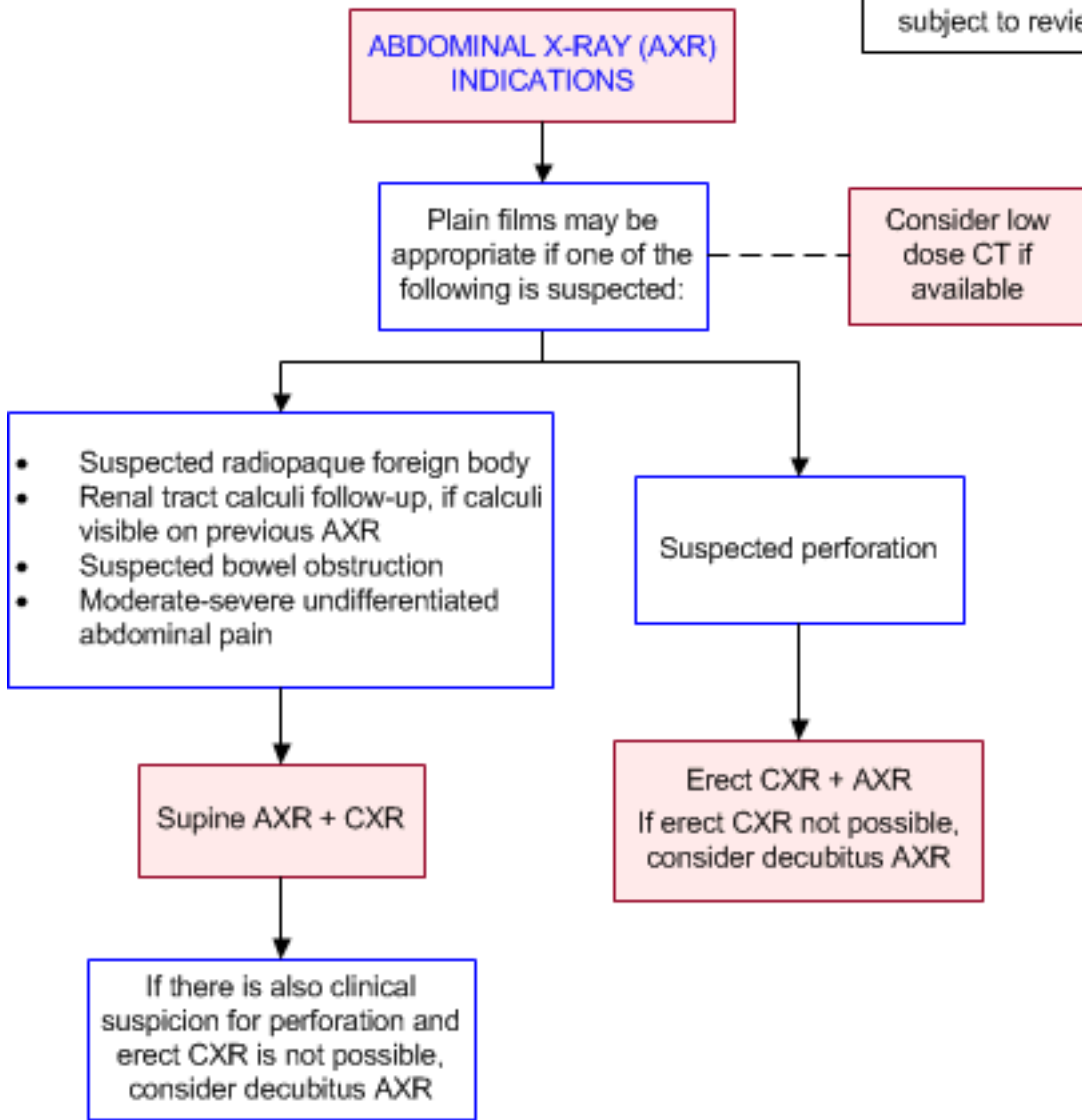


Image Gallery

Note: Images coming soon

Teaching Points

- Plain films may be appropriate for evaluation of:
 - A suspected radiopaque foreign body
 - Renal tract calculi for follow-up, if calculi have been visible on previous radiographs
 - Suspected bowel obstruction
 - Suspected perforation
 - Moderate-severe undifferentiated abdominal pain
- If logistics allow, low-dose non-enhanced CT should be performed for moderate-severe undifferentiated abdominal pain as considerably more diagnostic information can be obtained with

very little increase in dose

Indications for Plain Abdominal Radiograph (AXR)

- The current utility of AXR is debated [1](#)
- Recommendations for radiography: [2](#)
 - Avoid radiography for conditions unlikely to be associated with radiographic signs
 - Avoid radiography in women of reproductive age group, unless a strong indication exists, and only after pregnancy has been excluded
 - Avoid radiography where it will not lead to a change in management
 - If radiography is indicated, request only a supine abdomen or a supine abdomen and erect chest radiograph (or decubitus AXR if this is not possible). A complementary view, such as erect an AXR, is to be requested only after reviewing the initial film
- Several studies have demonstrated the overuse of AXRs [3-5](#) and that the use of guidelines can significantly reduce the number of AXRs performed without missing diagnoses [6,7](#)
- AXRs are low-yield [1](#)
 - A prospective study by Thomas et al showed that about 77% films were normal, increasing to 84% if unrelated or unsuspected findings were considered [8](#)
 - Even 25 years later, Kellow et al (2008), in their retrospective study of 874 patients presenting to the Emergency Department, showed that 81% had normal or non-specific abdominal radiograph results [9](#)
- AXRs infrequently change management
 - A cohort study of 1021 patients found that AXR resulted in a change to a correct diagnosis in only 4% of patients, and increased diagnostic confidence in only a third of unchanged diagnoses [10](#)
 - In their review of 277 cases, Lee showed that plain abdominal radiographs were not helpful in 57% and were misleading in another 1% [11](#)
- Plain abdominal radiographs have little or no role in diagnosis or further investigation of gastrointestinal haemorrhage, peptic ulcer, appendicitis, urinary tract infection or non-specific abdominal pain [1,7,8,12-15](#)
- Other circumstances:
- **Foreign bodies:** AXR is sensitive and specific for foreign bodies dependent on their nature; AXR should only performed where the foreign body has clinical relevance, such as being poisonous, sharp or otherwise symptomatic. [15](#) AXR may also be used to check the position of abdominal catheters [9](#)
- **Small bowel obstruction (SBO):** AXR has traditionally been the first imaging investigation but evidence for its value is variable [16](#)
 - Some studies report accuracy approaching 80-90%, [17,18](#) similar to CT, [19](#) while others reported AXR to be of little or no help; [20,21](#) one study found AXR to be misleading in 20-40% of patients [22](#)
 - Although AXR may have a relative high accuracy for detecting SBO, CT provides much more information about the site, cause and complications of SBO, so AXR is unlikely to be definitive. In suspected SBO patients, AXR may just prolong the evaluation period while adding radiation exposure [1,16](#)
 - Some guidelines suggest that SBO may be an indication for AXR [6,19,23-26](#), while others suggest that AXR may be of more use to monitor the evolution of obstruction [1](#)
- **Urolithiasis:** Low-dose non-contrast CT is usually more appropriate to evaluate patients with suspected ureteric colic, however in a patient with recurrent symptoms, if a stone can be seen on AXR of the kidneys, ureters and bladder (KUB) then a repeat KUB might provide information at a much lower dose. [27](#) KUB may also be useful to follow up patients after lithotripsy [28](#)



- **Moderate-severe undifferentiated abdominal pain:** AXR may be appropriate in acute non-localised abdominal pain. [29](#) As previously mentioned, studies suggest that AXR in undifferentiated abdominal pain rarely changes management [10](#) and does not change the accuracy of clinical diagnosis. [30,31](#) Two studies have shown that low-dose CT can provide better clinical information than abdominal radiographs with as little as twice the radiation dose of AXR, without contrast [30,32](#)
- **Perforation:** reported sensitivities range from 15% [10](#) to 85%; [33](#) lack of free air on plain radiography does not rule out perforation. [34](#) A number of guidelines suggest that AXR is appropriate to evaluate suspected perforation. [23,26,33,35](#) Alternatively, CT is more sensitive and also gives information about the location and cause which are relevant for planning a surgical approach so in the review by Artigas Martin et al, AXR was not recommended to evaluate suspected perforation [1](#)
- **Trauma:** The use of AXR in trauma has been mostly replaced by the Focussed Assessment with Sonography for Trauma (FAST) scan, although plain radiography may still be used when this is not available [36](#)
- **Constipation:** There is a paucity of evidence addressing the role of AXR in adults with constipation. [37](#) A small cross-sectional study failed to show a strong correlation between radiographic and clinical constipation scores [38](#)

Erect Chest Radiograph (CXR)

- A retrospective study of 250 surgically confirmed cases of hollow organ perforation found the sensitivity of erect CXR to be 85.1% compared to 80.4% for supine AXR and 98.0% for left decubitus AXR for the detection of pneumoperitoneum, though neither difference reached statistical significance [33](#)
- Lateral decubitus AXR should be considered to evaluate for perforation if erect CXR is not possible
- Reported sensitivities of AXR for perforation range from 15% [10](#) to 85%; [33](#) lack of free air on plain radiography does not rule out perforation. [34](#) A number of guidelines suggest that AXR is appropriate to evaluate suspected perforation. [23,26,33,35](#) Alternatively, CT is more sensitive and also gives information about the location and cause which are relevant for planning a surgical approach so in the review by Artigas Martin et al, AXR was not recommended to evaluate suspected perforation [1](#)

Low-Dose Computed Tomography (LDCT)

- Several studies have validated the feasibility of non-enhanced LDCT as an alternative to AXR
- LDCT protocols have achieved doses as low as the dose of two or three abdominal radiograph series [30,32,39](#) and more recently Alshamari et al achieved an effective LDCT dose of 1.2mSv, which was comparable to 1.0mSv for AXR. [40](#) One study found that patients who underwent AXR had more subsequent AXRs which resulted in similar total radiation doses for both strategies, even when initial LDCT dose was higher [30](#)
- Compared to AXR, LDCT gave more correct diagnoses [30,32](#) and demonstrated superior sensitivity and positive predictive value [39,40](#)
- LDCT with dose less than 2.5mSv was found to have comparable accuracy to standard-dose CT, though obese patients may still require larger doses to achieve adequate diagnostic images [41](#)
- Although evidence suggests that LDCT provides higher diagnostic yield at comparable doses to AXR, logistical factors such as availability of CT scanners and reporting expertise may prevent AXR from being replaced by LDCT
- Where logistics allow, non-enhanced LDCT is recommended in place of AXR for the evaluation of

moderate-severe undifferentiated abdominal pain. AXR has been found to have low value in this setting [10,30,31](#)

References

References are graded from Level I to V according to the Oxford Centre for Evidence-Based Medicine, Levels of Evidence. [Download the document](#)

1. Artigas Martin JM, Marti de Gracia M, Rodriguez Torres C, Marquina Martinez D, Parrilla Herranz P. **Routine abdominal x-rays in the emergency department: a thing of the past?** Radiologia. 2015;57(5):380-90. (Review article). [View the reference](#)
2. Greene CS. **Indications for plain abdominal radiography in the emergency department.** Ann Emerg Med. 1986;15(3):257-60. (Review article). [View the reference](#)
3. Karkhanis S, Medcalf J. **Plain abdomen radiographs: the right view?** Eur J Emerg Med. 2009;16(5):267-70. (Level III evidence). [View the reference](#)
4. Morris-Stiff G, Stiff RE, Morris-Stiff H. **Abdominal radiograph requesting in the setting of acute abdominal pain: temporal trends and appropriateness of requesting.** Ann R Coll Surg Engl. 2006;88(3):270-4. (Level II evidence). [View the reference](#)
5. Wakai A. **Plain abdominal radiographs in acute medical emergencies: an abused investigation?** Postgrad Med J. 2002;78(925):698-9. (Level II evidence). [View the reference](#)
6. Eisenberg RL, Heineken P, Hedgcock MW, Federle M, Goldberg HI. **Evaluation of plain abdominal radiographs in the diagnosis of abdominal pain.** Ann Surg. 1983;197(4):464-9. (Level II evidence). [View the reference](#)
7. Jelinek GA, Banham ND. **Reducing the use of plain abdominal radiographs in an emergency department.** Arch Emerg Med. 1990;7(4):241-5. (Level II evidence). [View the reference](#)
8. McCook TA, Ravin CE, Rice RP. **Abdominal radiography in the emergency department: a prospective analysis.** Ann Emerg Med. 1982;11(1):7-8. (Level II evidence). [View the reference](#)
9. Kellow ZS, MacInnes M, Kurzenecwyg D, Rawal S, Jaffer R, Kovacina B, et al. **The role of abdominal radiography in the evaluation of the nontrauma emergency patient.** Radiology. 2008;248(3):887-93. (Level III evidence). [View the reference](#)
10. van Randen A, Lameris W, Luitse JS, Gorzeman M, Hesselink EJ, Dolmans DE, et al. **The role of plain radiographs in patients with acute abdominal pain at the ED.** Am J Emerg Med. 2011;29(6):582-9.e2. (Level III evidence). [View the reference](#)
11. Lee PW. **The plain x-ray in the acute abdomen: a surgeon's evaluation.** Br J Surg. 1976;63(10):763-6. (Level III evidence). [View the reference](#)
12. Anyanwu AC, Moalypour SM. **Are abdominal radiographs still overutilized in the assessment of acute abdominal pain? A district general hospital audit.** J R Coll Surg Edinb. 1998;43(4):267-70. (Level III evidence). [View the reference](#)
13. Campbell JP, Gunn AA. **Plain abdominal radiographs and acute abdominal pain.** Br J Surg. 1988;75(6):554-6. (Level III evidence). [View the reference](#)
14. Brewer BJ, Golden GT, Hitch DC, Rudolf LE, Wangenstein SL. **Abdominal pain. An analysis of 1,000 consecutive cases in a university hospital emergency room.** Am J Surg. 1976;131(2):219-23. (Level II evidence). [View the reference](#)
15. Gans SL, Stoker J, Boermeester MA. **Plain abdominal radiography in acute abdominal pain; past, present, and future.** International Journal of General Medicine. 2012;5:525-33. (Review article). [View the reference](#)
16. **ACR appropriateness criteria suspected small-bowel obstruction.** 2013. (Guideline). [View the reference](#)
17. Fukuya T, Hawes DR, Lu CC, Chang PJ, Barloon TJ. **CT diagnosis of small-bowel obstruction: efficacy in 60 patients.** AJR Am J Roentgenol. 1992;158(4):765-9; discussion 71-2. (Level III)



- evidence). [View the reference](#)
18. Thompson WM, Kilani RK, Smith BB, Thomas J, Jaffe TA, DeLong DM, et al. **Accuracy of abdominal radiography in acute small-bowel obstruction: does reviewer experience matter?** AJR Am J Roentgenol. 2007;188(3):W233-8. (Level II evidence). [View the reference](#)
 19. Maglinte DD, Reyes BL, Harmon BH, Kelvin FM, Turner WW, Jr., Hage JE, et al. **Reliability and role of plain film radiography and CT in the diagnosis of small-bowel obstruction.** AJR Am J Roentgenol. 1996;167(6):1451-5. (Level II evidence). [View the reference](#)
 20. Heinberg EM, Finan MA, Chambers RB, Bazzett LB, Kline RC. **Postoperative ileus on a gynecologic oncology service--do abdominal x-rays have a role?** Gynecol Oncol. 2003;90(1):158-62. (Level III evidence). [View the reference](#)
 21. Ko YT, Lim JH, Lee DH, Lee HW, Lim JW. **Small bowel obstruction: sonographic evaluation.** Radiology. 1993;188(3):649-53. (Level II evidence). [View the reference](#)
 22. Shrake PD, Rex DK, Lappas JC, Maglinte DD. **Radiographic evaluation of suspected small bowel obstruction.** Am J Gastroenterol. 1991;86(2):175-8. (Level III evidence). [View the reference](#)
 23. Smith JE, Hall EJ. **The use of plain abdominal x rays in the emergency department.** Emerg Med J. 2009;26(3):160-3. (Review article). [View the reference](#)
 24. Ahn SH, Mayo-Smith WW, Murphy BL, Reinert SE, Cronan JJ. **Acute nontraumatic abdominal pain in adult patients: abdominal radiography compared with CT evaluation.** Radiology. 2002;225(1):159-64. (Level III evidence). [View the reference](#)
 25. Suri S, Gupta S, Sudhakar PJ, Venkataramu NK, Sood B, Wig JD. **Comparative evaluation of plain films, ultrasound and CT in the diagnosis of intestinal obstruction.** Acta Radiol. 1999;40(4):422-8. (Level II evidence). [View the reference](#)
 26. Loughborough W. **Development of a plain radiograph requesting algorithm for patients presenting with acute abdominal pain.** Quantitative Imaging in Medicine and Surgery. 2012;2(4):239-44. (Guidelines). [View the reference](#)
 27. **ACR appropriateness criteria acute onset flank pain - suspicion of stone disease (urolithiasis).** 2015. (Guideline). [View the reference](#)
 28. **ACR-SPR practice parameter for the performance of abdominal radiography.** 2016. (Guideline). [View the reference](#)
 29. **ACR appropriateness criteria. Acute nonlocalized abdominal pain.** 2018. (Guideline). [View the reference](#)
 30. Haller O, Karlsson L, Nyman R. **Can low-dose abdominal CT replace abdominal plain film in evaluation of acute abdominal pain?** Ups J Med Sci. 2010;115(2):113-20. (Level II-III evidence). [View the reference](#)
 31. Laméris W, van Randen A, van Es HW, van Heesewijk JPM, van Ramshorst B, Bouma WH, et al. **Imaging strategies for detection of urgent conditions in patients with acute abdominal pain: diagnostic accuracy study.** BMJ. 2009;338 (Level III evidence). [View the reference](#)
 32. Nguyen LK, Wong DD, Fatovich DM, Yeung JM, Persaud J, Wood CJ, et al. **Low-dose computed tomography versus plain abdominal radiography in the investigation of an acute abdomen.** ANZ J Surg. 2012;82(1-2):36-41. (Level II evidence). [View the reference](#)
 33. Chiu YH, Chen JD, Tiu CM, Chou YH, Yen DH, Huang CI, et al. **Reappraisal of radiographic signs of pneumoperitoneum at emergency department.** Am J Emerg Med. 2009;27(3):320-7. (Level III evidence). [View the reference](#)
 34. Li Y, Song J, Lin N, Zhao C. **Computed tomography scan is superior to x-ray plain film in the diagnosis of gastrointestinal tract perforation.** Am J Emerg Med. 2015;33(3):480.e3-5. (Review article). [View the reference](#)
 35. Levine MS, Scheiner JD, Rubesin SE, Laufer I, Herlinger H. **Diagnosis of pneumoperitoneum on supine abdominal radiographs.** AJR Am J Roentgenol. 1991;156(4):731-5. (Level III evidence). [View the reference](#)
 36. **ACR appropriateness criteria blunt abdominal trauma.** 2012. (Guideline). [View the reference](#)
 37. Rao SS, Ozturk R, Laine L. **Clinical utility of diagnostic tests for constipation in adults: a**



systematic review. Am J Gastroenterol. 2005;100(7):1605-15. (Review article). [View the reference](#)

38. Nagaviroj K, Yong WC, Fassbender K, Zhu G, Oneschuk D. **Comparison of the Constipation Assessment Scale and plain abdominal radiography in the assessment of constipation in advanced cancer patients.** J Pain Symptom Manage. 2011;42(2):222-8. (Level III evidence). [View the reference](#)

39. Udayasankar UK, Li J, Baumgarten DA, Small WC, Kalra MK. **Acute abdominal pain: value of non-contrast enhanced ultra-low-dose multi-detector row CT as a substitute for abdominal radiographs.** Emergency radiology. 2009;16(1):61-70. (Level III evidence). [View the reference](#)

40. Alshamari M, Norrman E, Geijer M, Jansson K, Geijer H. **Diagnostic accuracy of low-dose CT compared with abdominal radiography in non-traumatic acute abdominal pain: prospective study and systematic review.** Eur Radiol. 2016;26(6):1766-74. (Level II-III evidence). [View the reference](#)

41. Poletti PA, Becker M, Becker CD, Halfon Poletti A, Rutschmann OT, Zaidi H, et al. **Emergency assessment of patients with acute abdominal pain using low-dose CT with iterative reconstruction: a comparative study.** Eur Radiol. 2017;27(8):3300-9. (Level II evidence). [View the reference](#)

Information for Consumers

Information from this website	Information from the Royal Australian and New Zealand College of Radiologists' website
<p>Radiation Risks of X-rays and Scans</p> <p>Plain Radiography (X-ray)</p>	<p>Plain Radiography/X-rays</p>

Copyright

© Copyright 2015, Department of Health Western Australia. All Rights Reserved. This web site and its content has been prepared by The Department of Health, Western Australia. The information contained on this web site is protected by copyright.

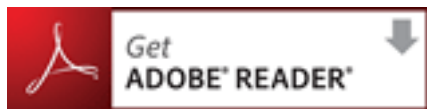Legal Notice

Please remember that this leaflet is intended as general information only. It is not definitive and The Department of Health, Western Australia can not accept any legal liability arising from its use. The information is kept as up to date and accurate as possible, but please be warned that it is always subject to change

File Formats



Some documents for download on this website are in a Portable Document Format (PDF). To read these files you might need to download Adobe Acrobat Reader.



[Legal Matters](#)