

# Diagnostic Imaging Pathways - Bowel Obstruction (Suspected)

## Population Covered By The Guidance

This pathway provides guidance for imaging adult patients with suspected bowel obstruction, including the roles of plain abdominal radiography and more advanced imaging.

**Date reviewed: December 2018**

**Date of next review: December 2021**






**Published: March 2019**

## Quick User Guide

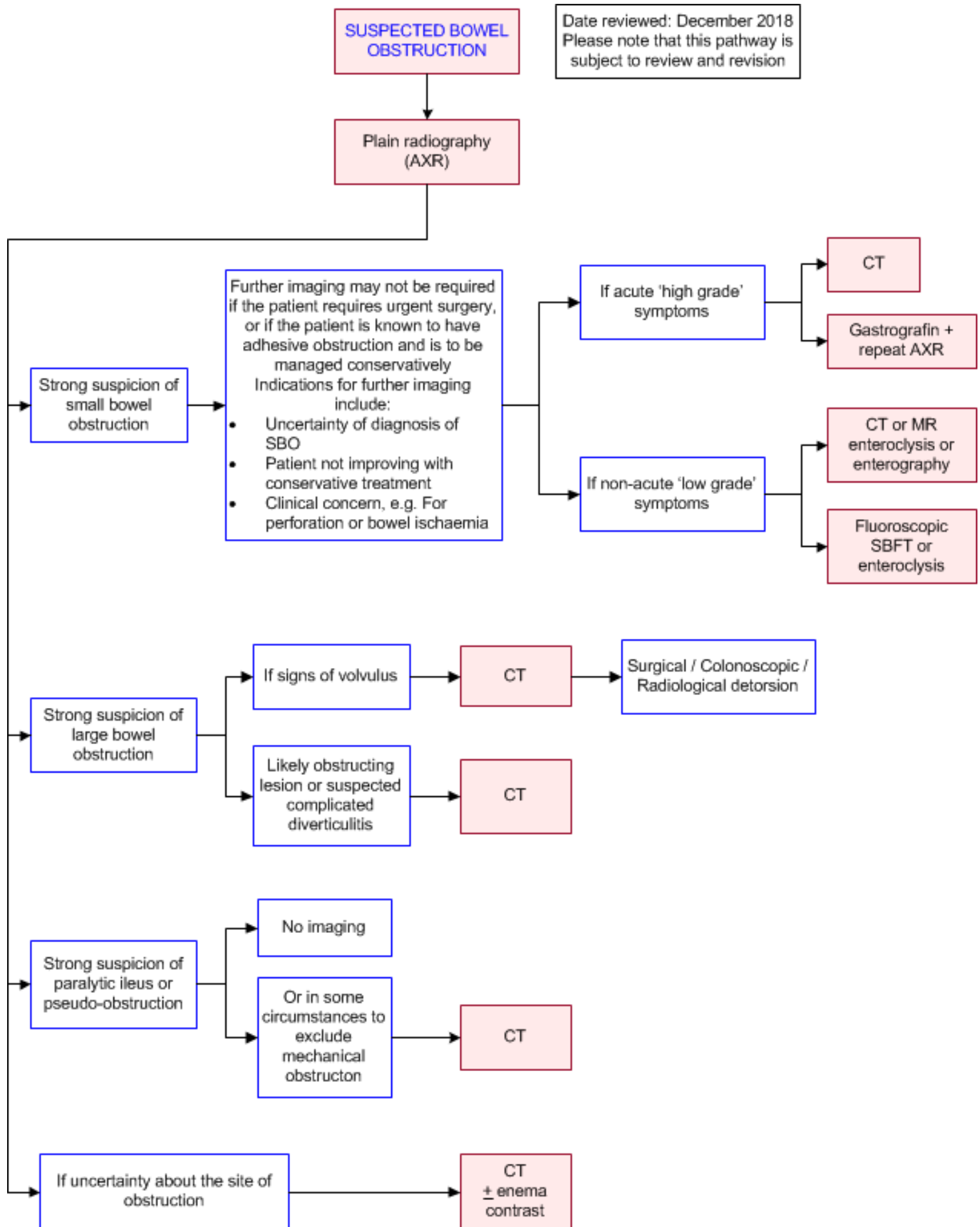
Move the mouse cursor over the **PINK** text boxes inside the flow chart to bring up a pop up box with salient points.

Clicking on the **PINK** text box will bring up the full text.

The relative radiation level (RRL) of each imaging investigation is displayed in the pop up box.

SYMBOL	RRL	EFFECTIVE DOSE RANGE
	None	0
	Minimal	< 1 millisieverts
	Low	1-5 mSv
	Medium	5-10 mSv
	High	>10 mSv

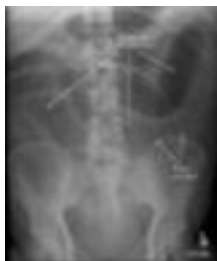## Pathway Diagram



## Image Gallery

*Note: These images open in a new page*

1a



### Small Bowel Obstruction

Image 1a (Plain radiograph, Supine view): Multiple dilated loops of small bowel.

1b

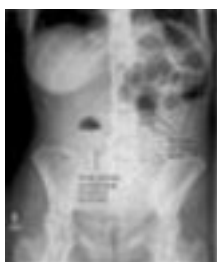
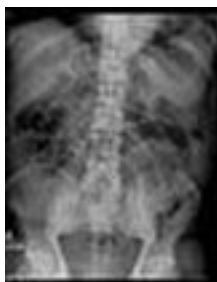
Image 1b (Plain radiograph, Erect view): Multiple dilated loops of small bowel with air-fluid levels and "string of pearls" sign indicating a mechanical small bowel obstruction.

2a



### Incarcerated Small Bowel Hernia

Image 2a (Plain radiograph): Multiple dilated loops of small bowel in the upper abdomen.

2b

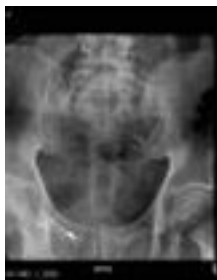

Image 2b (Plain radiograph): Lower abdominal film showing increased density in the right obturator foramen.

2c

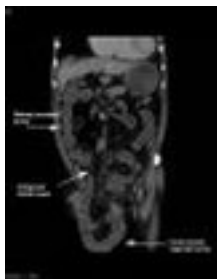

Image 2c (Computed Tomography): Coronal view of the same patient demonstrating an incarcerated small bowel. Dilated proximal loops of small bowel enter a large right inguinal hernia. The distal small bowel loop exiting the hernia is collapsed.

2d

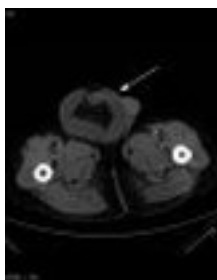
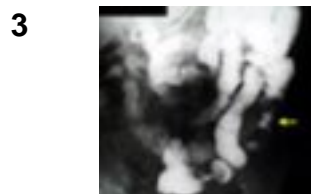
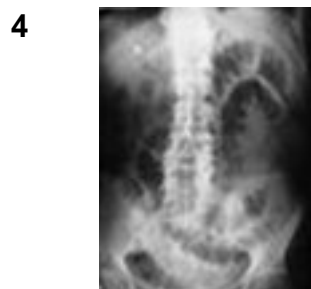Image 2d (Computed Tomography): Axial view showing the dilated small bowel loop in the right inguinal hernia (arrow).



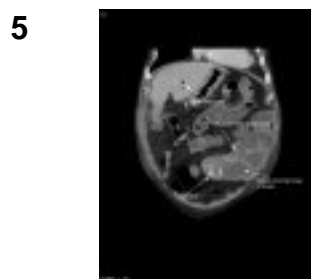
### Malignant Small Bowel Obstruction

Image 3 (Small bowel enteroclysis): Small bowel obstruction due to a serosal metastasis (arrow).



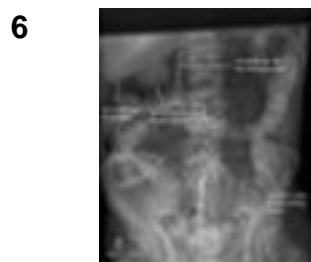
### Gallstone Ileus

Image 4 (Plain radiograph): Multiple loops of distended small bowel with air in the biliary tree (arrow).



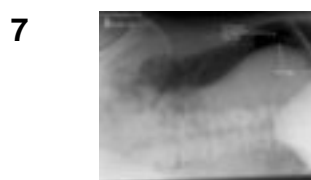
### Gallstone Ileus

Image 5 (Computed Tomography): A large gallstone is impacted in the small bowel causing mechanical obstruction. Note air in the biliary tree.



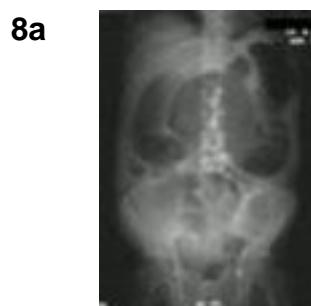
### Pneumoperitoneum

Image 6 (Plain radiograph): Perforated bowel and pneumoperitoneum. The intraabdominal gas outlines the liver edge, gallbladder and falciform ligament.



### Pneumoperitoneum

Image 7 (Plain radiograph, Lateral decubitus): Perforated bowel with pneumoperitoneum. The intraabdominal gas outlines the liver edge and chest wall.



### Large Bowel Obstruction

Image 8a (Plain radiograph): Distension of the caecum, ascending and transverse colon.

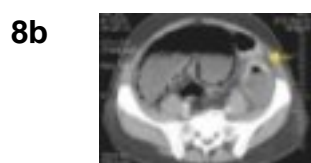


Image 8b (Computed Tomography): CT of the same patient showing marked caecal distension secondary to a constricting tumour (arrow).



### Colorectal Carcinoma

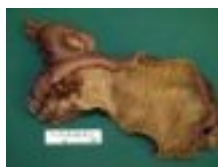

Image 9a: A right hemicolectomy showing a large, ulcerated and exophytic caecal adenocarcinoma.

9b

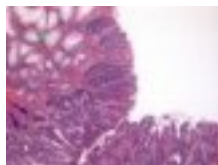
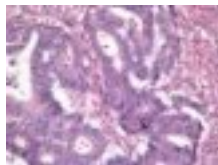
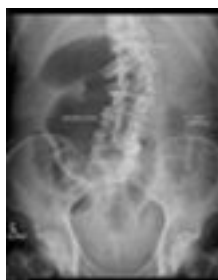Image 9b (H&E, x2.5) and 9c (H&E, x10): Histological sections showing a moderately differentiated colorectal adenocarcinoma composed of malignant glands invading into the bowel wall (blue arrows). The glands are lined by cells showing marked nuclear atypia. Normal colonic mucosa is included for comparison (green arrow).

9c



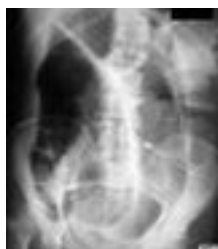10



### Caecal Volvulus

Image 10 (Plain radiograph): Markedly distended loop of large bowel from a caecal volvulus.

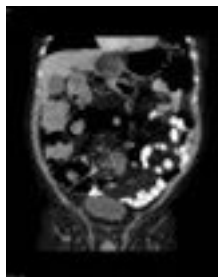
11



### Sigmoid Volvulus

Image 11 (Plain radiograph): Markedly dilated loop of large bowel. The dense white line between the limbs (arrow) points to the origin of the volvulus.

12



### Sigmoid Volvulus

Image 12 (Computed Tomography): Sigmoid volvulus with the classical "whirl" sign representing the twisted sigmoid mesentery (arrow).

## Teaching Points

- CT is generally the investigation of choice to diagnose bowel obstruction, the location, cause and complications
- Plain radiographs may miss low-grade obstruction and are rarely able to show the cause, however they are a fast, inexpensive and widely available investigation
- In low-grade small bowel obstruction or during relatively asymptomatic intervals between episodes of recurrent obstruction, the small bowel can be assessed with CT or MR enteroclysis or enterography. The small bowel is dilated with intraluminal contrast; areas of obstruction that may be missed on conventional CT are non-distendable and more easily identified

## Plain Radiography (AXR)

- Limited sensitivity and specificity for bowel obstruction, but remains widely used in the initial diagnostic evaluation due to widespread availability, low cost and ability to monitor disease progression [1](#)
- For small bowel obstruction, some studies report accuracy approaching 80-90%, [2,3](#) similar to CT, [4](#) while others reported AXR to be of little or no help; [5,6](#) one study found AXR to be misleading in 20-40% of patients [7](#)
- For large bowel obstruction, sensitivity has been reported as approximately 80% for detecting and predicting the level of large bowel obstruction [8,9](#)
- Erect AXR may be complementary to supine views but does not necessarily improve diagnostic accuracy [10](#)
- Even though AXR may be able to diagnose SBO and LBO, CT provides much more information about the site, cause and complications of SBO, so AXR is unlikely to be definitive
  - In suspected SBO patients, AXR may just prolong the evaluation period while adding radiation exposure [11,12](#)
- Except for inguinal hernias and gallstone ileus, AXR rarely identifies the cause of obstruction [13](#)
- Findings suggesting the diagnosis of small bowel obstruction include [4,13,14](#)
  - Distended loops of small bowel >3cm
  - Collapsed colon
  - Presence of >2 air fluid levels on erect AXR
  - The "string of pearls" sign resulting from the small amount of residual air compared with the large amount of retained fluid
- Limitations [1,4,15](#)
  - Unable to diagnose the cause of obstruction in most cases
  - Cannot reliably detect the presence of ischaemic complications
  - May miss early, proximal or partial/low grade obstruction
  - Difficult to differentiate between obstruction and ileus
  - In obstruction of ileocaecal region, it may be difficult to determine whether the level is in the proximal large bowel or distal ileum

## Computed Tomography (CT) in Evaluation of Small Bowel Obstruction (SBO)

- Preferred imaging modality for the diagnosis of bowel obstruction [1,15-17](#)
- In moderate or high grade obstruction, CT is normally performed with intravenous contrast but intraluminal contrast is not required
- 90-96% sensitivity for detection of acute high-grade obstruction, with specificity 96-100% [4,18-22](#)
- A number of CT findings are associated with the need for surgery [23](#)
- Useful in
  - Confirming or excluding small bowel obstruction (versus pseudo-obstruction) [4,18,19,24](#)
  - Defining the degree and site of obstruction, including the presence of closed loop obstruction [4,24-28](#)
  - Identifying the cause of small bowel obstruction (73-95% sensitivity) [4,19,21,22,25,27,29](#)
  - Confirming or excluding the diagnosis of ischaemia (approximately 60-90% sensitivity and up to 100% specificity) [24,28-33](#) or perforation
  - Ability to depict other causes of an acute abdomen
- Limitations
  - Lower sensitivity (approximately 50%) for the detection and location of low-grade small

bowel obstruction [4,20,22](#) – CT or MR enteroclysis or enterography may be advantageous in this situation

- Exposure to ionising radiation
- Iodinated contrast may be contraindicated with renal impairment or allergies, however SBO can still be assessed without contrast [34](#)

## CT Enterography and Enteroclysis

- Can be performed In low grade small bowel obstruction or during relatively asymptomatic intervals between episodes of recurrent obstruction
- Enteroclysis is performed by intubating the small bowel and infusing contrast material, essentially bypassing the stomach [13](#)
- By distending the small bowel, fixed or narrowed areas can be identified
- Enteroclysis can be an adjunct to CT; compared with CT, has high reliability for diagnosing or ruling out low-grade and intermittent obstructions [35](#)
- Can also detect multiple levels of obstruction [35](#)
- Main disadvantages are that enteroclysis is time consuming and uncomfortable for patients
- In enterography, patients ingest a large amount of fluid that fills the stomach and small bowel; the volume is limited by patient tolerance [36](#)
  - In enterography, patients ingest a large amount of fluid that fills the stomach and small bowel; the volume is limited by patient tolerance [36](#)
  - Although enteroclysis achieves better small bowel distension, it is not clearly superior to enterography [37](#)
- Enterography may be preferred if expertise to insert a nasojejunal tube is not available

## MR Enterography and Enteroclysis

- Can be performed in low grade small bowel obstruction or during relatively asymptomatic intervals between episodes of recurrent obstruction
- Enteroclysis is performed by intubating the small bowel and infusing contrast material, essentially bypassing the stomach [13,38](#)
- By distending the small bowel, fixed or narrowed areas can be identified, including low-grade obstructions
- Can also demonstrate extraluminal features [38](#)
- Unlike fluoroscopy or CT enteroclysis, there is no exposure to ionising radiation. This is advantageous in younger patients with Crohn's Disease who require repeat imaging and may have recurrent presentations of obstruction
- Disadvantages:
  - Patient discomfort
  - Time-consuming
  - Longer acquisition time than CT can result in peristalsis motion artefacts; breath holding required to minimise respiration artefact
  - MRI is contraindicated in the presence of some ferromagnetic prostheses
  - Cost
  - Limited availability
  - Although MRI does not use ionising radiation, there is exposure during fluoroscopic insertion of the nasojejunal tube [39](#)
- In enterography, patients ingest a large amount of fluid that fills the stomach and small bowel; the

volume is limited by patient tolerance [38](#)

- Enteroclysis achieves better luminal distension, particularly at the level of the jejunum, [38](#) however there is no significant difference in terms of detection of clinically significant findings. [40,41](#) Limited studies comparing MR enterography and enteroclysis have focused on Crohn's disease; there is little research investigating the accuracy in other causes of small bowel obstruction

## Fluoroscopic Small Bowel Follow Through (SBFT) and Enteroclysis

- SBFT and enteroclysis have been generally replaced by cross-sectional imaging, including CT and MR [17,40,42](#) however water-soluble contrast agents are still used for diagnostic, prognostic and therapeutic purposes. [Read more here](#)
- Can be performed in low grade small bowel obstruction or during relatively asymptomatic intervals between episodes of recurrent obstruction
- SBFT involves ingestion of 500-600mL of oral contrast, followed by intermittent fluoroscopy of the small bowel every 15 to 30 minutes until contrast reaches the right colon
- In fluoroscopic enteroclysis, the small bowel is intubated and contrast is gradually infused to distend the small bowel
- A dedicated small bowel follow through examination may be appropriate in suspected low grade small bowel obstruction if enteroclysis is unavailable [43](#)
- Findings in small bowel obstruction include [18](#)
  - Failure of contrast to reach the colon within 4 hours
  - Dilatation of loops of small bowel
  - Delayed transit time of the barium to a point of transition in the caliber of the bowel lumen
  - With complete obstruction, no barium will be visualised past the point of obstruction in delayed images taken 24 hours after administration of contrast
  - With partial obstruction, barium will pass the obstructed portion into collapsed bowel loops
- Advantages [18](#)
  - Does not require nasointestinal intubation
  - Compared to enteroclysis, SBFT is easier to perform and does not require additional expertise
- Limitations [18,42,43](#)
  - Time required for contrast to reach the obstruction
  - Dilution of barium in high-grade obstruction because of excess residual intraluminal fluid resulting in non-uniform small bowel filling [19](#)
  - Partially obstructing lesions may not be visualised due to limitations in assessment of intestinal distensibility and fixation of small bowel loops
  - Inability of the patient to drink sufficient quantities of barium
  - Contraindicated in complete obstruction with suspected bowel ischaemia
  - Does not demonstrate extramural disease
  - Higher radiation dose compared with other modalities

## Gastrografin + Repeat AXR

- Multiple studies have shown the diagnostic and prognostic value of water-soluble contrast agents such as gastrografin in the work-up of SBO
- Oral contrast is administered followed by delayed imaging, usually AXR, but contrast can also be visualised on CT
- The presence of contrast in the colon predicts the resolution of obstruction without surgery with



- 92-96% sensitivity and 93-98% specificity [44-46](#)
  - AXR should be taken at least 4-24h from administration of contrast [44-46](#)
- There is also mixed evidence about whether water-soluble contrast has a therapeutic effect in reducing the need for surgery. [44-48](#) Some surgeons may administer gastrografin for therapeutic purposes as well as diagnostic [49](#)

## Computed Tomography (CT) in Evaluation of Large Bowel Obstruction (LBO)

- Imaging modality of choice for the diagnosis and cause of LBO [50](#)
- Reported sensitivity of 91-96% and specificity of 91-93% for LBO [51,52](#)
- As in SBO, CT is useful for identifying a transition point in LBO, as well as depicting intraluminal, mural and extramural causes of obstruction [50](#)
  - The most common cause of LBO is carcinoma of the colon [50,53](#)
- Intravenous contrast should be used if possible; oral and rectal contrast are not routinely indicated
- Supplementary CT acquisitions (e.g. prone or decubitus scans) may be performed to distinguish real versus pseudo transition points in the colon seen on supine scans. These may be acquired using low-dose protocols [51](#)
- Limitations
  - Some appearances may mimic LBO such as spasm at the splenic flexure, [51](#) or isolated distension of hepatic flexure and ascending colon in pancreatitis. [54](#) Supplementary acquisitions in different positions can help to distinguish these
  - Partially obstructing lesions may not be well demonstrated, especially right-sided colonic tumors [50,51](#)
  - Exposure to ionising radiation and intravenous contrast
- Contrast enema has been largely replaced by CT [50](#)
- If the diagnosis of LBO is uncertain, rectal contrast can aid in localisation of the lesion [50,55](#)
- CT colonography is useful to diagnose colorectal malignancy, particularly if colonoscopy is incomplete due to being unable to bypass strictures [56](#) but is not indicated in the acute setting
  - Bowel preparation is required before the colon is insufflated with air, so CT colonography is not generally appropriate in acute LBO

## References

References are graded from Level I to V according to the Oxford Centre for Evidence-Based Medicine, Levels of Evidence. [Download the document](#)

- 1.** Maung AA, Johnson DC, Piper GL, Barbosa RR, Rowell SE, Bokhari F, et al. **Evaluation and management of small-bowel obstruction: an Eastern Association for the Surgery of Trauma practice management guideline.** The journal of trauma and acute care surgery. 2012;73(5 Suppl 4):S362-9. (Guideline). [View the reference](#)
- 2.** Fukuya T, Hawes DR, Lu CC, Chang PJ, Barloon TJ. **CT diagnosis of small-bowel obstruction: efficacy in 60 patients.** AJR Am J Roentgenol. 1992;158(4):765-9; discussion 71-2. (Level III evidence). [View the reference](#)
- 3.** Thompson WM, Kilani RK, Smith BB, Thomas J, Jaffe TA, DeLong DM, et al. **Accuracy of abdominal radiography in acute small-bowel obstruction: does reviewer experience matter?** AJR Am J Roentgenol. 2007;188(3):W233-8. (Level II evidence). [View the reference](#)
- 4.** Maglinte DD, Reyes BL, Harmon BH, Kelvin FM, Turner WW, Jr., Hage JE, et al. **Reliability and**

- role of plain film radiography and CT in the diagnosis of small-bowel obstruction.** AJR Am J Roentgenol. 1996;167(6):1451-5. (Level II evidence). [View the reference](#)
5. Heinberg EM, Finan MA, Chambers RB, Bazzett LB, Kline RC. **Postoperative ileus on a gynecologic oncology service--do abdominal x-rays have a role?** Gynecol Oncol. 2003;90(1):158-62. (Level III evidence). [View the reference](#)
  6. Ko YT, Lim JH, Lee DH, Lee HW, Lim JW. **Small bowel obstruction: sonographic evaluation.** Radiology. 1993;188(3):649-53. (Level II evidence). [View the reference](#)
  7. Shrake PD, Rex DK, Lappas JC, Maglinte DD. **Radiographic evaluation of suspected small bowel obstruction.** Am J Gastroenterol. 1991;86(2):175-8. (Level III evidence). [View the reference](#)
  8. Chapman AH, McNamara M, Porter G. **The acute contrast enema in suspected large bowel obstruction: value and technique.** Clin Radiol. 1992;46(4):273-8. (Level III evidence). [View the reference](#)
  9. Grunshaw ND, Renwick IG, Scarisbrick G, Nasmyth DG. **Prospective evaluation of ultrasound in distal ileal and colonic obstruction.** Clin Radiol. 2000;55(5):356-62. (Level II-III evidence). [View the reference](#)
  10. Geng WZM, Fuller M, Osborne B, Thoires K. **The value of the erect abdominal radiograph for the diagnosis of mechanical bowel obstruction and paralytic ileus in adults presenting with acute abdominal pain.** Journal of medical radiation sciences. 2018 (Level II evidence). [View the reference](#)
  11. **ACR appropriateness criteria suspected small-bowel obstruction.** 2013. (Guideline). [View the reference](#)
  12. Artigas Martin JM, Marti de Gracia M, Rodriguez Torres C, Marquina Martinez D, Parrilla Herranz P. **Routine abdominal x-rays in the emergency department: a thing of the past?** Radiologia. 2015;57(5):380-90. (Review article). [View the reference](#)
  13. Nicolaou S, Kai B, Ho S, Su J, Ahamed K. **Imaging of acute small-bowel obstruction.** Am J Roentgenol. 2005;185. (Review)(4):1036-44. [View the reference](#)
  14. Silva AC, Pimenta M, Guimaraes LS. **Small bowel obstruction: what to look for.** Radiographics. 2009;29(2):423-39. (Review). [View the reference](#)
  15. Jackson P, Vigiola Cruz M. **Intestinal obstruction: evaluation and management.** Am Fam Physician. 2018;98(6):362-7. (Review article). [View the reference](#)
  16. Ten Broek RPG, Krielen P, Di Saverio S, Coccolini F, Biffi WL, Ansaloni L, et al. **Bologna guidelines for diagnosis and management of adhesive small bowel obstruction (ASBO): 2017 update of the evidence-based guidelines from the world society of emergency surgery ASBO working group.** World J Emerg Surg. 2018;13:24. (Guideline). [View the reference](#)
  17. **ACR appropriateness criteria. Suspected small-bowel obstruction.** 2013. (Guideline). [View the reference](#)
  18. Macari M, Megibow A. **Imaging of suspected acute small bowel obstruction.** Semin Roentgenol. 2001;36(2):108-17. (Review article). [View the reference](#)
  19. Peck JJ, Milleson T, Phelan J. **The role of computed tomography with contrast and small bowel follow-through in management of small bowel obstruction.** Am J Surg. 1999;177(5):375-8. (Level III evidence). [View the reference](#)
  20. Maglinte DD, Gage SN, Harmon BH, Kelvin FM, Hage JP, Chua GT, et al. **Obstruction of the small intestine: accuracy and role of CT in diagnosis.** Radiology. 1993;188(1):61-4. (Level III evidence). [View the reference](#)
  21. Megibow AJ, Balthazar EJ, Cho KC, Medwid SW, Birnbaum BA, Noz ME. **Bowel obstruction: evaluation with CT.** Radiology. 1991;180(2):313-8. (Level III evidence). [View the reference](#)
  22. Pongpornsup S, Tarachat K, Srisajjakul S. **Accuracy of 64 sliced multi-detector computed tomography in diagnosis of small bowel obstruction.** J Med Assoc Thai. 2009;92(12):1651-61. (Level III evidence). [View the reference](#)
  23. Scrima A, Lubner MG, King S, Pankratz J, Kennedy G, Pickhardt PJ. **Value of MDCT and clinical and laboratory data for predicting the need for surgical intervention in suspected small-**



- bowel obstruction.** AJR Am J Roentgenol. 2017;208(4):785-93. (Level III evidence). [View the reference](#)
24. Frager D, Baer JW, Medwid SW, Rothpearl A, Bossart P. **Detection of intestinal ischemia in patients with acute small-bowel obstruction due to adhesions or hernia: efficacy of CT.** AJR Am J Roentgenol. 1996;166(1):67-71. (Level II-III evidence). [View the reference](#)
25. Taourel PG, Fabre JM, Pradel JA, Seneterre EJ, Megibow AJ, Bruel JM. **Value of CT in the diagnosis and management of patients with suspected acute small-bowel obstruction.** AJR Am J Roentgenol. 1995;165(5):1187-92. (Level III evidence). [View the reference](#)
26. Idris M, Kashif N, Idris S, Memon WA, Tanveer UH, Haider Z. **Accuracy of 64-slice multidetector computed tomography scan in detection of the point of transition of small bowel obstruction.** Japanese journal of radiology. 2012;30(3):235-41. (Level II-III evidence). [View the reference](#)
27. Barnett RE, Younga J, Harris B, Keskey RC, Nisbett D, Perry J, et al. **Accuracy of computed tomography in small bowel obstruction.** Am Surg. 2013;79(6):641-3. (Level III evidence). [View the reference](#)
28. Makar RA, Bashir MR, Haystead CM, Iseman C, Mayes N, Hebert S, et al. **Diagnostic performance of MDCT in identifying closed loop small bowel obstruction.** Abdominal radiology (New York). 2016;41(7):1253-60. (Level III evidence). [View the reference](#)
29. Balthazar EJ, Liebeskind ME, Macari M. **Intestinal ischemia in patients in whom small bowel obstruction is suspected: evaluation of accuracy, limitations, and clinical implications of CT in diagnosis.** Radiology. 1997;205(2):519-22. (Level II-III evidence). [View the reference](#)
30. Zalcman M, Sy M, Donckier V, Closset J, Gansbeke DV. **Helical CT signs in the diagnosis of intestinal ischemia in small-bowel obstruction.** AJR Am J Roentgenol. 2000;175(6):1601-7. (Level II-III evidence). [View the reference](#)
31. Geffroy Y, Boulay-Coletta I, Julles MC, Nakache S, Taourel P, Zins M. **Increased unenhanced bowel-wall attenuation at multidetector CT is highly specific of ischemia complicating small-bowel obstruction.** Radiology. 2014;270(1):159-67. (Level II-III evidence). [View the reference](#)
32. Millet I, Taourel P, Ruyer A, Molinari N. **Value of CT findings to predict surgical ischemia in small bowel obstruction: A systematic review and meta-analysis.** Eur Radiol. 2015;25(6):1823-35. (Level I-II evidence). [View the reference](#)
33. Millet I, Boutot D, Faget C, Pages-Bouic E, Molinari N, Zins M, et al. **Assessment of strangulation in adhesive small bowel obstruction on the basis of combined CT findings: implications for clinical care.** Radiology. 2017;285(3):798-808. (Level III evidence). [View the reference](#)
34. Atri M, McGregor C, McInnes M, Power N, Rahnavardi K, Law C, et al. **Multidetector helical CT in the evaluation of acute small bowel obstruction: comparison of non-enhanced (no oral, rectal or IV contrast) and IV enhanced CT.** Eur J Radiol. 2009;71(1):135-40. (Level II-III evidence). [View the reference](#)
35. Maglinte DD, Kelvin FM, Sandrasegaran K, Nakeeb A, Romano S, Lappas JC, et al. **Radiology of small bowel obstruction: contemporary approach and controversies.** Abdom Imaging. 2005;30(2):160-78. (Review). [View the reference](#)
36. Barlow JM, Goss BC, Hansel SL, Kolbe AB, Rackham JL, Bruining DH, et al. **CT enterography: technical and interpretive pitfalls.** Abdom Imaging. 2015;40(5):1081-96. (Review). [View the reference](#)
37. Minordi LM, Vecchioli A, Mirk P, Bonomo L. **CT enterography with polyethylene glycol solution vs CT enteroclysis in small bowel disease.** The British journal of radiology. 2011;84(998):112-9. (Level III evidence). [View the reference](#)
38. Masselli G, Gualdi G. **MR imaging of the small bowel.** Radiology. 2012;264(2):333-48. (Review). [View the reference](#)
39. Puustinen L, Numminen K, Uusi-Simola J, Sipponen T. **Radiation exposure during nasojejunal intubation for MRI enteroclysis.** Scand J Gastroenterol. 2012;47(6):658-61. (Level II-III)

- evidence). [View the reference](#)
40. Murphy KP, McLaughlin PD, O'Connor OJ, Maher MM. **Imaging the small bowel.** *Curr Opin Gastroenterol.* 2014;30(2):134-40. (Review article). [View the reference](#)
  41. Liu W, Liu J, Xiao W, Luo G. **A diagnostic accuracy meta-analysis of CT and MRI for the evaluation of small bowel crohn disease.** *Acad Radiol.* 2017;24(10):1216-25. (Level II evidence). [View the reference](#)
  42. Markova I, Kluchova K, Zboril R, Mashlan M, Herman M. **Small bowel imaging - still a radiologic approach?** *Biomedical papers of the Medical Faculty of the University Palacky, Olomouc, Czechoslovakia.* 2010;154(2):123-32. (Review). [View the reference](#)
  43. Maglinte DD, Heitkamp DE, Howard TJ, Kelvin FM, Lappas JC. **Current concepts in imaging of small bowel obstruction.** *Radiol Clin North Am.* 2003;41(2):263-83, vi. (Review). [View the reference](#)
  44. Ceresoli M, Coccolini F, Catena F, Montori G, Di Saverio S, Sartelli M, et al. **Water-soluble contrast agent in adhesive small bowel obstruction: a systematic review and meta-analysis of diagnostic and therapeutic value.** *Am J Surg.* 2016;211(6):1114-25. (Level I evidence). [View the reference](#)
  45. Branco BC, Barmparas G, Schnuriger B, Inaba K, Chan LS, Demetriades D. **Systematic review and meta-analysis of the diagnostic and therapeutic role of water-soluble contrast agent in adhesive small bowel obstruction.** *Br J Surg.* 2010;97(4):470-8. (Level I evidence). [View the reference](#)
  46. Abbas S, Bissett IP, Parry BR. **Oral water soluble contrast for the management of adhesive small bowel obstruction.** *Cochrane Database Syst Rev.* 2007(3):Cd004651. (Level I evidence). [View the reference](#)
  47. Scotte M, Mauvais F, Bubenheim M, Cosse C, Suaud L, Savoye-Collet C, et al. **Use of water-soluble contrast medium (gastrografin) does not decrease the need for operative intervention nor the duration of hospital stay in uncomplicated acute adhesive small bowel obstruction? A multicenter, randomized, clinical trial (Adhesive Small Bowel Obstruction Study) and systematic review.** *Surgery.* 2017;161(5):1315-25. (Level II evidence). [View the reference](#)
  48. Zielinski MD, Haddad NN, Cullinane DC, Inaba K, Yeh DD, Wydo S, et al. **Multi-institutional, prospective, observational study comparing the Gastrografin challenge versus standard treatment in adhesive small bowel obstruction.** *The journal of trauma and acute care surgery.* 2017;83(1):47-54. (Level III evidence). [View the reference](#)
  49. Lee MJ, Sayers AE, Wilson TR, Acheson AG, Anderson ID, Fearnhead NS. **Current management of small bowel obstruction in the UK: results from the National Audit of Small Bowel Obstruction clinical practice survey.** *Colorectal Dis.* 2018;20(7):623-30. (Level II evidence). [View the reference](#)
  50. Jaffe T, Thompson WM. **Large-bowel obstruction in the adult: classic radiographic and CT findings, etiology, and mimics.** *Radiology.* 2015;275(3):651-63. (Review). [View the reference](#)
  51. Beattie GC, Peters RT, Guy S, Mendelson RM. **Computed tomography in the assessment of suspected large bowel obstruction.** *ANZ J Surg.* 2007;77(3):160-5. (Level II evidence). [View the reference](#)
  52. Frager D, Rovno HD, Baer JW, Bashist B, Friedman M. **Prospective evaluation of colonic obstruction with computed tomography.** *Abdom Imaging.* 1998;23(2):141-6. (Level II evidence). [View the reference](#)
  53. Gore RM, Silvers RI, Thakrar KH, Wenzke DR, Mehta UK, Newmark GM, et al. **Bowel obstruction.** *Radiol Clin North Am.* 2015;53(6):1225-40. (Review). [View the reference](#)
  54. Schwartz S, Nadelhaft J. **Simulation of colonic obstruction at the splenic flexure by pancreatitis: roentgen features.** *Am J Roentgenol Radium Ther Nucl Med.* 1957;78(4):607-16. (Level III evidence). [View the reference](#)
  55. Frago R, Ramirez E, Millan M, Kreisler E, del Valle E, Biondo S. **Current management of acute**



**malignant large bowel obstruction: a systematic review.** Am J Surg. 2014;207(1):127-38. (Review). [View the reference](#)

56. Spada C, Stoker J, Alarcon O, Barbaro F, Bellini D, Bretthauer M, et al. **Clinical indications for computed tomographic colonography: European Society of Gastrointestinal Endoscopy (ESGE) and European Society of Gastrointestinal and Abdominal Radiology (ESGAR) Guideline.** Eur Radiol. 2015;25(2):331-45. (Guideline). [View the reference](#)

## Information for Consumers

Information from this website	Information from the Royal Australian and New Zealand College of Radiologists' website
<p><a href="#">Radiation Risks of X-rays and Scans</a></p> <p><a href="#">Computed Tomography (CT)</a></p> <p><a href="#">Plain Radiography (X-ray)</a></p>	<p><a href="#">Computed Tomography (CT)</a></p> <p><a href="#">Iodine-Containing Contrast Medium</a></p> <p><a href="#">Plain Radiography/X-rays</a></p> <p><a href="#">Radiation Risk of Medical Imaging During Pregnancy</a></p> <p><a href="#">Radiation Risk of Medical Imaging for Adults and Children</a></p>

## Copyright

© Copyright 2015, Department of Health Western Australia. All Rights Reserved. This web site and its content has been prepared by The Department of Health, Western Australia. The information contained on this web site is protected by copyright.

## Legal Notice

Please remember that this leaflet is intended as general information only. It is not definitive and The Department of Health, Western Australia can not accept any legal liability arising from its use. The information is kept as up to date and accurate as possible, but please be warned that it is always subject to change

## File Formats

Some documents for download on this website are in a Portable Document Format (PDF). To read these files you might need to download Adobe Acrobat Reader.



[Legal Matters](#)