

Diagnostic Imaging Pathways - Chest Trauma

Population Covered By The Guidance

This pathway provides guidance on the imaging of adult patients with chest trauma.

Date reviewed: August 2013

Date of next review: 2017/2018






Published: August 2013

Quick User Guide

Move the mouse cursor over the **PINK** text boxes inside the flow chart to bring up a pop up box with salient points.

Clicking on the **PINK** text box will bring up the full text.

The relative radiation level (RRL) of each imaging investigation is displayed in the pop up box.

SYMBOL	RRL	EFFECTIVE DOSE RANGE
	None	0
	Minimal	< 1 millisieverts
	Low	1-5 mSv
	Medium	5-10 mSv
	High	>10 mSv

Pathway Diagram

Date reviewed: August 2013
 Please note that this pathway is subject to review and revision.

Definitions:
Penetrating injuries to the chest most commonly result from stabbing or gunshot wounds. ¹
Blunt injuries to the chest are most commonly associated with motor vehicle and sport-related accidents in western societies. ²

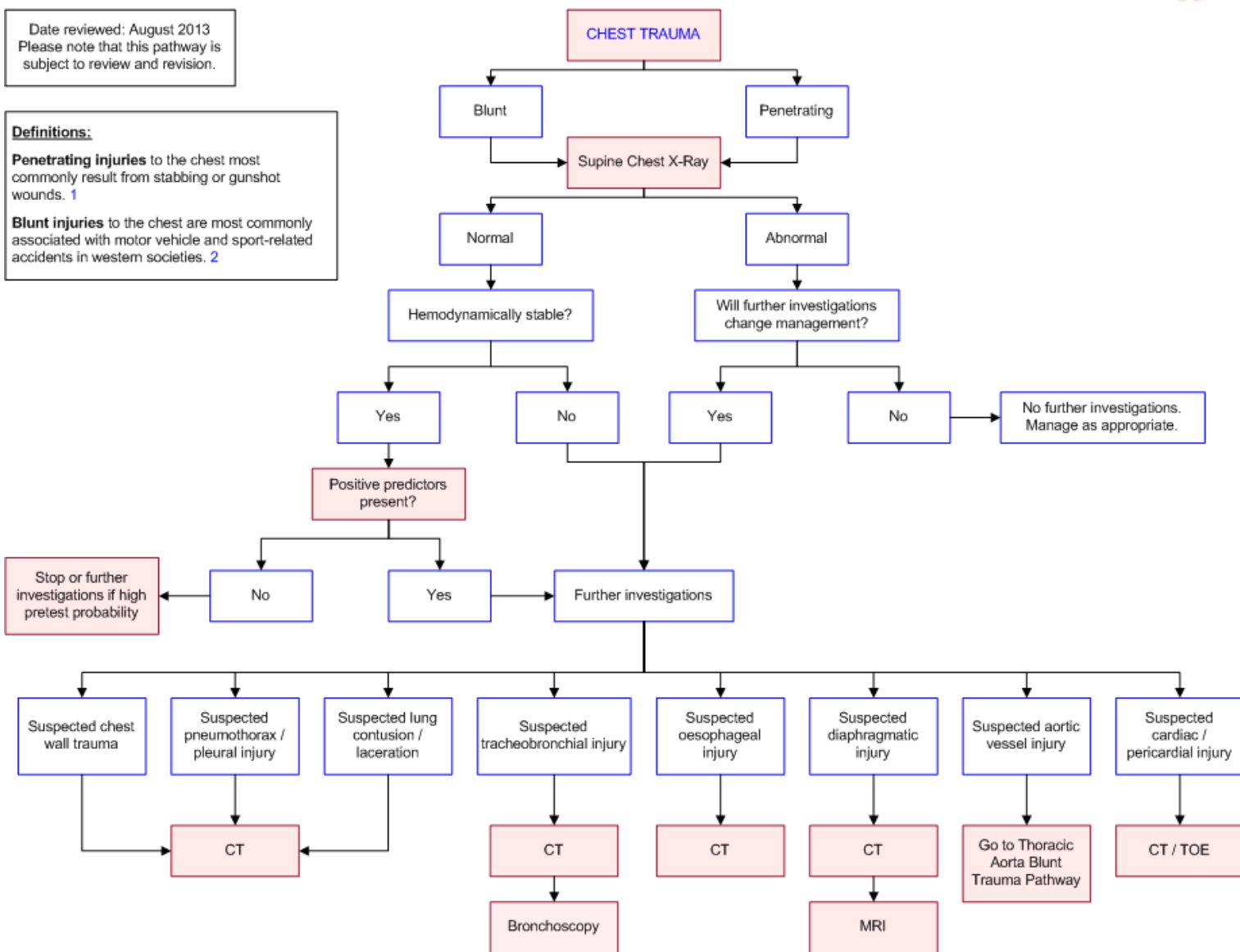
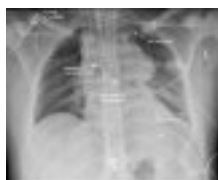

Image Gallery

Note: These images open in a new page

1



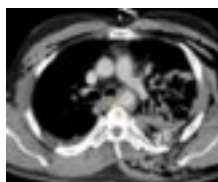Blunt Thoracic Aortic Injury

Image 1 (Chest radiography): The classical radiographic signs of a traumatic disruption of the aorta are shown including a widened mediastinum, depressed left main bronchus and left apical cap.

2a

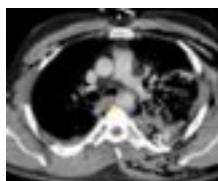
Blunt Thoracic Aortic Injury

Image 2a, 2b and 2c (CT Angiography): Evidence of an

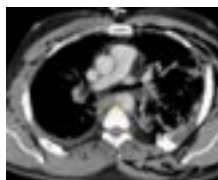

intimal flap and full-thickness rupture of the thoracic aorta at the level of the aortic isthmus (arrows). Subcutaneous emphysema is seen bilaterally with contusions to the left lung.

2b



2c



2d

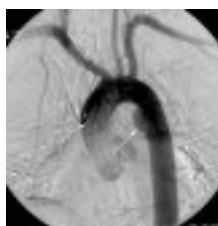
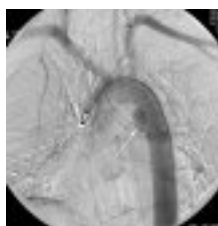
Image 2d and 2e (Aortography): Aortic rupture is confirmed by evidence of delayed contrast flow in the region of the aortic isthmus (arrow) which is best seen in image 2e, where the area of injury retains contrast and appears darker compared to the rest of the aorta.

2e



Teaching Points

- Conventional radiography (CXR) remains the primary diagnostic modality for all chest trauma patients
- Computed tomography of chest has unequalled sensitivity and specificity and often helps in rapid assessment of emergency chest trauma patients

Computed Tomography (CT). Echocardiography. Cardiac and Pericardial Injuries

- In the setting of acute chest trauma, injuries to the heart and pericardium may run the gamut from minor arrhythmia (e.g. sinus tachycardia) through to blunt cardiac avulsion [39](#)
- Cardiac contusion is one of the most common cardiac injuries in patients with blunt chest trauma, affecting 3-56% of patients. [40](#) It occurs most commonly in motor vehicle accidents, either from a direct blow to the chest (e.g. chest

hitting steering wheel) or in rapid deceleration (as the heart strikes the internal sternum). The right ventricle is more commonly affected, as it is situated more anteriorly in the chest. Symptoms may range from palpitations or precordial pain to haemodynamic instability

- Other blunt cardiac injuries may include injury to internal cardiac structures such as the ventricular septum, valves, chordae tendineae, papillary muscles. Damage to the cardiac musculature or blood vessels may result in a traumatic pericardial effusion and tamponade. This requires urgent sternotomy [41](#)
- Standard screening for cardiac trauma should include a CXR, and serial echocardiograms (ECG) and serum troponins. A large prospective study by Velmahos et al. showed that a normal ECG and normal serum troponin I levels had 100% negative predictive value for excluding blunt cardiac injury [42](#)
- Patients with positive findings on examination or screening tests should undergo morphologic assessment of the heart and pericardium. [40](#) Echocardiogram is an excellent tool in this regard. Transthoracic echocardiography (TTE) is non-invasive and can be performed at the bedside in the ED. It can detect a wide range of cardiac injuries including wall motion abnormalities, valvular lesions and pericardial effusions. In circumstances where TTE is unsuitable (e.g. patient has painful chest wall injuries) or provides poor images, transoesophageal echocardiography (TOE) should be considered [40](#)
- CT is superior to plain chest x-ray in detecting injuries from blunt chest trauma. [43](#) In comparison with echocardiogram, it is more limited in its ability to detect cardiac injury. It may not directly identify cardiac injuries such as contusion, but can demonstrate associated injuries such as haemopericardium, contrast extravasation into the mediastinum and injuries to the great vessels. Vignon et al. compared multiplane TEE to contrast enhanced helical CT in the detection of cardiovascular injuries from blunt chest trauma in 110 consecutive patients. [44](#) TEE was superior at detecting cardiac injuries, but they showed similar diagnostic accuracy for aortic injuries

Chest Wall Trauma

- Rib fractures are the most common lesion in chest wall trauma. [2](#)
- Multiple rib fractures are a marker for serious associated injuries, including abdominal injuries. [12,13](#) Many trauma surgeons believe that patients with multiple rib fractures should be referred to a trauma centre for evaluation. [12](#)
- Plain chest films, including, rib views offer limited information. [2,14](#) Screening CXRs miss rib fractures in around 50% cases, in particular, rib radiography in addition to chest radiography is deemed unnecessary for the diagnosis of fractures because CT is almost always used to evaluate potential organ injury in patients with significant chest and upper abdominal trauma. [15](#)
- Compared to plain chest radiography, a CT scan is able to differentiate chest

- wall from parenchymal or mediastinal injury. [14](#)
- Multidetector computed tomography (MDCT) is increasingly used as the method of choice for the radiologic evaluation of traumatized patients. It provides an accurate assessment of fractures and associated internal injuries. [16](#) It also provides an accurate means of assessing cartilage fractures, which are typically missed on radiography. [17,18](#)
- In a study by Traub et al., CT chest scan was shown to be significantly better at detecting fractured ribs, scapulas, sternums and vertebrae than a chest x-ray. [18](#)

Computed Tomography (CT)

- Computed tomography is the modality of choice for rapid assessment of emergency chest trauma patients though chest radiograph (CXR) remains the initial screening modality [3-7](#)
- A CT scan is significantly more likely to yield additional information than a CXR alone, especially in the presence of chest wall tenderness, reduced air-entry and abnormal respiratory effort [2](#)
- CT of chest, usually performed in conjunction with abdominal CT, in trauma patients has unequalled sensitivity and specificity. It provides great diagnostic information which can compliment the admission chest X-ray and further films. [2](#) However there are concerns regarding its overutilization and thus implications on radiation exposure, cost and time [8-10](#)

Chest Wall Trauma

- Rib fractures are the most common lesion in chest wall trauma [2](#)
- Multiple rib fractures are a marker for serious associated injuries, including abdominal injuries. [12,13](#) Many trauma surgeons believe that patients with multiple rib fractures should be referred to a trauma centre for evaluation [12](#)
- Plain radiographs including rib views offer limited information. [2,14](#) Screening chest radiographs miss rib fractures in around 50% cases. [15](#) Rib radiography in addition to chest radiography is deemed unnecessary for the diagnosis of fractures because CT is almost always used to evaluate potential organ injury in patients with significant chest and upper abdominal trauma [16](#)
- Compared to plain chest radiography, a CT scan is able to differentiate chest wall from parenchymal or mediastinal injury [14](#)
- Multidetector computed tomography (MDCT) is increasingly used as the method of choice for the radiologic evaluation of traumatized patients. It provides an accurate assessment of fractures and associated internal injuries. [16](#) It also provides an accurate means of assessing cartilage fractures, which are typically missed on radiography [17,18](#)

- In a study by Traub et al., CT chest scan was shown to be significantly better at detecting fractured ribs, scapulas, sternums and vertebrae than a chest radiograph [18](#)

Injury to Pleura

- A sufficiently high proportion of pneumothoraces are missed on chest radiography. This advocates for a low threshold to CT in the early assessment of blunt trauma patients, especially if mechanical ventilation is required for ongoing management [19](#)
- CT can detect pneumothoraces missed by ultrasonography and supine AP chest radiograph. [21](#) Several studies have documented much higher sensitivity of CT for pneumothorax when compared with supine chest radiograph [6,22-25](#)
- Chest ultrasound is also sensitive in detecting, characterising and quantifying pleural fluid collections. However small collections in the dependent part of the pleural space are difficult to access in a supine trauma patient [2](#)

Lung Injury

- The most common lung lesions resulting from blunt trauma are pulmonary contusions, pulmonary lacerations, atelectasis and aspiration of gastric content, blood or foreign bodies. [2](#) Pulmonary contusions and lacerations are also quite common after a penetrating injury [1](#)
- Pulmonary lacerations very frequently accompany pulmonary contusions and are much better seen with CT than on chest radiography [1,2,12,18,21](#)
- In general, lung lacerations are benign, but complications can occur and are best shown by CT. [6](#) Complications include infection, bronchopleural fistula, enlargement with compression of adjacent normal lung, and haemorrhage [22](#)
- Rarely, a lung segment may herniate through a flail segment. Conditions that may increase the likelihood of this occurring are positive-pressure ventilation and rupture of the internal thoracic fascia, parietal pleura, and pectoral & intercostal musculature. The diagnosis may be made with radiographs, but lung herniation is easier to detect with CT [6](#)

Computed Tomography (CT). Diaphragmatic Injury. Magnetic Resonance Imaging (MRI)

- Diaphragmatic injuries (DI) can be a diagnostic challenge. Up to 8% of patients may develop some form of DI after major blunt trauma to the lower chest or abdomen. [32](#) The majority (75%) of DI involves the left hemidiaphragm, and left sided abdominal organs (particularly stomach & spleen) are most commonly found herniating into the chest. [33](#) DI rarely occurs in isolation, and is often

- accompanied by more serious injuries to other organs. This may delay diagnosis of DI and affects up to 66% of patients at initial presentation. [34](#) Due to the progressive herniation of visceral organs and potential strangulation, delayed diagnosis is associated with 50% morbidity and mortality rate [34](#)
- Plain chest radiographs may sometimes demonstrate obvious DI (e.g. presence of herniated viscera within the chest cavity), although signs can be subtle. The accuracy for diagnosis of DI is relatively low - 27-60% of left-sided injuries and 17% of right-sided injuries. [35](#) Sensitivity is reported around 24-50%
 - Improvements in CT have improved the diagnosis of injuries in trauma patients. Standard axial CT has a reported sensitivity of 14-61% & specificity of 76-99%. [35](#) Helical CT (which allows for coronal/sagittal reconstructions) has a sensitivity of 71% and specificity of 100%. [35](#) With the latest MDCT machines (which allow for complete imaging of the chest within a single breath-hold), the sensitivity is improved to 77% [36](#)
 - In order to improve diagnosis of DI, multiple CT signs have been described. These include visceral herniation, collar sign, dependent viscera sign [34](#), and dangling diaphragm sign [36](#). In one retrospective series of 179 patients, Nchimi et al. found that the best signs of DI were diaphragmatic discontinuity, diaphragmatic thickening, segmental nonrecognition of the diaphragm, intrathoracic herniation of abdominal viscera, elevated diaphragm, and haemothorax/haemoperitoneum. The sensitivity was reported to be 100% for a combination of these signs. [37](#) A more recent and smaller series of 43 patients found that herniation of abdominal organs was highly predictive of DI [38](#)
 - On MRI sequences, the normal diaphragm presents as a continuous hypointense band. Signs of DI may include any abrupt disruption to that band and intrathoracic visceral or omental herniation. Unfortunately MRI is not well suited to the acute trauma setting and should only be considered when there is uncertainty as to the diagnosis of DI on CT [35](#)

Lung Injury

- The most common lung lesions resulting from blunt trauma are pulmonary contusions, pulmonary lacerations, atelectasis and aspiration of gastric content, blood or foreign bodies. [2](#) Pulmonary contusions and lacerations are also quite common after a penetrating injury. [1](#)
- Pulmonary lacerations very frequently accompany pulmonary contusions and are much better seen with CT than on CXR. [1,2,12,18,21](#)
- In general, lung lacerations are benign, but complications can occur and are best shown by CT. [6](#) Complications include infection, bronchopleural fistula, enlargement with compression of adjacent normal lung, and haemorrhage. [22](#)
- Rarely, a lung segment may herniate through a flail segment. The conditions increasing this likelihood are positive-pressure ventilation and rupture of the

internal thoracic fascia, parietal pleura, and pectoral & intercostal musculature. The diagnosis may be made with radiographs, but lung herniation is easier to detect with CT. [6](#)

Computed Tomography (CT)

- **Computed tomography is the modality of choice for rapid assessment of emergency chest trauma patients though chest radiography remains the initial screening modality [3-7](#)**
- **A CT scan is significantly more likely to yield additional information than a chest radiograph alone, especially in the presence of chest wall tenderness, reduced air-entry and abnormal respiratory effort [2](#)**
- **CT of chest, usually performed in conjunction with abdominal CT, in trauma patients has unequalled sensitivity and specificity. It provides great diagnostic information which can compliment the admission chest radiograph and further films. [2](#) However there are concerns regrading its overutilization and thus implications on radiation exposure, cost and time [8-10](#)**

Injury to Oesophagus

- **Injury to the oesophagus is often accompanied by injury to adjacent structures, including trachea and vascular structures**
- **Both plain films and CT are unable to demonstrate direct signs of oesophageal rupture, although they show indirect signs like mediastinal haematoma, pneumomediastinum, and pneumothorax [2](#)**
- **When injury to the oesophagus is suspected, both contrast oesophagography and endoscopy can be used [1,2,6,25,26](#)**

Injury to Pleura

- **A sufficiently high proportion of pneumothoraces are missed on CXR. This advocates for a low threshold to CT in the early assessment of blunt trauma patients, especially if mechanical ventilation is required for ongoing management. [19](#)**
- **CT can detect pneumothoraces missed by ultrasonography and supine AP CXR. [21](#) Several studies have documented much higher sensitivity of CT for pneumothorax when compared with supine CXR. [6,22-25](#)**
- **Chest ultrasound is also sensitive in detecting, characterising and quantifying pleural fluid collections. However small collections in the dependent part of the pleural space are difficult to access in a supine trauma patient. [2](#)**

Predictors of Chest Injury

- Due to concerns of overutilisation of CT in chest trauma patients, there has been an interest in creating predicting which trauma patients would benefit from chest CT. Brink et al. performed a prospective study of 1047 adult patients with blunt chest trauma in order to derive clinical predictors of chest injury [8](#)
- They found several independent predictors of the presence of any chest injuries (“positive predictors”) are [8](#)
 - Age ≥ 55 years
 - Abnormal physical examination chest
 - Abnormal physical examination of the thoracic spine
 - Altered sensorium
 - Abnormal conventional chest radiography
 - Abnormal thoracic spine radiograph
 - Abnormal radiograph of pelvis and abdominal ultrasonography
 - Base excess < -3 mmol/L
 - Haemoglobin < 6 mmol/L
- The above independent predictors significantly contributed to the presence of chest injuries on CT in their study. The authors suggest that although their absence can be used as a guide against the use of a CT chest, their presence necessitates careful clinical judgement to decide which patient really needs CT
- Further investigations for clinically stable patients having normal chest radiograph should be dependent on pre-test probability. Unfortunately, a method to assess the pre-test probability is not well defined. For example, a dangerous mechanism of injury does not correlate significantly with traumatic aortic injury but speed of collision does (if > 60 mph or > 100 kph) [8,11](#)
- These positive predictors are yet to be externally validated in other populations and settings

Mechanism of injury

- Mechanism of injury was not considered a positive predictor for the presence of a chest injury on CT in the recent study by Brink et al (2010). [8](#) So in the absence of positive CXR findings in stable patients with a low pretest probability (excluding motor vehicle accidents with speed > 60 mph), a thoracic aortic injury can be excluded and thus a CT can be avoided. [11](#) The findings from the chest radiograph incorporated in the study were left paraspinous line displacement, obscured aortic knob, and mediastinal widening. It showed a negative predictive value of 99.6% in excluding Thoracic Aortic Injury [11](#)

Computed Tomography (CT)

- **Computed tomography is the modality of choice for rapid assessment of emergency chest trauma patients though chest radiography remains the initial screening modality [3-7](#)**
- **A CT scan is significantly more likely to yield additional information than a chest radiograph alone, especially in the presence of chest wall tenderness, reduced air-entry and abnormal respiratory effort [2](#)**
- **CT of chest, usually performed in conjunction with abdominal CT, in trauma patients has unequalled sensitivity and specificity. It provides great diagnostic information which can compliment the admission chest X-ray and further films. [2](#) However there are concerns regarding its overutilization and thus implications on radiation exposure, cost and time [8-10](#)**

Injury to the Trachea and Bronchi. Bronchoscopy

- **Tracheobronchial injuries (TBI) are relatively uncommon and often go unrecognized as a result of lack of visible external signs of injury [23](#)**
- **Rapid detection depends on a high suspicion of injury. TBI should be suspected if the patient has severe dyspnoea, haemoptysis, subcutaneous emphysema, mediastinal or cervical air on radiograph, or a persistent pneumothorax or air leak following chest tube insertion [12](#)**
- **The hallmark of the intrathoracic tracheal injury is persistent, progressive, and severe pneumomediastinum, unrelieved by tube thoracostomy [6](#)**
- **Chen et al. showed that the overall sensitivity of CT for the diagnosis of tracheal rupture was 85% [24](#)**
- **Any blunt trauma patient presenting with persistent pneumothorax despite adequate chest tube insertion, or persistently enlarging pneumomediastinum/subcutaneous cervical emphysema should have a bronchoscopy irrespective of x-ray or CT findings [2](#)**
- **Bronchoscopy is the diagnostic modality of choice to confirm TBI [1,12,27,29,30](#)**

Plain Radiography

- **Conventional radiography remains the primary diagnostic modality for all chest trauma patients. It gives precise diagnosis for most life-threatening lesions involving the chest wall, pleura, lung, mediastinum and diaphragm [2,3](#)**
- **Plain radiographs should be used as the initial screening examination in the patient who has sustained chest trauma**

References

References are graded from Level I to V according to the Oxford Centre for Evidence-Based Medicine, Levels of Evidence. [Download the document](#)

- 1. Shanmuganathan K, Matsumoto J. Imaging of penetrating chest trauma. Radiol Clin North Am. 2006;44(2):225-38. (Review article)**
- 2. Wicky S, Wintermark M, Schnyder P, Capasso P, Denys A. Imaging of blunt chest trauma. Eur Radiol. 2000;10(10):1524-38. (Review article)**
- 3. Mirvis SE. Imaging of acute thoracic injury: the advent of MDCT screening. Semin Ultrasound CT MR. 2005;26(5):305-31. (Review article)**
- 4. Sroka NL, Combs J, Mood R, Henderson V. Scout anteroposterior and lateral CT scans as a screening test for thoracolumbar spine injury in blunt trauma. Am Surg. 2007;73(8):780-5. (Level III evidence)**
- 5. Magu S, Yadav A, Agarwal S. Computed tomography in blunt chest trauma. Indian J Chest Dis Allied Sci. 2009;51:75-81. (Level III evidence)**
- 6. Mirvis S. Diagnostic imaging of acute thoracic injury. Semin Ultrasound CT MR. 2004;25(2):156-79. (Review article)**
- 7. Omert L, Yeane W, Protetch J. Efficacy of thoracic computerized tomography in blunt chest trauma. Am Surg. 2001;67(7):660-4. (Level II evidence).**
- 8. Brink M, Deunk J, Dekker HM, Edwards MJR, Kool DR, van Vugt AB, et al. Criteria for the selective use of chest computed tomography in blunt trauma patients. Eur Radiol. 2010;20(4):818-28. (Level III evidence)**
- 9. Plurad D, Green D, Demetriades D, Rhee P. The increasing use of chest computed tomography for trauma: is it being overutilized? J Trauma. 2007;62:631- 5. (Level III evidence)**
- 10. Ali Salim BS, Matthew Martin, Carlos Brown, David Plurad, Demetrios Demetriades. Whole body imaging in blunt multisystem trauma patients without obvious signs of injury: results of a prospective study. Arch Surg. 2006;141:468-75. (Level III evidence)**
- 11. Ungar TC, Wolf SJ, Haukoos JS et al. Derivation of a clinical decision rule to exclude thoracic aortic imaging in patients with blunt chest trauma after motor vehicle collisions. J Trauma. 2006;61:1150-5. (Level III evidence)**
- 12. Mayberry JC. Imaging in thoracic trauma: the trauma surgeon's perspective. J Thorac Imaging. 2000;15(2):76-86. (Review article)**
- 13. Ziegler DW, Agarwal NN. The morbidity and mortality of rib fractures. J Trauma. 1994;37(6):975-9. (Level III evidence)**
- 14. Collins J. Chest wall trauma. J Thorac Imaging. 2000;15(2):112-9. (Review article)**
- 15. Livingston D, Shogan B, John P, F.Lavery R. CT diagnosis of rib fractures and the prediction of acute respiratory failure. J Trauma. 2008;64(4):905-11. (Level III evidence)**
- 16. Alkadhi H, Wildermuth S, Marincek B, Boehm T. Accuracy and time efficiency for the detection of thoracic cage fractures: volume rendering compared with transverse computed tomography images. J Comput Assist Tomogr. 2004;28(3):378-85. (Level III evidence)**

- 17. Malghem J, Vande Berg BC, Lecouvet FE, Maldague BE. Costal cartilage fractures as revealed on CT and sonography. AJR Am J Roentgenol. 2001;176(2):429-32. (Level II evidence)**
- 18. Traub M, Stevenson M, McEvoy S, Briggs G, Lo SK, Leibman S, et al. The use of chest computed tomography versus chest X-ray in patients with major blunt trauma. Injury. 2007;38(1):43-7. (Level III evidence)**
- 19. Lamb A, Qadan M, AJ.Gray. Detection of occult pneumothoraces in the significantly injured adult with blunt trauma. Eur J Emerg Med. 2007;14(2):65-7. (Level III evidence)**
- 20. Wilkerson RG, Stone MB. Sensitivity of bedside ultrasound and supine anteroposterior chest radiographs for the identification of pneumothorax after blunt trauma. Acad Emerg Med. 2010;17(1):11-7. (Level II evidence)**
- 21. Trupka A, Waydhas C, Hallfeldt KKJ, Nast-Kolb D, Pfeifer KJ, Schweiberer L. Value of thoracic computed tomography in the first assessment of severely injured patients with blunt chest trauma: results of a prospective study. J Trauma. 1997;43(3):405-11. (Level II evidence)**
- 22. Carroll K, H.Cheeseman S, P.Fink M, B.Umali C, T.Cohen I. Secondary infection of post-traumatic pulmonary cavitory lesions in adolescents and young adults: role of computed tomography and operative debridement and drainage. J Trauma. 1989;29(1):109-12. (Level IV evidence)**
- 23. KL Killeen, SE Mirvis, Shanmuganathan K. Helical CT of diaphragmatic rupture caused by blunt trauma. AJR Am J Roentgenol. 1999;173(6):1611-6. (Level III evidence)**
- 24. Chen J-D, Shanmuganathan K, Mirvis SE, Killeen KL, Dutton RP. Using CT to diagnose tracheal rupture. AJR Am J Roentgenol. 2001;176:1273-80. (Level III evidence)**
- 25. De Lutio di Castelguidone E, Pinto A, Merolas S, Stavolo C, Romano L. Spiral and multislice computed tomography in the evaluation of traumatic and spontaneous oesophageal perforation: our experience. Radiologia Medica. 2005;109(3):252-9. (Level III evidence)**
- 26. Flowers JL, Graham SM, Ugarte MA, Sartor WM, Rodriquez A, Gens DR, et al. Flexible endoscopy for the diagnosis of esophageal trauma. J Trauma. 1996;40(2):261-6. (Level III evidence)**
- 27. Lochum S, Thomas Ludig, Frederic Walter, Hugues Sebbag, Gilles Grosdidier, Blum AG. Imaging of diaphragmatic injury: a diagnostic challenge? Radiographics. 2002;22(suppl 1):103-16. (Review article)**
- 28. Shanmuganathan K , Killeen K, Mirvis S, White, Charles S. Imaging of diaphragmatic injuries. J Thorac Imaging. 2000;15:104-11. (Review Article)**
- 29. Killeen K, Shanmuganathan K , Stuart M. Imaging of traumatic diaphragmatic injuries. Semin Ultrasound CT MR. 2002;23(2):184-92. (Review article)**
- 30. Mirvis S, Shanmuganathan K. MR imaging of thoracic trauma. Magn Reson Imaging Clin N Am. 2000;8(1):91-104. (Review article)**
- 31. Mandavia D, Joseph A. Bedside echocardiography in chest trauma. Emerg Med Clin North Am. 2004;22(3):601-19. (Review article)**



- 32. Sangster G, Ventura VP, Carbo A, Gates T, Garayburu J, D'Agostino H. Diaphragmatic rupture: a frequently missed injury in blunt thoracoabdominal trauma patients. Emerg Radiol. 2007;13(5):225-30. (Review article)**
- 33. Hanna WC, Ferri LE. Acute traumatic diaphragmatic injury. Thorac Surg Clin. 2009;19(4):485-9. (Review article)**
- 34. Cantwell CP. The dependent viscera sign. Radiology. 2006;238(2):752-3. (Review article)**
- 35. Iochum S, Ludig T, Walter F, Sebbag H, Grosdidier G, Blum AG. Imaging of diaphragmatic injury: a diagnostic challenge? Radiographics. 2002;22 Spec No:S103-16; discussion S116-8. (Review article)**
- 36. Desser TS, Edwards B, Hunt S, Rosenberg J, Purtill MA, Jeffrey RB. The dangling diaphragm sign: sensitivity and comparison with existing CT signs of blunt traumatic diaphragmatic rupture. Emerg Radiol. 2010;17(1):37-44. (Level III evidence)**
- 37. Nchimi A, Szapiro D, Ghaye B, Willems V, Khamis J, Haquet L, Noukoua C, Dondelinger RF. Helical CT of blunt diaphragmatic rupture. AJR Am J Roentgenol. 2005;184(1):24-30. (Level III evidence)**
- 38. Chen HW, Wong YC, Wang LJ, Fu CJ, Fang JF, Lin BC. Computed tomography in left-sided and right-sided blunt diaphragmatic rupture: experience with 43 patients. Clin Radiol. 2010;65(3):206-12. (Level III evidence)**
- 39. Trauma.org. Organ injury scaling: heart [Document on the Internet]. Accessed: June 2011. [Access the document](#)**
- 40. Sybrandy KC, Cramer MJ, Burgersdijk C. Diagnosing cardiac contusion: old wisdom and new insights. Heart. 2003;89(5):485-9. (Review article)**
- 41. Cook CC, Gleason TG. Great vessel and cardiac trauma. Surg Clin North Am. 2009;89(4):797-820, viii. (Review article)**
- 42. Velmahos GC, Karaiskakis M, Salim A, Toutouzas KG, Murray J, Asensio J, Demetriades D. Normal electrocardiography and serum troponin I levels preclude the presence of clinically significant blunt cardiac injury. J Trauma. 2003;54(1):45-50; discussion 50-1. (Level III evidence)**
- 43. Omert L, Yeane WW, Protetch J. Efficacy of thoracic computerized tomography in blunt chest trauma. Am Surg. 2001;67(7):660-4. (Level III evidence)**
- 44. Vignon P, Boncoeur MP, François B, Rambaud G, Maubon A, Gastinne H. Comparison of multiplane transesophageal echocardiography and contrast-enhanced helical CT in the diagnosis of blunt traumatic cardiovascular injuries. Anesthesiology. 2001;94(4):615-22. (Level III evidence)**

Information for Consumers

Information from this website	Information from the Royal Australian and New Zealand
-------------------------------	-------------------------------------------------------



	College of Radiologists' website
Consent to Procedure or Treatment Radiation Risks of X-rays and Scans Computed Tomography (CT)	Computed Tomography (CT) Contrast Medium (Gadolinium versus Iodine) Gadolinium Contrast Medium
Magnetic Resonance Imaging (MRI) Plain Radiography (X-ray)	Iodine-Containing Contrast Medium Magnetic Resonance Imaging (MRI) Plain Radiography/X-rays Radiation Risk of Medical Imaging During Pregnancy Radiation Risk of Medical Imaging for Adults and Children

Copyright

© Copyright 2015, Department of Health Western Australia. All Rights Reserved. This web site and its content has been prepared by The Department of Health, Western Australia. The information contained on this web site is protected by copyright.

Legal Notice

Please remember that this leaflet is intended as general information only. It is not definitive and The Department of Health, Western Australia can not accept any legal liability arising from its use. The information is kept as up to date and accurate as possible, but please be warned that it is always subject to change

File Formats



Some documents for download on this website are in a Portable Document Format (PDF). To read these files you might need to download Adobe Acrobat Reader.



[Legal Matters](#)