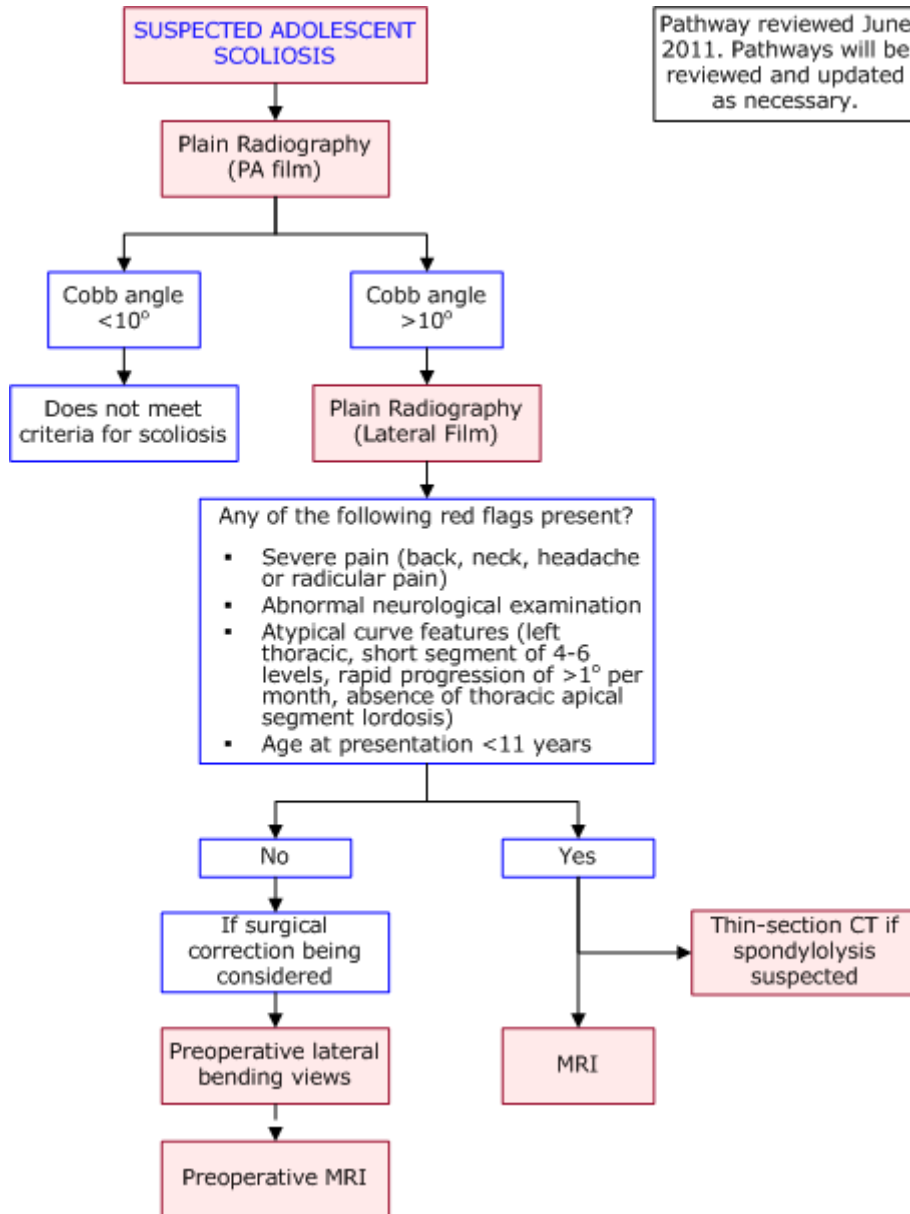




## DIAGNOSTIC IMAGING PATHWAYS

[www.imagingpathways.health.wa.gov.au](http://www.imagingpathways.health.wa.gov.au)



## INTRODUCTION

- Scoliosis is defined as  $>10^\circ$  abnormal lateral curvature of the spine in the coronal plane, often associated with axial rotation. [1,2](#)
- Scoliosis can be classified as structural or non-structural (functional). Functional scoliosis can be postural or compensatory. It is non-progressive and correctable by ipsilateral bending. [1,3,4](#)
- Structural scoliosis can be classified into 5 aetiological causes: idiopathic (80%), congenital (10%), or associated with neuromuscular, developmental and other miscellaneous diseases. [3,4](#)

- Idiopathic scoliosis is a diagnosis of exclusion and can be subdivided based on age of onset: infantile (from birth to 3 years - <1% of cases), juvenile (4 to 10 years - 12-21%) and adolescent (>10 years and before skeletal maturity). [1-3,5](#)
- Adolescent idiopathic scoliosis has a prevalence of 0.5-3% and is the most common form of the disease. Females are predominantly affected (female:male ratio 5-10:1) and are more likely to have more progressive disease and severe curves. [2,5](#)
- The Adam's forward bend test is commonly used as a screening test for scoliosis. The test is performed with the patient bending forward at the waist with arms extended and knees straight until the spine parallel with the ground. Observe for asymmetry in the contour of the back when viewed in the horizontal plane. A rib cage deformity known as a "rib hump" is indicative of a scoliosis curve >10°. [2](#)
- Adam's test was 92% sensitive and 60% specific for detecting thoracic curves >20° and 73% sensitive and 68% specific for lumbar curves >20°, when compared with Cobb's angle as the gold standard. [6](#)

## PLAIN RADIOGRAPHY

- The primary imaging modality for evaluating adolescent scoliosis is a single posteroanterior erect film of the entire spine and including the iliac crests. [1,2,7](#)
- Some authors also recommend a lateral film as part of the initial radiographic investigation. [3,4,8](#)
- The lateral view is necessary to determine the absence of apical segment lordosis of the thoracic spine (i.e. the presence of normal thoracic kyphosis or hyperkyphosis) which is considered an atypical curve pattern and found to be associated with increased incidence of neuroaxis abnormalities. [9](#)
- The scoliosis curve is described as "right" or "left" depending on their convexity and named by the location of the apex vertebrae.
- The Cobb method is used to quantify the degree of scoliosis. A line parallel to the superior end plate of the most cephalic tilted vertebra and a line parallel to the inferior end plate of the most tilted caudal vertebra are drawn. Perpendicular lines to these are drawn and the Cobb angle is measured where the lines intersect.
- Factors which reduce the reproducibility include patient position, radiographic technique and diurnal variation (5° reported in one study). [3](#)
- On a single film there can still be variability in inter-observer and intra-observer measurements. In one study the 95% confidence intervals for intraobserver variability was 4.9° and intraobserver variability was 7.2°, when the end vertebrae were not pre-selected. [10](#)
- Hence, in the monitoring of scoliosis a 10° difference of the Cobb angle between radiographs taken at different times is necessary in order to be 95% confident that a true change in scoliosis has occurred. [3](#)

## Preoperative Lateral Bending Views

- Passive lateral bending view in the frontal plane enables the surgeon to measure the degree of correction and determine the levels included in the operation. [1,3,4,8,12](#)
- A CXR is required to exclude any associated cardiopulmonary abnormalities. [3,8](#)

## Notes on ionising radiation

- Judicious use of imaging frequency and radiation reduction techniques (eg. breast shielding, contoured filter, air gap technique) are needed to minimise the radiation burden as patients with scoliosis are monitored with serial radiographs.
- The PA view is standard as it reduces the radiation dose to breast tissue despite delivering increased radiation absorption to bone marrow. Bone marrow is only one-sixth as sensitive to radiation as breast tissue. [3,4](#)
- The PA film compared to the AP view, reduces cumulative radiation dose to the thyroid gland and breast by 3 to 7 fold and would reduce the estimated risk of lifetime cancer by 3 to 4 fold. [1,5](#)
- A retrospective cohort study of 5573 female patients with scoliosis diagnosed before the age of 20 has shown that scoliosis patients are exposed to an average of 25 radiographs per patient with a mean estimated cumulative radiation dose to the breast of 10.8 cGy. The relative risk of dying from breast cancer was 1.7 (95% CI = 1.2-2.1) after an average of 40 years follow-up (77 observed breast cancer deaths vs 45 expected deaths in this population). [1,3,5](#)

## MAGNETIC RESONANCE IMAGING

- MRI is the modality of choice for assessment of the spinal canal and paraspinal soft tissues in patients with scoliosis. [4,12](#)
- Spinal cord abnormalities are seen in 2-3% of patients with presumed adolescent idiopathic scoliosis. [9,13](#)
- Abnormalities detected by MRI include Chiari malformations, hydromyelia, syringomyelia, intramedullary tumours, tethered spinal cord, diastamatomyelia and intra-spinal lipomas.
- The clinical relevance of these findings is still debated. It is known that there is increased risk of neurological complications during correction of scoliosis without prior neurosurgical intervention for conditions such as syringomyelia. [15](#)
- Commonly accepted indications for MRI include
  - Pain involving the back or neck, radicular pain or headache
  - Neurological findings
  - Atypical curve pattern: In one study, there was a 25% prevalence of neuroaxis abnormalities when both an atypical curve and neurological findings were present [9](#)
  - Age of onset <11 years: There is a higher prevalence (20%) of MRI neuroaxis abnormalities in the infantile/juvenile scoliosis age groups [3](#)
- The presence of abnormalities on MRI in those without any of the above features is variable depending on the series. Some studies report a 2-3% prevalence of which none required prior neurosurgical intervention or had postoperative neurological complications. [13,14](#) Others have reported prevalences up to 8% of which 15% required a neurosurgical procedure. [16](#) In view of this, some institutions advocate routine preoperative MRI in *all patients* with presumed adolescent idiopathic scoliosis.

## COMPUTED TOMOGRAPHY

- Thin section CT is the most accurate confirmatory test if there is concern regarding spondylolysis. Spondylolysis at L5 is common in patients with adolescent idiopathic scoliosis and important to identify since the surgeons may choose to include this area while extending posterior fusion to pelvis. [17](#)

## REFERENCES

1. Van Goethem J, Van Campenhout A, van den Hauwe L, Parizel PM. **Scoliosis**. *Neuroimaging Clin N Am*. 2007 Feb;17(1):105-15. (Review article)
2. Reamy BV, Slakey JB. **Adolescent idiopathic scoliosis: review and current concepts**. *American family physician*. 2001 Jul 1;64(1):111-6. (Review article)
3. Cassar-Pullicino VN, Eisenstein SM. **Imaging in scoliosis: what, why and how?** *Clin Radiol*. 2002 Jul;57(7):543-62. (Review article)
4. Oestreich AE, Young LW, Young Poussaint T. **Scoliosis circa 2000: radiologic imaging perspective. I. Diagnosis and pretreatment evaluation**. *Skeletal radiology*. 1998 Nov;27(11):591-605. (Review article)
5. Jaramillo D, Poussaint TY, Grottkau BE. **Scoliosis: evidence-based diagnostic evaluation**. *Neuroimaging Clin N Am*. 2003 May;13(2):335-41, xii. (Review article)
6. Cote P, Kreitz BG, Cassidy JD, Dzus AK, Martel J. **A study of the diagnostic accuracy and reliability of the Scoliometer and Adam's forward bend test**. *Spine*. 1998 Apr 1;23(7):796-802. (Level III evidence)
7. Greiner KA. **Adolescent idiopathic scoliosis: radiologic decision-making**. *American family physician*. 2002 May 1;65(9):1817-22. (Review article)
8. Thomsen M, Abel R. **Imaging in scoliosis from the orthopaedic surgeon's point of view**. *European journal of radiology*. 2006 Apr;58(1):41-7. (Review article)
9. Davids JR, Chamberlin E, Blackhurst DW. **Indications for magnetic resonance imaging in presumed adolescent idiopathic scoliosis**. *The Journal of bone and joint surgery*. 2004 Oct;86-A(10):2187-95. (Level III evidence)
10. Morrissy RT, Goldsmith GS, Hall EC, Kehl D, Cowie GH. **Measurement of the Cobb angle on radiographs of patients who have scoliosis. Evaluation of intrinsic error**. *The Journal of bone and joint surgery*. 1990 Mar;72(3):320-7. (Level IV evidence)
11. Morcuende JA, Dolan LA, Vazquez JD, Jirasirakul A, Weinstein SL. **A prognostic model for the presence of neurogenic lesions in atypical idiopathic scoliosis**. *Spine*. 2004 Jan 1;29(1):51-8. (Level III evidence)
12. Wright N. **Imaging in scoliosis**. *Archives of disease in childhood*. 2000 Jan;82(1):38-40. (Review article)
13. Inoue M, Minami S, Nakata Y, Otsuka Y, Takaso M, Kitahara H, et al. **Preoperative MRI analysis of patients with idiopathic scoliosis: a prospective study**. *Spine*. 2005 Jan 1;30(1):108-14. (Level III evidence)
14. Do T, Fras C, Burke S, Widmann RF, Rawlins B, Boachie-Adjei O. **Clinical value of routine preoperative magnetic resonance imaging in adolescent idiopathic scoliosis. A prospective study of three hundred and twenty-seven patients**. *The Journal of bone and joint surgery*. 2001 Apr;83-A(4):577-9. (Level III evidence)
15. Noordeen, M.H., B.A. Taylor and M.A. Edgar. **Syringomyelia. A potential risk factor in scoliosis surgery**. *Spine*, 1994. 19(12): p. 1406-9. (Level IV evidence)
16. Ozturk, C. et al. **The role of routine magnetic resonance imaging in the preoperative evaluation of adolescent idiopathic scoliosis**. *Int Orthop*, 2009. (Level II evidence)
17. Malfair D, Flemming AK, Dvorak MF, Munk PL, Vertinsky AT, Heran MK, Graeb DA. **Radiographic evaluation of scoliosis: review**. *AJR Am J Roentgenol*. 2010 Mar; 194(3 Suppl):S8-22.(review article)

#### **Website**

For more information go to [www.imagingpathways.health.wa.gov.au](http://www.imagingpathways.health.wa.gov.au)

#### **Copyright**

© Copyright 2009, Department of Health Western Australia. All Rights Reserved.

This web site and its content has been prepared by The Department of Health, Western Australia. The information contained on this web site is protected by copyright.

#### **Legal Notice**

Please remember that this leaflet is intended as general information only. It is not definitive and The Department of Health, Western Australia can not accept any legal liability arising from its use. The information is kept as up to date and accurate as possible, but please be warned that it is always subject to change.

