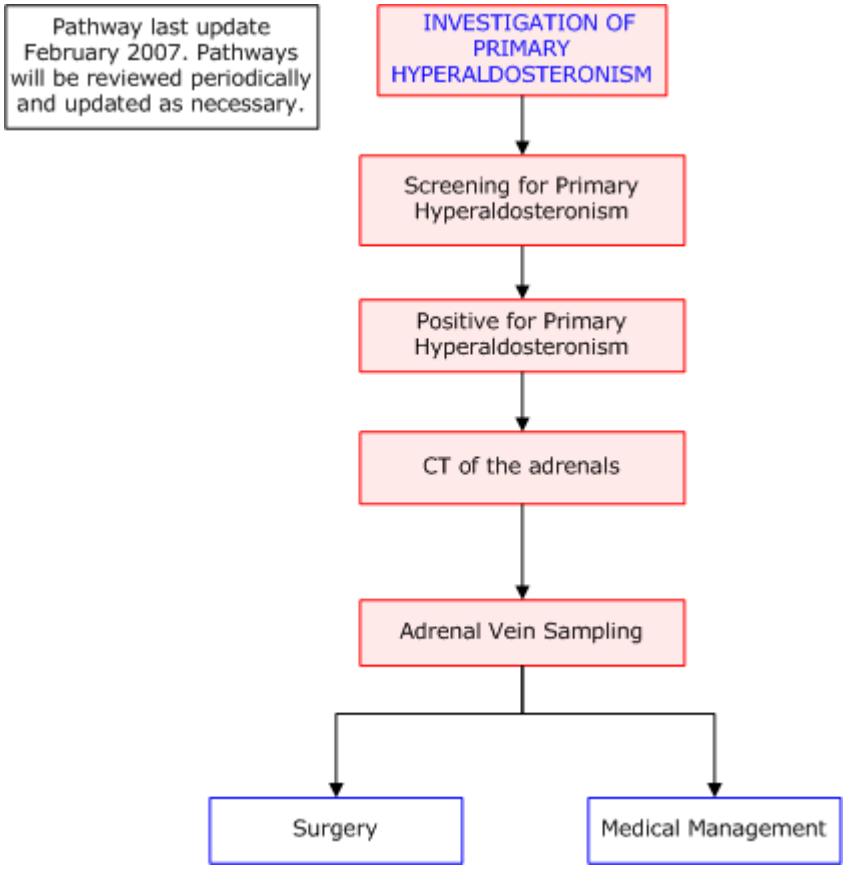

PRIMARY HYPERALDOSTERONISM

- The incidence of hyperaldosteronism as a cause for hypertension is believed to be more common than previously thought. 2-10% of patients with hypertension have hyperaldosteronism. 1
- Imaging is used for localisation of a biochemically proven abnormality. 1,2
- The most important distinction to be made is between the two most common causes of primary hyperaldosteronism: 1,2
    1. Aldosterone producing adenoma (APA) - One third of cases of Primary Hyperaldosteronism
    2. Bilateral adrenal hyperplasia or Idiopathic hyperaldosteronism (IHA) - Two thirds of cases of Primary Hyperaldosteronism
- Aldosterone producing adenoma is treated surgically and idiopathic hyperaldosteronism/bilateral adrenal hyperplasia is treated medically. 1,2

BIOCHEMICAL EVALUATION

- Plasma aldosterone concentration to plasma renin activity ratio (PAC/PRA) is regarded as the screening test of choice for primary hyperaldosteronism (PA). 1,3
- Biochemical diagnosis of primary hyperaldosteronism must be established prior to performing imaging studies to avoid unnecessary surgery because 3% to 7% of patients over the age of 50 have nonfunctioning adrenal nodules ("incidentalomas"). 4

Copyright © 2007 Department of Health Western Australia

CONFIRMATORY TESTING

- A number of tests are available to confirm the diagnosis of Primary Hyperaldosteronism. These include; 13
  - 1. Fludrocortisone Suppression Test
  - 2. Normal Saline Infusion
  - 3. Oral Sodium Loading
- In clinical practice however, a properly performed plasma aldosterone:renin concentration (PAC/PRA) particularly in the absence of medications likely to cause false results (such as B-Blockers and diuretics) is normally sufficient to make the diagnosis.

COMPUTED TOMOGRAPHY

- Initial imaging modality of choice for localisation of biochemically proven primary hyperaldosteronism. 1,2
- Computed Tomography has been shown to have a sensitivity of 50-60% in the detection of adenoma. 6-8
- Magnetic Resonance Imaging has been shown to have a comparable sensitivity of 70% in detecting adenoma, with a specificity of 100% 14
- Advantages: non-invasive and is useful in mapping the position of veins prior to adrenal vein sampling

ADRENAL VEIN SAMPLING (AVS)

- Most reliable method to localise the lesion resulting in Primary Hyperaldosteronism, and will dictate further management 6,8-10,12
- Concordance between computed tomography and adrenal vein sampling for the assessment of Primary Hyperaldosteronism is poor 15
- Adrenal Vein Sampling is a sensitive test to differentiate aldosterone-producing adenoma (APA) from bilateral hyperplasia. 8,9,12
- The aldosterone to cortisol ratio in both adrenal veins is compared. If one side has a concentration more than 2 times the other side, then APA is diagnosed; bilateral adrenal hyperplasia is the diagnosis by default. 12
- When successful, AVS unequivocally establishes the presence or absence of unilateral aldosterone production, thus clarifying the choice of therapy - medical or surgical. 1
- Disadvantages: invasive, highly operator-dependent, not widely available and carries a finite risk of venous thrombosis, adrenal haemorrhage, and adrenal insufficiency.

Copyright © 2007 Department of Health Western Australia

REFERENCES

1. Thakkar RB, Oparil S. **Primary aldosteronism: a practical approach to diagnosis and treatment**. J Clin Hypertension 2001;3(3):189-95. (Review article)
2. Ganguly A. **Primary aldosteronism**. NEJM 1998; 339(25):1828-34. (Review article)
3. Soule S, Davidson JS, Rayner BL. **The evaluation of primary hyperaldosteronism**. SAMJ 2000;90(4):387-94. (Level II/III evidence)
4. Bornstein SR, Stratakis CA, Chrousos GP. **Adrenocortical tumors: recent advances in basic concepts and clinical management**. Ann Intern Med 1999;130:759-71.
5. Radin DR, Manoogian C, Nadler JL. **Diagnosis of primary hyperaldosteronism: importance of correlating CT findings with endocrinologic studies**. AJR 1992;158:553-7. (Level III evidence)
6. Doppman JL, Gill JR Jr, Miller DL, et al. **Distinction between hyperaldosteronism due to bilateral hyperplasia and unilateral aldosteronoma**: reliability of CT. Radiology 1992;184:677-82. (Level II evidence). Click here to view reference
7. Dunnick NR, Leight GS, Robidoux MA, et al. **CT in the diagnosis of primary aldosteronism: sensitivity in 29 patients**. AJR 1993;160:321-4. (Level III evidence)
8. Harper R, Ferrett CG, McKnight JA, et al. **Accuracy of CT and adrenal vein sampling in the pre-operative sampling localization of aldosterone-secreting adrenal adenomas**. Q J Med 1999;92:643-50. (Level III evidence)
9. Magill SB, Raff H, Shaker JL, et al. **Comparison of adrenal vein sampling and computed tomography in the differentiation of primary aldosteronism**. J Clin Endocrinol & Metabolism 2001;86:1066-71. (Level III evidence)
10. Ikeda DM, Francis IR, Glazer Gm, et al. **The detection of adrenal tumors and hyperplasia in patients with primary aldosteronism: comparison of scintigraphy, CT and MR imaging**. AJR 1989;153:301-6. (Level III evidence)
11. Nocaudie-Calzada M, Huglo D, Lambert M, et al. **Efficacy of iodine 131 6b-methyl-iodo-19-norcholesterol scintigraphy and computed tomography in patients with primary hypoaldosteronism.** Eur J Nucl Med 1999;26:1326-32 (Level III evidence)
12. Mayo-Smith WW, Boland GW, Noto RB, Lee MJ. **State of the Art Adrenal Imaging**. Radiographics 2001;21:995-1012 (Review article)
13. Schirpenbach C, Reincke M **Screening for primary hyperaldosteronism** Best Prac & Res Cli Endo & Metabolism 2006; 20(3):369-384 (Review article)
14. Sohaib S, Peppercorn P, Allan C **Primary hyperaldosteronism (Conn Syndrome): MR Imaging Findings** Radiology 2000; 214:527-531 (Level IV Evidence)
15. Nwariaku F, Miller B, Auchus R et al. **Primary Hyperaldosteronism** Arch Surg 2006; 141:497-503 (Level IV Evidence)Thakkar

Copyright © 2007 Department of Health Western Australia

Website

For more information go to www.imagingpathways.health.wa.gov.au

Copyright

© Copyright 2007, Department of Health Western Australia. All Rights Reserved.

This web site and its content has been prepared by The Department of Health, Western Australia. The information contained on this web site is protected by copyright.

Legal Notice

Please remember that this leaflet is intended as general information only. It is not definitive and The Department of Health, Western Australia can not accept any legal liability arising from its use. The information is kept as up to date and accurate as possible, but please be warned that it is always subject to change.

Copyright © 2007 Department of Health Western Australia