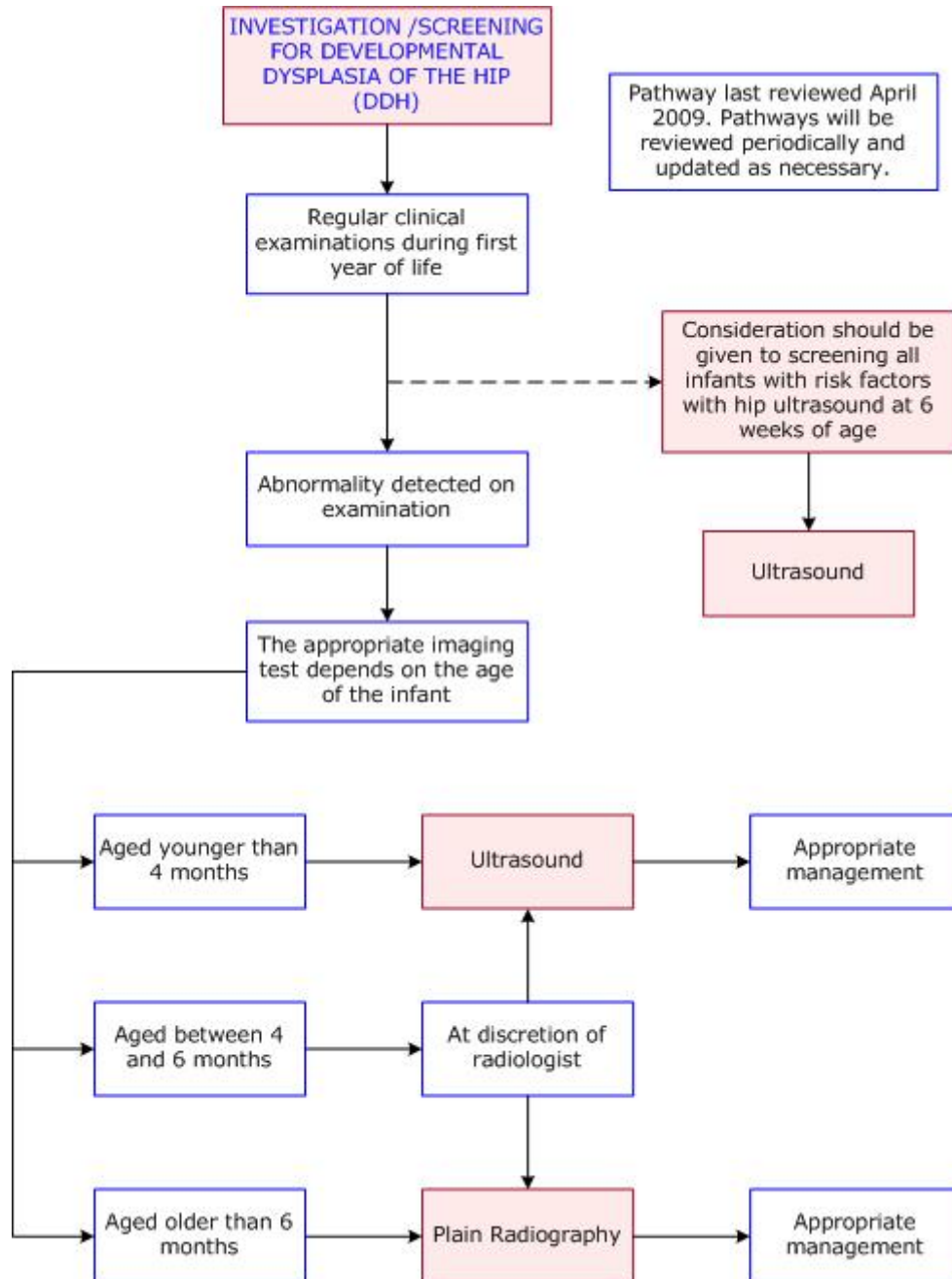




DIAGNOSTIC IMAGING PATHWAYS

www.imagingpathways.health.wa.gov.au



ULTRASOUND

- Uses and Features:
 - Effective non-invasive way to image the cartilaginous hip joint that involves no exposure to radiation. [3](#)
 - Indications for its use vary but in general it is used in children under 4-6 months of age who have signs of hip instability on examination.

- If clinical examination is normal and hip ultrasound is performed as a screening test due to the presence of risk factors it is best delayed until at least 3 weeks post term because of physiological immaturity evident on early US which may lead to false positive results.
- Whilst it is ideal to delay ultrasound until at least 3 weeks post term, if the hip is clinically dislocates or is frankly unstable then earlier orthopaedic referral and hip ultrasound should be sought.
- Consists of an anatomical and dynamic assessment of the hip joint. [1-3](#)
- Graf's standardised morphology criteria are commonly used. [2](#)
- Different variations of the anatomical and dynamic methods are used in clinical practice. [4,5](#)
- The screening of children for developmental dysplasia of the hip is a controversial topic. Clinical methods of screening when performed by experienced clinicians have a reasonably high sensitivity and specificity for detecting DDH. [6-9](#)
- Ultrasonography is used as a screening tool in some centres and it has reduced the number of infants who require surgical treatment at the expense of more infants being treated with abduction splinting. [10,11](#)

PLAIN RADIOGRAPHY

- Plain radiography is less reliable in the first few months of life when the femoral head is composed mainly of cartilage.
- It becomes a more useful method of investigating for DDH in children aged between 4 and 6 months.
- The relationships of the femoral head and proximal femoral metaphysis to the acetabulum are an important part of evaluating for DDH.
- The use of the acetabular index and other objective means are used to evaluate for DDH, although the sensitivity and specificity of some of these are uncertain. However, these measurements are only one part of the radiographical assessment used to gauge hip dysplasia. [12,13](#)

REFERENCES

1. Graf R. The diagnosis of congenital hip-joint dislocation by the ultrasonic compound treatment. Arch Orthop Trauma Surg 1980;97:117-33. (Review article)
2. Graf R. Fundamentals of sonographic diagnosis of infant hip dysplasia. J Pediatr Orthop 1984;4:735-40. (Level III evidence)
3. Clarke NMP, Harcke HT, McHugh P, et al. Real-time ultrasound in the diagnosis of congenital dislocation and dysplasia of the hip. J Bone Joint Surg 1985;67:406-12. (Level III evidence)

4. Terjeson T, Bredland T, Berg V. **Ultrasound for hip assessment in the newborn.** J Bone Joint Surg 1998;71:767-73. (Level III evidence)
5. Andersson JE. **Neonatal hip instability: normal values for physiological movement of the femoral head determined by an anterior dynamic ultrasound method.** J Pediatr Orthop 1995;15:736-40. (Level III evidence)
6. Düppe H, Danielsson LG. **Screening of neonatal instability and of developmental dislocation of the hip.** A survey of 132,601 living newborn infants between 1956-1999. J Bone Joint Surg 2002;84:878-85. (Level III evidence)
7. Krikler SJ, Dwyer NS. **Comparison of results of two approaches to hip screening in infants.** J Bone Joint Surg 1992;74:701-3. (Level III evidence)
8. Macnicol MF. **Results of a 25 year screening programme for neonatal instability.** J Bone Joint Surg 1990;72:1057-60. (Level III evidence)
9. Bialik V, Fishman J, Katzir J, Zeltzer M. **Clinical assessment of hip instability in the newborn by an orthopaedic surgeon and a paediatrician.** J Pediatr Orthop 1986;6:703-6. (Level IV evidence)
10. Patel H. **Preventive health care, 2001 update: screening and management of developmental dysplasia of the hip in newborns.** CMAJ 2001;164:1669-77. (Evidence based recommendations)
11. Rosendahl K, Markestad T, Lie RT. **Ultrasound screening for developmental dysplasia of the hip in the neonate: the effect on treatment rate and prevalence of late cases.** Pediatrics 1994;94:47-52. (Level II evidence). [Click here to view reference](#)
12. Kay RM, Watts HG, Dorey FJ. **Variability in the assessment of acetabular index.** J Pediatr Orthop 1997;17:170-3. (Level III evidence)
13. Spatz DK, Reiger M, Klaumann M, et al. **Measurement of acetabular index intraobserver and interobserver variation.** J Pediatr Orthop 1997;17:174-5. (Level III evidence)

Website

For more information go to www.imagingpathways.health.wa.gov.au

Copyright

© Copyright 2009, Department of Health Western Australia. All Rights Reserved.

This web site and its content has been prepared by The Department of Health, Western Australia. The information contained on this web site is protected by copyright.

Legal Notice

Please remember that this leaflet is intended as general information only. It is not definitive and The Department of Health, Western Australia can not accept any legal liability arising from its use. The information is kept as up to date and accurate as possible, but please be warned that it is always subject to change.

