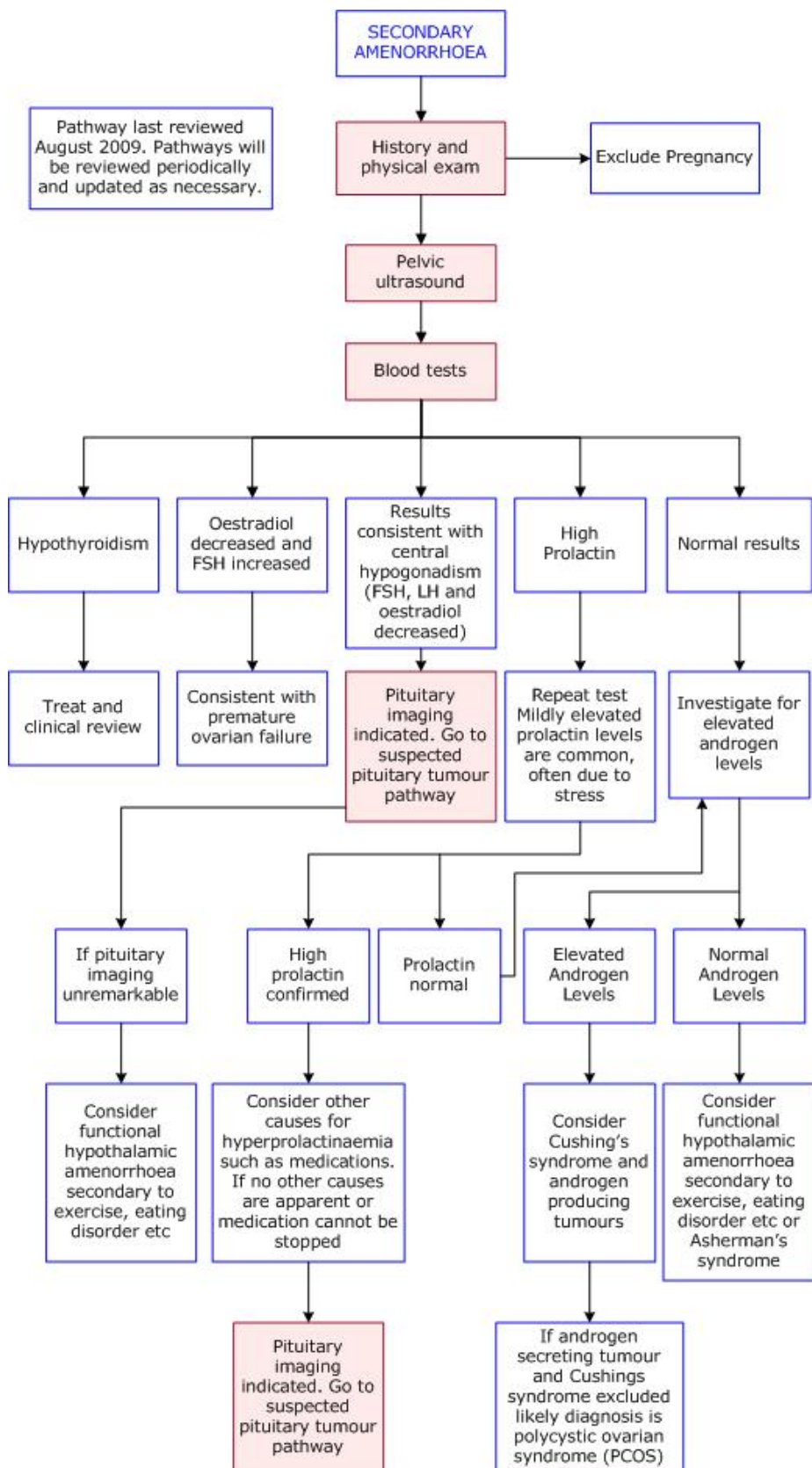




DIAGNOSTIC IMAGING PATHWAYS

www.imagingpathways.health.wa.gov.au



SECONDARY AMENORRHEA

- Important features of the history include possible pregnancy, previous instrumentation (which suggests intrauterine adhesions), medications, diet, weight loss, stress and exercise.
- Blood tests should include TFTs, oestrogen, FSH and prolactin levels.

Pelvic Ultrasound

- Safe and non-invasive method to assess for uterine and ovarian pathology which may account for up to 20% of cases of secondary amenorrhoea.
- Most common uterine cause is intrauterine adhesions (Asherman syndrome) and should be considered particularly in women with a history of instrumentation.
- Assessment of the ovaries may reveal small ovaries (ovarian failure) or polycystic ovaries (polycystic ovarian syndrome).

Website

For more information go to www.imagingpathways.health.wa.gov.au

Copyright

© Copyright 2009, Department of Health Western Australia. All Rights Reserved.

This web site and its content has been prepared by The Department of Health, Western Australia. The information contained on this web site is protected by copyright.

Legal Notice

Please remember that this leaflet is intended as general information only. It is not definitive and The Department of Health, Western Australia can not accept any legal liability arising from its use. The information is kept as up to date and accurate as possible, but please be warned that it is always subject to change.

